

# Osteoma in *Agapornis roseicollis*

## *Osteoma em Agapornis roseicollis*

Didier Quevedo Cagnini<sup>1\*</sup> ; Weida Katrinny do Carmo Moraes<sup>2</sup> ; Mayara Colmanetti Dias<sup>2</sup> ;  
Leuton Scharles Bonfim<sup>3</sup> ; Francielle Martins França<sup>3</sup> ; Douglas Regalin<sup>3</sup> 

**ABSTRACT:** Neoplasias are important causes of illness and death in domestic animals. However, in birds, they are less frequent compared with other species such as dogs and cats. Moreover, benign tumors of bone are even less frequent in captive birds being considered sporadic, which make it a poorly understood entity due to the lack of clinical and histopathological data. Thus, we present a case of an osteoma in a Peach-faced lovebird (*Agapornis roseicollis*) approaching clinical and morphological aspects. A two-years-old lovebird was referred to the veterinary hospital with a 4-month evolution round to oval tumoral mass on the wing. The nodule was firm, painful when manipulated. Radiographic examination revealed a radiopaque mass in the radius and ulna bones. The animal has died during the surgical procedures. The affected wing was submitted to pathology service and histopathology revealed an osteoma.

**KEYWORDS:** pet birds, avian medicine, avian neoplasia, avian pathology, avian surgery.

**RESUMO:** As neoplasias são importantes causas de doença e morte em animais domésticos. No entanto, em aves, são menos frequentes em comparação com outras espécies, como cães e gatos. Além disso, tumores ósseos benignos são ainda menos frequentes em aves de cativeiro sendo considerados esporádicos, o que o torna uma entidade pouco compreendida devido à falta de dados clínicos e histopatológicos. Assim, apresentamos um caso de osteoma em Periquito cara-de-pêssego (*Agapornis roseicollis*) abordando aspectos clínicos e morfológicos. Um periquito de dois anos foi encaminhado ao hospital veterinário com uma massa tumoral ovalada na asa com evolução de 4 meses. O nódulo era firme, doloroso quando manipulado. O exame radiográfico revelou uma massa radiopaca nos ossos rádio e ulna. O animal morreu durante os procedimentos cirúrgicos. A asa afetada foi submetida ao serviço de patologia e a histopatologia revelou um osteoma.

**PALAVRAS-CHAVE:** aves domésticas, medicina aviária, neoplasia aviária, patologia aviária, cirurgia aviária.

## INTRODUCTION

Neoplastic diseases are among the most important causes of morbidity and mortality in domestic animals. The real incidence of neoplasia in captive birds is challenging because it mainly relies on reports and case series, which could create a bias. However, the prevalence has been estimated at 1.89% (EFFRON *et al.*, 1977), 3.8% (REECE, 1992), and 5.8% (GARNER *et al.*, 2005).

Benign tumors of bones are uncommon in animals (SCHMIDT; REAVILL; PHALEN, 2015) and it represents a group of poorly understood neoplasia that comprises two different entities, osteoma and ossifying fibroma, and the fibrous dysplasia, the latter not being a neoplastic change (THOMPSON; DITTMER, 2017). Avian neoplasia encountered in practice

includes cancer of the skin, oral cavity, sinuses, liver, kidney, reproductive organs, bones, brain, vascular structures, and connective tissue (LIGHTFOOT, 2005).

Osteomas are seen sporadically in pet birds (LIGHTFOOT, 2005; SCHMIDT; REAVILL; PHALEN, 2015) and infrequently compared to osteosarcomas (LATIMER, 1994). In birds, this benign bone neoplasia may originate from the cranium (HIDALGO; PAULSEN, 1998; REECE, 1992, 1996), scapula, tarsometatarsus (REECE, 1992), plantar footpad (REECE, 1992), chest (COWAN *et al.*, 2011), wing (JAVDANI *et al.*, 2017), femorotibiotarsal articulation (FROST, 1961), radius (HAHN, *et al.*, 1998), nasal cavity (CARDOSO *et al.*, 2013). A retrospective study including a total of 44 ornamental and pet birds with neoplasms revealed only one case of osteoma in

<sup>1</sup>Universidade Federal de Jataí, Institute of Biological Sciences (CIBIO)

<sup>2</sup>Universidade Federal de Jataí, Graduation Student

<sup>3</sup>Universidade Federal de Jataí, Veterinary Hospital

\*Didier Quevedo Cagnini (didiercagnini@ufj.edu.br);

Received: 05/10/2022. Accepted: 06/21/2022

a 2-year-old Canary, affecting the musculoskeletal system, but no further information about the location was available (SÁNCHEZ-GODOY *et al.*, 2020). Recently there was a case of bilateral osteoma cutis in a Peach-Faced Lovebird secondary to trauma (PINZÓN-OSORIO *et al.*, 2020).

For lovebirds (*Agapornis spp.*) the most reported neoplasia was soft tissue sarcoma, fibrosarcoma, and lymphoma (GARNER *et al.*, 2005), with only one report for osteoma since our concern (HIDALGO; PAULSEN, 1998). Considering it, this report is particularly important for aggregate clinical and morphological aspects of and osteoma in a Peach-faced lovebird (*Agapornis roseicollis*).

### CASE DESCRIPTION

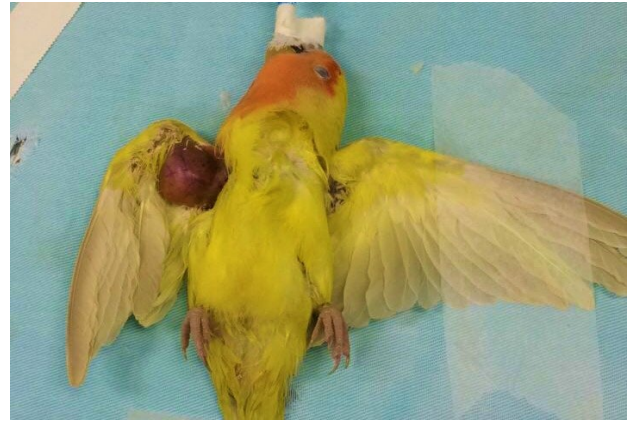A 2-years-old female Peach-faced lovebird (*Agapornis roseicollis*) was referred to the veterinary hospital, Federal University of Jataí, Brazil, with a history of a 4-month evolution round tumoral mass in the right-wing, apparently affecting the ulna and radius bones.

On physical examination, the bird was weighing 50 grams, and a subcutaneous, well-circumscribed, firm tumor, covered by featherless skin and presenting regional muscle atrophy (Fig. 1). There was no history of previous trauma or infectious disease in the region and the mass was painful during manipulation. The animal ate and drink normally most of the time, presenting decreased appetite in the last days. The animal was raised in a private cage, daily cleaned, with food and drink ad libitum.

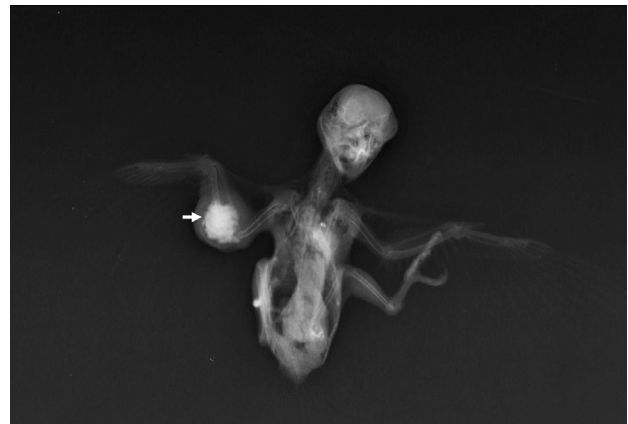On ventral-dorsal radiographic evaluation, the animal presented a heterogeneous radiopaque mass affecting the ulna, and apparently radius (Fig. 2). The animal was submitted to surgical intervention to remove the entire right-wing that was further submitted to histopathological examination. For anesthesia, it was administered Ketamine 50mg/Kg (Agener 10%, União Química, Sao Paulo, Brazil) and midazolam 1mg/Kg IM (Dormire, 0,5%, cloridrato de midazolam, Cristalia, Sao Paulo, Brazil), and then the bird was intubated with a 24G catheter. 100% oxygen was delivered in a patient-adapted non-rebreathing system, and anesthesia was maintained with 1,5V% isoflurane. The animal died during the surgical procedure after blood loss.

Grossly, the tumoral mass measured 22x20x20mm, with very hard consistency, not allowing initial cut surface evaluation (Fig. 3). However, it was possible verify that only ulna was affected by the mass. After properly fixed in a 10% buffered formalin solution for one week, the mass was placed in a 10% EDTA solution for slow decalcification, for better preservation of morphological and tinctorial characteristics. The solution was replaced every four days, during a total of 32 days. On the cut surface, the tumoral mass was whitish, and firm, showing a bone structure. Three millimeters thick sections were submitted to dehydration, diaphanization, and then embedded in paraffin wax. Five micrometers thickness sections were accessed in mechanical rotatory microtome (RM2235 Leyca Biosystems) attached to glass slides and stained with Hematoxylin and Eosin.

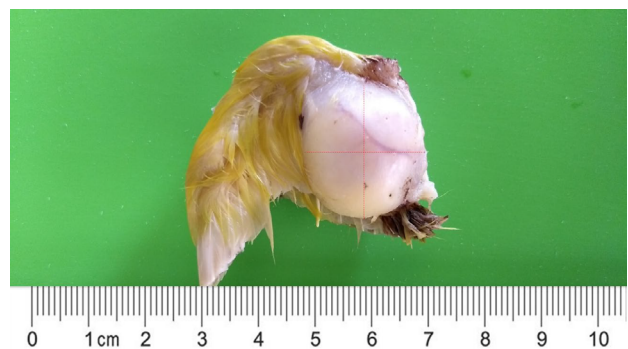Histopathology revealed a densely trabeculated bone formation surrounded by connective tissue (Fig. 4). Adjacent areas of loosely arranged stellated shaped cells were present (Fig. 5). At the periphery, the mass presented a variable thick periosteum layer. The trabecular formations were closely packed and covered by well-differentiated osteoblast.



**Figure 1.** Bird, *Agapornis roseicollis*, Osteoma. Gross morphology of subcutaneous, featherless skin-covered tumor in right radius and ulna region.

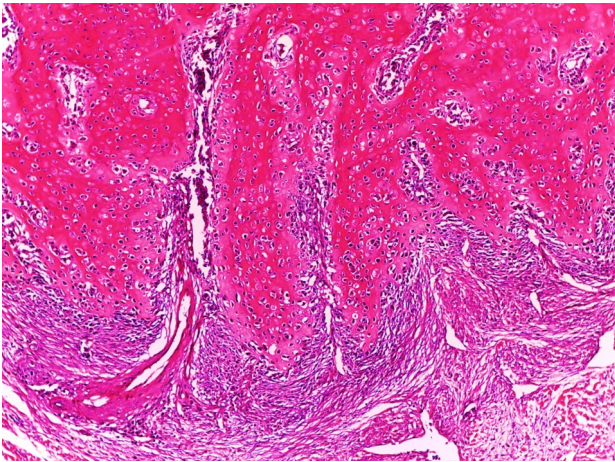


**Figure 2.** Bird, *Agapornis roseicollis*, Osteoma. Ventral-dorsal radiographic evaluation shows heterogeneous radiopaque mass affecting the ulna (arrow).

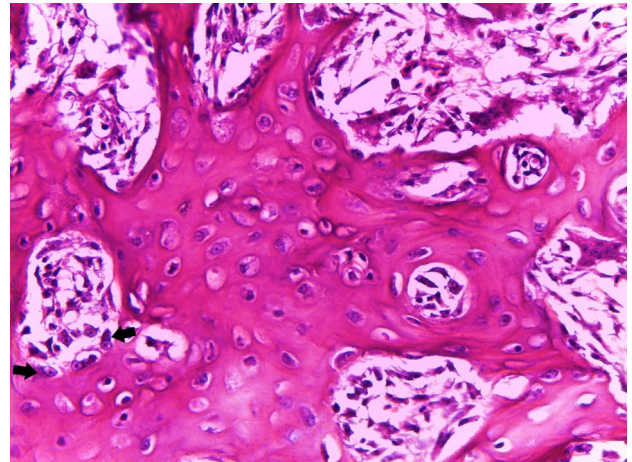


**Figure 3.** Bird, *Agapornis roseicollis*, Osteoma. Note the whitish subcutaneous mass covered by thin skin in the right radius and ulna region.

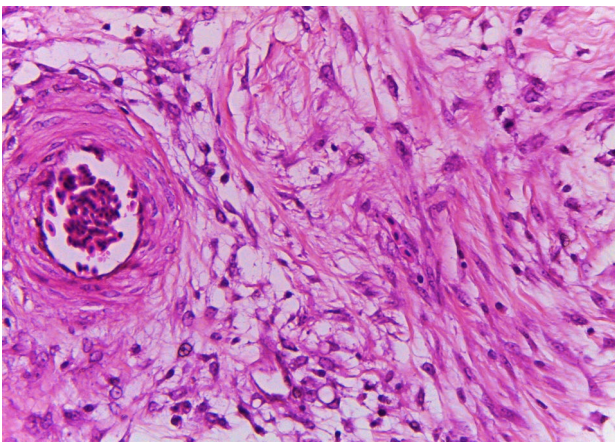




**Figure 4.** Bird, *Agapornis roseicollis*, Osteoma. Mature trabeculated bone formation surrounded by connective tissue (Hematoxylin and Eosin, 40X).



**Figure 6.** Bird, *Agapornis roseicollis*, Osteoma. Note the presence of capillaries, mesenchymal cells, and osteoblast (arrow) in the center of trabeculae (Hematoxylin and Eosin, 400X).



**Figure 5.** Bird, *Agapornis roseicollis*, Osteoma. Loosely arranged stellated cells with acidophilic extracellular matrix production (Hematoxylin and Eosin, 400X).

Moreover, mesenchymal tissue with proliferating osteoblasts and capillaries (Fig. 6) and osteoclasts were found in the center of the trabeculae. Pre-existent bone areas were normal which contributes to the final diagnosis of Skeletal osteoma.

## DISCUSSION

Clinical and morphological aspects of benign bone tumors are poorly described in the veterinary literature and could lead to misdiagnosis. Osteomas generally affect bones of the cranium, as well as fibrous osteoma (CRAIG; DITTMER; THOMPSON, 2016; HIDALGO; PAULSEN, 1998; THOMPSON; DITTMER, 2017), different from the present case, were tibial and radius bones were involved. Furthermore, osteomas commonly arise from a sessile or pedunculated base on the periosteum (CRAIG; DITTMER; THOMPSON, 2016), however, it has completely substituted the normal bone parenchyma in the present case. Osteomas occasionally arise

from the bones of the pelvis, or tubular bones of the limbs, and must be differentiated from osteochondromas (CRAIG; DITTMER; THOMPSON, 2016).

The etiology of osteomas is often multifactorial. In humans, they could be genetic or congenital (Gardner syndrome) or related to endocrine disorders, chronic inflammatory processes, or traumas (HERFORD; STOFFELLA; TANDON, 2013). This issue remains controversial, whereas some classified as a true neoplasm, others described it as a possible reaction to trauma (HERFORD; STOFFELLA; TANDON, 2013). In birds, etiology was not determinate generally by the lack of information as age, breed, sex, or other possible etiologic factors, such as repeated trauma (HAHN, *et al.*, 1998). In the present case, the 2-years-old female Peach-faced lovebird has not presented trauma or infection detected by the owner. Maybe it could be a spontaneous case of osteoma, or a possible injury may not have been noticed by the owner. Viral etiology has been described in humans and laboratory animals (LABAT, 1996) but was not investigated in the present report.

Osteomas should be differentiated clinically, radiographically, or histopathologically from disuse demineralization, devitalized bone or sequestration due to surgical intervention, or traumatic, infectious, or neoplastic processes (HEATLEY, *et al.*, 2004). Osteoid osteoma (GORRA *et al.*, 2002), traumatic aneurysmal bone cysts (HEATLEY, *et al.*, 2004), ossifying fibroma, and fibrous dysplasia (THOMPSON; DITTMER, 2017), and exuberant bone callus should be considered as a differential diagnosis. Exuberant bone formation was excluded because pre-existent bone was normal, there was no history of trauma and radius was no affected.

Microscopically, osteomas consist of trabecular bone formed by osteoblasts, remodeled by osteoclasts (CRAIG; DITTMER; THOMPSON, 2016), with or without lamellar

bone formation (THOMPSON; DITTMER, 2017), corroborating with our findings where the lamellar bone formation was not well distinguished. Among trabeculae, there was sparse connective tissue, which was different in fibrous osteoma and fibrous dysplasia that showing dense connective tissue (CRAIG; DITTMER; THOMPSON, 2016).

Despite the lack of a pathological description of those entities, some aspects can be used to distinguish them. Grossly, the densely packed cancellous bone, as in our case, is indicative of osteoma, while a fibro-osseous tissue will be founded in ossifying fibroma and a densely bone shell in the fibrous dysplasia (THOMPSON; DITTMER, 2017). Previously reports

corroborate our gross and microscopical findings (HIDALGO; PAULSEN, 1998; JAVDANI *et al.*, 2017).

On the other hand, some reports of osteoma in the literature are likely ossifying fibromas and vice versa, and the two may represent different stages of the same tumor (CRAIG; DITTMER; THOMPSON, 2016).

## CONCLUSION

Previously reports of bone neoplasia in birds are mainly focused on the surgical aspects which make gross, clinical history and microscopical description relevant to better understand those entities, improving diagnosis.

## REFERENCES

- CARDOSO, J. F. R. *et al.* Osteoma in a blue-fronted amazon parrot (*Amazona aestiva*). **Journal Of Avian Medicine and Surgery**, [S.L.], v. 27, n. 3, p. 218-221, 2013. doi: 10.1647/2012-010.
- COWAN, M. L. *et al.* Suspected Osteoma in an Eclectus Parrot (*Eclectus roratus roratus*). **Journal Of Avian Medicine and Surgery**, [S.L.], v. 25, n. 4, p. 281-285, dez. 2011. Association of Avian Veterinarians (AAV). <http://dx.doi.org/10.1647/2010-061.1>.
- CRAIG, L. E.; DITTMER, K. E.; THOMPSON, K. G. Bones and joints. In: MAXIE, M. G. (ed.). **Jubb, Kennedy, and Palmer's Pathology of Domestic Animals**. 6. ed. St. Louis: Elsevier, 2016. p. 109.
- EFFRON, M. *et al.* Nature and Rate of Neoplasia Found in Captive Wild Mammals, Birds, and Reptiles at Necropsy. **Jnci: Journal of the National Cancer Institute**, [S.L.], v. 59, n. 1, p. 185-198, jul. 1977. Oxford University Press (OUP). <http://dx.doi.org/10.1093/jnci/59.1.185>.
- FROST, C. Experiences with pet budgerigars. **Veterinary Record**, [S.L.], v. 73, p. 621-626, 1961.
- GARNER, M. M. *et al.* Overview of Tumors: Section II A Retrospective Study of Case Submissions to a Specialty Diagnostic Service. In: LIGHTFOOT, T. L.; HARRISON, G. J. **Clinical Avian Medicine**. Unabridged: Spix Publishing, 2005. p. 565-571.
- GORRA, M. *et al.* OSTEOID OSTEOMA IN A DOG. **Veterinary Radiology**, [S.L.], v. 43, n. 1, p. 28-30, jan. 2002. Wiley. <http://dx.doi.org/10.1111/j.1740-8261.2002.tb00438.x>.
- HAHN, K. A. *et al.* Clinical and pathological characterization of an osteoma in a barred owl. **Avian Pathology**, [S.L.], v. 27, n. 3, p. 306-308, jun. 1998. Informa UK Limited. <http://dx.doi.org/10.1080/03079459808419341>.
- HEATLEY, J. J. *et al.* TRAUMA-INDUCED ANEURYSMAL BONE CYSTS IN TWO PSITTACINE SPECIES (*CACATUA ALBA* AND *NYMPHICUS HOLLANDICUS*). **Journal Of Zoo And Wildlife Medicine**, [S.L.], v. 35, n. 2, p. 185-196, jun. 2004. American Association of Zoo Veterinarians. <http://dx.doi.org/10.1638/03-045>.
- HERFORD, A.S.; STOFFELLA, E.; TANDON, R. Osteomas involving the facial skeleton: a report of 2 cases and review of the literature. **Oral Surgery Oral Medicine Oral Pathology Oral Radiology**, [S.L.], v. 115, n. 2, fev. 2013.
- HIDALGO, P.; PAULSEN, D. B. "What Is Your Diagnosis?". **J Avian Med Surg**, [S.L.], v. 12, n. 4, p. 281-283, 1998.
- JAVDANI, M. *et al.* Extraskeletal osteoma in a canary (*Serinus canaria*). **Veterinary Research Forum**, [S.L.], v. 8, n. 3, p. 265-268, 2017.
- LABAT, M. L. Retroviruses and bone diseases. **Clinical Orthopaedics and related Research**, [S.L.], v. 326, p. 287-309, maio, 1996.
- LATIMER, K. S. Oncology. In: RITCHIE, B. W.; HARRISON, G. J.; HARRISON, L. R. **Avian Medicine: Principles and Application**. Lake Worth, FL: Wingers, 1994. p. 640-672.
- LIGHTFOOT, T.L. Overview of Tumors: Section I - Clinical Avian Neoplasia and Oncology. In: HARRINSON, G. J.; LIGHTFOOT, T. L. (ed.). **Clinical Avian Medicine**. Palm Beach, FL: Spix Publishing; 2005, 2: 560-565.
- PINZÓN-OSORIO, C. A.; GOMEZ, A. P.; ÁLVAREZ-MIRA, D. M. Bilateral osteoma cutis in a Peach-Faced Lovebird (*Agapornis roseicollis*). **The Journal of Veterinary Medical Science**, [S.L.], v. 82, n. 5, p. 536-540, 2020.
- REECE, R. L. Some observations on naturally occurring neoplasms of domestic fowls in the State of Victoria, Australia (1977-87). **Avian Pathology**, [S.L.], v. 25, n. 3, p. 407-447, Jan. 1996.
- REECE, R. L. Observations on naturally occurring neoplasms in birds in the state of Victoria, Australia. **Avian Pathology**, [S.L.], v. 21, n.1, p. 3-32, 1992.
- SÁNCHEZ-GODOY, F.; LEDESMA-RAMÍREZ, I.; MORALES-SALINA, E. A retrospective study of neoplasms in ornamental and pet birds diagnosed at the Hospital de Aves of the Universidad Nacional Autónoma de México (2007-2014). **Brazilian Journal of Veterinary Pathology**, [S.L.], v.13, n. 1, p.1-11, 2020.
- SCHMIDT, R. E.; REAVILL, D.R.; PHALEN, D. N. **Pathology of Pet and Aviary Birds**. 2. ed. Wiley -Blackwell, 2015. p. 213.
- THOMPSON, K.G.; DITTMER, K. E. Tumors of bones. In: MEUTEN, D. J. (ed.). **Tumors in domestic animals**. 5. ed. Ames, Iowa: Wiley and Blackwell, 2017. p.359-365.

