

# Diagnostic applicability of infrared thermography in the evaluation of canine mammary tumors

## *Aplicabilidade diagnóstica da termografia infravermelha na avaliação dos tumores mamários caninos*

André Gustavo Alves Holanda<sup>1\*</sup> , Victória Morais Silva<sup>1</sup> , Larissa de Castro Demoner<sup>1</sup> ,  
Juliana Fortes Vilarinho Braga<sup>1</sup> , Genilson Fernandes de Queiroz<sup>1</sup> 

**ABSTRACT:** Mammary tumors have a high prevalence in bitches and women, and are related to high rates of morbidity and mortality. For the human species, thermography has stood out as a diagnostic tool for breast cancer. However, its clinical benefit in bitches remains unknown. Thus, the goal of the present study was to evaluate the diagnostic applicability of infrared thermography for canine mammary tumors, as well as to correlate tumor temperature with mitotic index and tumor volume. Thermographic and digital images of eight bitches with mammary neoplasms were captured. Thermograms were entered into the FLIR tools software and the temperature of 15 tumor and 15 healthy glands from the contralateral mammary chain was analyzed. There was no significant difference ( $p = 0.786$ ) between the mean temperature of neoplastic ( $33.71^{\circ}\text{C} \pm 1.86$ ) and healthy ( $33.54^{\circ}\text{C} \pm 1.59$ ) glands. There was a negative and moderate correlation between tumor temperature and mitotic index ( $p = -0.52$   $p = 0.049$ ). However, no correlation was detected between mammary temperature and tumor volume ( $p = 0.10$ ). Although thermography allowed no distinction between neoplastic and healthy mammary glands in bitches, it may be promising to assess the proliferative rate of tumors. In addition, malignant neoplasms may be more often hypothermic than healthy tissue.

**KEYWORDS:** Complementary test; thermal imaging; temperature; bitch.

**RESUMO:** Os tumores mamários apresentam alta prevalência em cadelas e mulheres, sendo relacionados a elevadas taxas de morbidade e mortalidade. Para a espécie humana, a termografia tem se destacado como ferramenta diagnóstica do câncer de mama. Entretanto, o seu benefício clínico em cadelas permanece desconhecido. Assim, o objetivo do presente estudo foi avaliar a aplicabilidade diagnóstica da termografia infravermelha para os tumores mamários caninos, bem como correlacionar a temperatura tumoral com o índice mitótico e volume tumoral. Foram capturadas imagens termográficas e digitais de oito cadelas com neoplasias mamárias. Os termogramas foram inseridos no software FLIR tools e analisou-se a temperatura de 15 mamas tumorais e 15 hígidas da cadeia mamária contralateral. Não houve diferença significativa ( $p = 0,786$ ) entre a temperatura média das glândulas neoplásicas ( $33,71^{\circ}\text{C} \pm 1,86$ ) e saudáveis ( $33,54^{\circ}\text{C} \pm 1,59$ ). Houve correlação negativa e moderada entre a temperatura tumoral e índice mitótico ( $p = -0,52$   $p = 0,049$ ). Entretanto, não foi observada correlação entre temperatura e volume tumoral ( $p = 0,10$ ). Apesar da termografia não ter permitido a diferenciação das mamas neoplásicas e saudáveis de cadelas, ela pode ser uma forma promissora para avaliação da taxa proliferativa dos tumores. Além disso, as neoplasias malignas podem apresentar-se mais frequentemente hipotérmicas em relação ao tecido saudável.

**PALAVRAS-CHAVE:** Exame complementar; imagem térmica; temperatura; cadela.

## INTRODUCTION

Mammary tumors are the most frequent in intact female dogs. In Brazil, these tumors account for 16 - 24% of all canine tumors (ANDRADE et al., 2012; KIMURA; GÁRATE; DAGLI, 2012). The predisposing factors are increased age, obesity, intact status or ovariectomy after 2.5

years of age, as well as progestagen treatment (ALENZA et al., 2000).

Mammary tumors are considered a major public health problem in underdeveloped countries (SALAS et al., 2015). In these places, early diagnosis is a difficult task, since visits to the veterinarian are not regular and, in many cases,

<sup>1</sup>Departamento de Ciências Animais, Universidade Federal Rural do Semi-Árido (UFERSA), Mossoró/RN, Brasil

\*Corresponding author: [gustavoholanda.50@gmail.com](mailto:gustavoholanda.50@gmail.com)

Received: 05/09/2022. Accepted: 11/15/2022

the nodule can be small and deep, making clinical examination difficult (PANDEY et al., 2018). Thus, the development of complementary techniques for detecting the disease becomes relevant.

Medical thermography is an imaging test used to monitor the surface temperature of the skin (CHROMY; KLIMA, 2017). In humans, it has been shown to be a promising method for breast cancer diagnosis (GONZALEZ-HERNANDEZ et al., 2019). Moreover, its prognostic role has been the subject of studies, indicating associations between temperature and tumor characteristics, such as: size, necrosis, microvessel density and the expression of estrogen, progesterone, HER-2 protein and Ki67 receptors (YAHARA et al., 2003; TEPPER et al., 2013; ZORE et al., 2015).

In veterinary oncology, clinical research using thermography is still scarce, but shows promising results. Studies point to the contribution of thermograms to distinguishing the biological behavior of skin and soft tissue neoplasms in felines (NITRINI; COGLIATI; MATERA, 2020), as well as potential application as a diagnostic tool for perianal tumors (ZANUTO et al., 2021) and the canine osteosarcoma (SUNG et al., 2019)

For bitches, a study reported an increase in temperature of mammary tumors compared to glands of healthy females (PAVELSKI et al., 2015). However, its diagnostic and prognostic role is unclear. Thus, the goal of this study was to evaluate the applicability of infrared thermography for detecting canine mammary tumors, as well as to correlate the temperature with the mitotic index and tumor volume.

## MATERIAL AND METHODS

The study was approved by the Animal Ethics Committee (CEUA) of the Federal Rural University of the Semi-Arid Region (UFERSA) under opinion 10/19. Patients were included in the study after signing the informed consent.

Eight bitches with mammary tumors were treated at the Veterinary Hospital of Federal Rural University of Semi-Arid Region, Mossoró-RN. Patients underwent general clinical examination and evaluation by blood count, serum biochemistry, chest radiography and abdominal ultrasound. Tumors were measured with a caliper to calculate the tumor volume using the following formula:

$$V = \frac{a \times b \times c \times \pi}{6}$$

The region of interest was shaved with an electric clipper and 15 minutes later, a FLIR SC620 model camera was positioned 50 cm away, forming a 90° angle to capture digital and thermographic images. Values of ambient humidity and temperature were registered by digital thermohygrometer (7663.02.0.00, Incoterm, Brazil) for later homogenization. The average temperature of tumoral and contralateral healthy mammary gland was obtained by delimiting

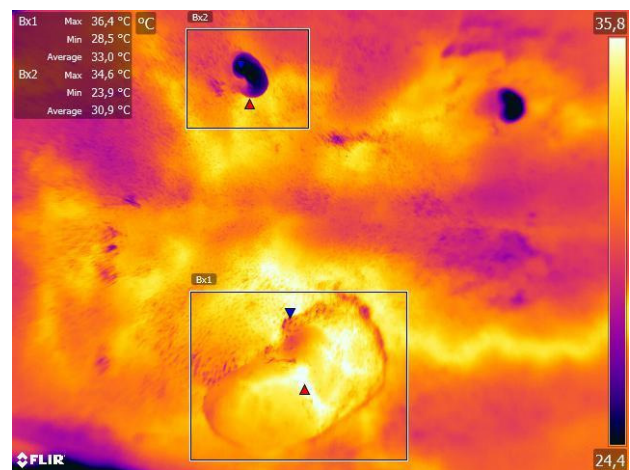
rectangles in the FLIR tools software. When it was not possible to assess the gland immediately contralateral to the neoplasm, the temperature of the closest healthy gland was measured. The rectangle size was set at 35 mm high and 30 mm wide to include all glands, regardless of the animal size. For neoplasms larger than those established, the rectangle was delimited in order to encompass the entire formation. The emissivity value adopted was 0.98.

Patients underwent surgical treatment, which consisted of regional or unilateral mastectomy, based on the location and size of the tumors (CASSALI et al., 2020). Mammary tumors were fixed in a 10% formalin-buffered solution for 48 hours. Then, the tissue samples were dehydrated in increasing ethanol concentrations, diaphanized in xylene and embedded in paraffin wax to obtain 4-µm thick serial sections, which were stained with hematoxylin-eosin for analysis under a light microscope (LUNA, 1968). Histopathological assessment was performed as previously described (GOLDSCHMIDT et al., 2011; CASSALI et al., 2020). The mitotic index was calculated in 10 high power fields (HPF) (GOLDSCHMIDT et al., 2011).

Statistical analysis was performed using SPSS 20 software (SPSS Inc., Chicago, II). Mean temperature values of tumor and healthy glands were normally distributed using the Shapiro-Wilk test and compared using Tukey's parametric test. The correlation between the mean temperature of neoplastic glands with the mitotic index and the tumor volume was estimated by Pearson's Correlation. p values ≤ 0.05 were considered significant.

## RESULTS

Tumor (n=15) and healthy glands (n=15) from eight non-neutered bitches were evaluated by thermography (Figure 1). The mean age of the patients was 8.5 years (ranging from 5 to 12 years) and the breed distribution was as follows: mixed breed (5/8), pinscher (1/8), poodle (1/8) and akita (1/8).



**Figure 1.** Thermography of canine mammary tubular carcinoma with mean temperature (Bx1 = 33°C) higher than the contralateral healthy gland (Bx2 = 30.9°C).

The histopathological diagnosis indicated the occurrence of 10 malignant and five benign neoplasms, including: tubular carcinoma (7/15), carcinoma in mixed tumor (1/15), complex carcinoma (1/15), micropapillary carcinoma (1/15) and benign mixed tumor (5/15). Tumors were mainly located in the cranial (5/15) and caudal (5/15) abdominal mammary glands, followed by the thoracic caudal (3/15) and inguinal (2/15). Values of tumor volume and mitotic index are presented according to the biological behavior (Table 1).

Thermography showed no difference between temperature of mammary tumors and healthy glands (Table 2). In 60% (6/10) of the cases, the mean temperature of malignant tumors was lower than healthy glands (Figure 2), while for benign tumors this occurred in only 20% (1/5) of the evaluations. There was a moderate negative correlation between temperature and mitotic index ( $\rho = -0.516$ ,  $p = 0.49$ ). However, no association was detected between tumor temperature and volume ( $\rho = -0.432$ ,  $p = 0.102$ ).

## DISCUSSION

The study analyzed the use of infrared thermography to differentiate the temperature between neoplastic and healthy


**Table 1.** Mean and standard deviation of tumor volume and mitotic index in benign and malignant mammary tumors of bitches.

Group	Tumor Volume (cm <sup>3</sup> )	Mitotic Index / 10HPF
Benign tumors	5.96 ± 7.54	1.46 ± 0.55
Malignant tumors	11.68 ± 24.57	5.15 ± 3.40

**Table 2.** Mean and standard deviation of temperature in mammary tumors and healthy glands of bitches.

Group	Mean (°C)	P - value
Mammary tumors	33.71 <sup>a</sup> ± 1.86	0.786
Healthy glands	33.54 <sup>a</sup> ± 1.59	

Values followed by the same letter are not significantly different.



**Figure 2.** Thermography of canine mammary micropapillary carcinoma with mean temperature (Bx1 = 31.4°C) lower than the contralateral healthy gland (Bx2 = 32.3°C).

mammary glands of bitches. At the same time, we performed the pioneering correlation between temperature and clinical-histopathological characteristics of tumors. For this study, all the experimental recommendations of the technique were followed, including acclimatization of patients, use of equipment with good resolution, maintenance of a pattern in angle and distance between the camera and the region of interest, as well as standardization of emissivity for biological tissues.

In women, thermography can be used as a screening test for diagnosis of breast cancer (GONZALEZ-HERNANDEZ et al., 2019). The use of the technique is based on the process of heat generation by cancer cells, from the mechanisms of angiogenesis, nitric oxide release, increased metabolic rate and vasodilation (SINGH; SINGH, 2020). Thus, thermograms may indicate an increase in tumor temperature in relation to adjacent areas (ARORA et al., 2008).

In veterinary medicine, a significant difference between the temperature of mammary glands with tumors (37.86 °C) and a control healthy group of bitches (35.07 °C) was reported (PAVESKI et al., 2015). We found no significant difference between the affected (33.7 °C) and healthy (33.5 °C) groups. This difference in behavior can be because we obtained a large number of hypothermic tumors (7/15) in relation to contralateral mammary glands. Among them, malignant neoplasms accounted for 85% (6/7). Although it was not directly evaluated, the frequent presence of necrosis in malignant mammary tumors probably has contributed to this result. Due to the impaired local microcirculation, these areas may be cold by thermography. Previous studies have also related necrosis as a factor for hypothermia in canine perianal tumors (ZANUTO et al., 2021) and in women with breast cancer (YAHARA et al., 2003).

Chronic inflammation is present in neoplastic processes and stimulates the release of cytokines and chemokines (KASZAK et al., 2018). The inflammatory infiltrate found in malignant mammary tumors commonly produces IL-6, IL-1 $\alpha$  and IL-1 $\beta$ , which upregulate COX-2, increasing tumor expression of VEGF and angiogenesis. Tumor cells produce IL-8, TNF- $\alpha$ , TGF- $\beta$  and nitric oxide, which are also angiogenic stimulators (ESQUIVEL-VELÁZQUEZ et al., 2015; IRAC et al., 2019). For canine species, cytokines may vary according to the biological behavior and histological type of mammary tumors (ANDALUZ et al., 2016; IRAC et al., 2019), acting as possible interfering factors in temperature variation.

One of our intentions was to correlate tumor temperature with prognostic factors. We adopted the mitotic index (MAINENTI et al., 2014; CARVALHO et al., 2016) and tumor size (NGUYEN et al., 2017; CANADAS et al., 2018) that are associated with a shorter survival time in bitches with mammary tumors. In addition, they were available for all neoplasms studied.

The mitotic index is a useful and simple method for analyzing cellular proliferation of neoplasms. It is known that one of the characteristics of cancer is the high rate of cell replication, which can lead to increased metabolic demand, hypoxia and consequent necrosis (ORD et al., 2007; KUZNETSOV; KOLOBOV, 2018). Thus, we believe that the inverse relationship between temperature and mitotic index may have occurred due to the impairment of tumor microcirculation by necrosis as cell proliferation increased.

The tumor volume was calculated by the ellipsoid formula, which considers the three gross dimensions: height, width, and depth. However, we did not identify an association between this variable and heat production of neoplasms. In women with breast cancer, a previous study failed to identify a relationship between tumor size and temperature. Nevertheless, malignant phenotypes identified by immunohistochemistry showed higher temperatures, suggesting that heat generation is mainly related to aggressiveness (ZORE et al., 2015). Thus, future studies can assess the correlation between temperature with prognostic markers in bitches with mammary tumors, including progesterone, estrogen, Ki-67, and COX-2 (KASZAK et al., 2018).

Mammary tumors present clinical, morphological, and molecular heterogeneity that can interfere with individual temperature. Thus, the results obtained here should be interpreted with caution due to the small number of samples. For further analysis, we believe that computer-aided diagnosis (CAD) is an alternative for differentiating thermal patterns between affected and healthy glands. This is an algorithmic tool capable of automating the interpretation of thermal imaging (RAGHAVENDRA et al., 2019). It has been effective in reducing human error in the detection of breast cancer in women, with accuracy rates ranging from 71.8% (NICANDRO et al., 2013) to 100% (SILVA et al., 2016).

## CONCLUSIONS

Thermography does not seem to contribute to the differentiation of temperature between mammary tumors and healthy glands in bitches. However, malignant neoplasms may be more often hypothermic than healthy tissues. In addition, the technique may be a promising way to assess the proliferative rate of tumors. Future studies with a large number of samples should be conducted to establish the diagnostic and prognostic role of the technique.

## REFERENCES

- ALENZA, M. D. P. et al. Factors influencing the incidence and prognosis of canine mammary tumours. **Journal of Small Animal Practice**, v. 41, n. 7, p. 287-291, 2000.
- ANDALUZ, A. et al. Pro-inflammatory cytokines: useful markers for the diagnosis of canine mammary tumours. **The Veterinary Journal**, v. 210, p. 92-94, 2016.
- ANDRADE, R L.F.S. et al. Tumores de cães e gatos diagnosticados no semiárido da Paraíba. **Pesquisa Veterinária Brasileira**, v. 32, n. 10, p. 1037-1040, 2012.
- ARORA, N. et al. Effectiveness of a noninvasive digital infrared thermal imaging system in the detection of breast cancer. **The American Journal Of Surgery**, v. 196, n. 4, p. 523-526, 2008.
- CANADAS, A. et al. Canine Mammary Tumors: comparison of classification and grading methods in a survival study. **Veterinary Pathology**, v. 56, n. 2, p. 208-219, 2018.
- CARVALHO, M. I. et al. Ki-67 and PCNA Expression in Canine Mammary Tumors and Adjacent Nonneoplastic Mammary Glands. **Veterinary Pathology**, v. 53, n. 6, p. 1138-1146, 2016.
- CASSALI, G. et al. Consensus for the Diagnosis, Prognosis and Treatment of Canine Mammary Tumors – 2019. **Brazilian Journal of Veterinary Pathology**, v. 13, n. 3, p. 555-574, 2020.
- CHROMY, A.; KLIMA, O. A 3D Scan Model and Thermal Image Data Fusion Algorithms for 3D Thermography in Medicine. **Journal Of Healthcare Engineering**, v. 2017, p. 1-9, 2017.
- ESQUIVEL-VELÁZQUEZ, M. et al. The Role of Cytokines in Breast Cancer Development and Progression. **Journal of Interferon & Cytokine Research**, v. 35, n. 1, p. 1-16, 2015.
- GOLDSCHMIDT, M. et al. Classification and Grading of Canine Mammary Tumors. **Veterinary Pathology**, v. 48, n. 1, p. 117-131, 2011.
- GONZALEZ-HERNANDEZ, J, et al. Technology, Application and Potential of Dynamic Breast Thermography for the Detection of Breast Cancer. **International Journal Of Heat And Mass Transfer**, v. 131, p. 558-573, 2019.
- IRAC, S. et al. Cytokine Expression in Canine Lymphoma, Osteosarcoma, Mammary Gland Tumour and Melanoma: Comparative Aspects. **Veterinary Sciences**, v. 6, n. 2, p. 37, 2 abr. 2019.
- KASZAK, I. et al. Current biomarkers of canine mammary tumors. **Acta Veterinaria Scandinavica**, v. 60, n. 1, p. 1-1, 29 out. 2018.
- KIMURA, K. C.; GÁRATE, A. P.; DAGLI, M. L. Z. Retrospective Study of Neoplasms in Domestic Animals: a Survey Between 1993 and 2002 of the Service of Animal Pathology, Department of Pathology, School of Veterinary Medicine and Animal Science, University of Sao Paulo, Southeast Brazil. **Brazilian Journal Of Veterinary Pathology**, v. 2, n. 5, p. 60-69, 2012.
- KUZNETSOV, M. B.; KOLOBOV, A. V. Transient alleviation of tumor hypoxia during first days of antiangiogenic therapy as a result of the therapy-induced alterations in nutrient supply and tumor metabolism – Analysis by mathematical modeling. **Journal Of Theoretical Biology**, v. 451, p. 86-100, 2018.

- LUNAL, G. Manual of histologic staining methods of the Armed Forces Institute of Pathology. 3<sup>rd</sup> ed, New York: **McGraw Hill**. p. 258, 1968.
- MAINENTI, M. et al. Oestrogen and progesterone receptor expression in subtypes of canine mammary tumours in intact and ovariectomised dogs. **The Veterinary Journal**, v. 202, n. 1, p. 62-68, 2014.
- NGUYEN, F. et al. Canine invasive mammary carcinomas as models of human breast cancer. Part I: natural history and prognostic factors. **Breast Cancer Research And Treatment**, v. 167, n. 3, p. 635-648, 2017.
- NICANDRO, C. et al. Evaluation of the Diagnostic Power of Thermography in Breast Cancer Using Bayesian Network Classifiers. **Computational And Mathematical Methods In Medicine**, v. 2013, p. 1-10, 2013.
- NITRINI, A. G. C.; COGLIATI, B.; MATERA, J. M. Thermographic Assessment of Skin and Soft Tissue Tumors in Cats. **Journal of Feline Medicine And Surgery**, v. 23, n. 6, p. 513-518, 2020.
- ORD, J. J. et al. An Investigation Into the Prognostic Significance of Necrosis and Hypoxia in High Grade and Invasive Bladder Cancer. **Journal Of Urology**, v. 178, n. 2, p. 677-682, 2007.
- PANDEY, M. et al. Over-expression of Mammaglobin-B in Canine Mammary Tumors. **Bmc Veterinary Research**, v. 14, n. 1, 2018.
- PAVELSKI, M. et al. Infrared Thermography in Dogs with Mammary Tumors and Healthy Dogs. **Journal Of Veterinary Internal Medicine**, v. 29, n. 6, p. 1578-1583, 2015.
- RAGHAVENDRA, U. et al. Computer-aided diagnosis for the identification of breast cancer using thermogram images: a comprehensive review. **Infrared Physics & Technology**, v. 102, p. 103041, nov. 2019.
- SALAS, Y. et al. Epidemiological Study of Mammary Tumors in Female Dogs Diagnosed during the Period 2002-2012: a growing animal health problem. **Plos One**, v. 10, n. 5, p. e0127381, 2015.
- SILVA, L. et al. Hybrid analysis for indicating patients with breast cancer using temperature time series. **Computer Methods And Programs In Biomedicine**, v. 130, p. 142-153, 2016.
- SINGH, D.; SINGH, A. K. Role of Image Thermography in Early Breast Cancer Detection - Past, Present and Future. **Computer Methods And Programs In Biomedicine**, v. 183, p. 105074, 2020.
- SUNG, J. et al. Medical Infrared Thermal Imaging of Canine Appendicular Bone Neoplasia. **Bmc Veterinary Research**, v. 15, n. 1, p. 430, 2019.
- TEPPER, M. et al. Thermographic Investigation of Tumor Size, and its Correlation to Tumor Relative Temperature, in Mice with Transplantable Solid Breast Carcinoma. **Journal Of Biomedical Optics**, v. 18, n. 11, p. 111410, 2013.
- YAHARA, T. et al. Relationship Between Microvessel Density and Thermographic Hot Areas in Breast Cancer. **Surgery Today**, v. 33, n. 4, p. 243-248, 2003.
- ZANUTO, E. B. M. et al. Diagnostic Value and Application of Infrared Thermography in the Analysis of Circumanal Gland Tumors. **Frontiers In Veterinary Science**, v. 8, p. 692221, 2021.
- ZORE, Z. et al. Association of Clinical, Histopathological and Immunohistochemical Prognostic Factors of Invasive Breast Tumors and Thermographic Findings. **Infrared Physics & Technology**, v. 68, p. 201-205, 2015.

