







Outbreaks of *Neoechinorhynchus buttnerae* (Acanthocephala) infection in raised semi-intensively *Colossoma macropomum* in Theobroma, Rondônia state, Western Amazon

Surtos de infecção por Neoechinorhynchus buttnerae (Acanthocephala) em Colossoma macropomum cultivado semi-intensivamente em Theobroma, estado de Rondônia, Amazônia Ocidental

Carina Fernanda Pereira de Jesus Lucena¹ , Jerônimo Vieira Dantas Filho^{2*} ,
Aristoteles Marcos Silva Ferreira¹ , Ana Sabrina Coutinho Marques Rocha^{1,3} ,
Sandro de Vargas Schons² , Paulo Henrique Gilio Gasparotto^{2,3} 

ABSTRACT: The aim of this study was to describe two outbreaks of *Neoechinorhynchus buttnerae* parasitizing *Colossoma macropomum* raised semi-intensively in the Theobroma municipality, Rondônia state, Brazil. It was reported by owner that the animals had a history of poor weight gain and decreased food intake. *C. macropomum* that weighed around 1.5 kg were clinically evaluated where the body surface, fins, buccal and brachial cavity were carefully analyzed and no changes were found. *N. buttnerae* was the only intestinal parasite found in the specimens studied, and its distribution pattern shows a preference for the posterior portion of the intestine of *C. macropomum*. All 50 fish examined were parasitized by at least one *N. buttnerae*. This parasite was found in the digestive system of the examined fish. 100% of prevalence, 430 of intensity, 8.6 of average intensity and average abundance were found. Although there was no record of mortalities due to acanthocephalosis, damage that compromised the feed conversion of the fish was recorded. *C. macropomum* were infected by ingesting a crustacean containing cystacanth, the infective larval form of the parasite. Damage, such as presence of nodules, hypertrophy of goblet cells, thickening of the muscle layer, metaplasia in muscle tissue, severe edema from leukocyte infiltration in blood vessels and necrotic foci, were found in the intestine due to high infection rates of *N. buttnerae*. That said, inspection activities are essential for the preservation of consumer and animal health.

KEYWORDS: Fish farming; fish healthiness; intestinal parasite; preventive measures.

RESUMO: O objetivo deste estudo foi descrever dois surtos de *Neoechinorhynchus buttnerae* parasitando *Colossoma macropomum* em cultivo semi-intensivo no município de Theobroma, estado de Rondônia, Brasil. Foi relatado pelo proprietário que os animais apresentavam histórico de baixo ganho de peso e diminuição da ingestão alimentar. *C. macropomum* que pesavam em torno de 1,5 kg foram avaliados clinicamente onde a superfície corporal, nadadeiras, cavidade bucal e braquial foram cuidadosamente analisadas e não foram encontradas alterações. *N. buttnerae* foi o único parasita intestinal encontrado nos espécimes estudados, e seu padrão de distribuição mostra uma preferência pela porção posterior do intestino do *C. macropomum*. Todos os 50 peixes examinados estavam parasitados por pelo menos um *N. buttnerae*. Este parasita foi encontrado no sistema digestivo dos peixes examinados. Foram encontrados 100% de prevalência, 430 de intensidade, 8,6 de intensidade média e de abundância média. Apesar de não haver registro de mortalidade por acantocéfaloze, foram registrados danos que comprometeram a conversão alimentar dos peixes. *C. macropomum* foram infectados pela ingestão de um crustáceo contendo cistacanto, a forma larval infectante do parasita. No intestino foram encontrados danos como presença de nódulos, hipertrofia de células caliciformes, espessamento da camada muscular, metaplasia no tecido muscular, edema grave por infiltração leucocitária nos vasos sanguíneos e focos necróticos devido às altas taxas de infecção de *N. buttnerae*. Dito isso, as atividades de fiscalização são essenciais para a preservação da saúde do consumidor e do animal.

PALAVRAS-CHAVE: Piscicultura; sanidade de peixes; parasitoses intestinais; medidas preventivas.

¹Centro Universitário São Lucas (Unisl), Curso de Medicina Veterinária, Ji-Paraná, RO, Brazil

²Universidade Federal de Rondônia (UNIR), Programa de Pós-Graduação em Ciências Ambientais, Rolim de Moura, RO, Brazil

³Universidade Federal do Acre (UFAC), Programa de Pós-Graduação em Sanidade e Produção Animal Sustentável na Amazônia Ocidental, Rio Branco, AC, Brazil

*Corresponding author: carinaluc98.cl@gmail.com

Received: 06/28/2022. Accepted: 03/09/2023

INTRODUCTION

It is estimated that the world population is expected to grow by about two billion people in the next 30 years, accumulating a total of 9.7 billion in 2050 (BAHAR et al., 2020). Due to this population growth, there is an increase in fish consumption and consequently greater aquaculture production in Latin America with about more than 49% increase, according to a report by the Food and Agriculture Organization (FAO) in year 2018. As stated in Brazilian Fish Farming Yearbook, from Associação Brasileira da Piscicultura (Peixe BR), Brazilian fish farming has had significant growth in recent years and in 2021 had a positive performance, with a total production of 841,005 tons, which represents a growth of 4.7% compared to com 2020. Fish production in year 2021 was led by states of Paraná (188,000 tons), followed by São Paulo (81,640 tons) and Rondônia (59,600 tons) (PEIXE BR, 2022).

The States of the Brazilian Amazon have great potential for growth in the Fish farming, due to their regional particularities, mainly from a cultural point of view, because fish is in the local culinary tradition, which defines the Amazon region as the largest consumer of fish in Brazil (PETENUCCI et al., 2019). The production of native species is mainly represented by *Colossoma macropomum* (Cuvier, 1818), which participated with 19% of the total production in year 2019, around 101,079 tons (VALENTI et al., 2021). In the Rondônia state, *C. macropomum* is the most produced species with great advantage, corresponding to about 90% of farmed fish. Municipalities of Ariquemes and Cujubim are the main producers in Rondônia state, which has its most structured local production arrangement in the Immediate Geographical Region of Ariquemes (IBGE, 2020).

C. macropomum is a species of great relevance to economy of the North region of Brazil and is the second most cultivated species in the whole country, where it has a percentage of 39.8% of the entire national production, behind only Nile tilapia (*Oreochromis niloticus*) (PEIXE BR, 2020). In year 2018, there was a drop of about 4.7% in the production of native species, such as *C. macropomum* compared to previous year, this decline is due to inadequate management practices and the emergence of parasitic outbreaks with serious losses in Fish farming, for example acanthocephalosis outbreak (PEIXE BR 2020). That said, among some factors that hinder greater productivity in Brazilian aquaculture, the health factor has been a problem both for producers who want to avoid losses due to emergence of parasitic and infectious diseases, and for consumers who want a good quality product. (CAVALCANTE et al., 2017; SOUZA et al., 2019). In production systems, high stocking density is common, which, due to stress, leads to increased contact of fish with parasites, enhancing transmission and infection rates, which can lead to epizootic disease outbreaks (COSTA et al., 2018).

Among the endoparasites that affect Fish farming, helminths are constantly neglected as disease-causing agents, even

though they are a major problem in fish farming (CHAGAS et al., 2012). Among the main parasites that affect the production of *C. macropomum* in Northern Brazil, the parasites of the phylum Acanthocephala stand out, which have shown a limiting agent in the cultivation of this fish. canthocephala is monophyletic, where the species are exclusively parasitic, with no free-living phase (GONÇALVES et al., 2022). The species *Neoechinorhynchus buttnerae* (GOLVAN, 1956) can cause great losses in the production chain of *C. macropomum*. Helminth compromises nutrient absorption, causes cachexia and heterogeneous populations, which can cause up to 100% mortality in fish farming (CHAGAS et al., 2019). In cases of severe infection by *N. buttnerae* at necropsy, stiffening and thickening of the intestinal wall is observed, also associated with mucous intestinal secretion with a catarrhal aspect and yellowish color. The pathogenesis of *N. buttnerae* stems from mechanical action of the parasite by attaching its proboscis to intestinal wall.

The effects of lesions can amplified due to displacement of helminths at the sites of infection, which demonstrates the potential that *N. buttnerae* has to compete with the host's food and reduce the absorption rate due to lesions in the digestive tract (VALDÃO et al., 2019). Penetration of *N. buttnerae* proboscis into intestinal mucosa of the host can cause histopathological changes in intestine, such as metaplasia, epithelial lesions, intestinal lumen obstruction, villous destruction, granulomatous reactions and, in some more severe cases, peritonitis, excessive hemorrhage and epithelial necrosis (LOURENÇO et al., 2017; AGUIAR et al., 2018). The life cycle of Acanthocephala is indirect or heteroxenous, and requires the presence of a definitive vertebrate host and an arthropod as an intermediate host. *N. buttnerae* uses *C. macropomum* as the only definitive host and the ostracoda *Cypridopsis vidua* as an intermediate (LOURENÇO et al., 2017).

Brazilian Fish farming has been consolidating and expanding, becoming the main activity of many producers, mainly in the North region of Brazil. *C. macropomum* is one of the main species cultivated in Brazilian Fish farming, and it has gained prominence especially in the market due to its high level of consumer acceptance. However, the high stocking densities, the inadequate management and the lack of technical knowledge have harmed the health of the fish, causing outbreaks of parasites, which compromises the production and commercialization of fish.

In Western Amazon region, *C. macropomum* farms have been suffering from parasitism of the species *N. buttnerae*. Therefore, in order to avoid outbreaks caused by helminth parasitism, this study performed morphological characterization and indicated the prevention of parasitic outbreaks. In view of the information presented, the aimed of this study was to describe two outbreaks of *N. buttnerae* parasitizing *C. macropomum* in raised semi-intensively in Theobroma municipality, Rondônia state, Brazil.

MATERIAL AND METHODS

Fish farm conditions

The water in the supply dam and tanks did not present a critical eutrophication situation. Although we can inform the water source was not treated before being used. In addition, the fish farmer did not have a mechanical aerator to improve the oxygenation of the water in the tanks. It is interesting to clarify that the fish farmer stated that he frequently monitors water quality. And it was found that the water quality values were adequate for the cultivation of *C. macropomum*. The variables analyzed in supply dam and tanks were pH, dissolved oxygen (mg/L), electrical conductivity ($\mu\text{S}/\text{cm}^2$) and temperature ($^{\circ}\text{C}$) *in situ*, using a previously calibrated multiparametric probe; Total ammonia ($\mu\text{g}/\text{L}$) was measured in the laboratory, and the water transparency (cm) was determined *in situ* using the Secchi disk.

Although the variables water quality were found suitable, it was noted that fish were found in a state of discomfort, erratic swimming, and in their dorsal region scratches were seen. These scratches are caused by the fish themselves, in an uncomfortable state they scrape themselves on the slopes of the tank and/or the drains. Given the overview, the fish farmer declared that his fish farm annually has parasitic infestations of Acanthocephala, Argulus and Perulernaea.

Study area

Have been reported two mortality outbreaks were reported in *C. macropomum* raised semi-intensively in commercial fish

farms in Theobroma municipality, Rondônia state, in geographical coordinates $10^{\circ}17'28.2''\text{S}$ $62^{\circ}37'43.0''\text{W}$ (Figure 1), between January and May 2022. From each outbreak, the intestine of three recently euthanized fish were sent for necropsy in the Laboratório de Parasitologia Veterinária, Centro Universitário São Lucas (UniSL), Campus of Ji-Paraná. The clinical and epidemiological history was obtained from the fish farmers and responsible veterinarian.

Infection report

The study was carried out through parasitological analysis of samples of *N. buttnerae* infecting the small intestine *C. macropomum*, which was submitted to parasitological analysis in the laboratory. The fish were made available by the fish farmers. They belonged to a private property in Theobroma municipality, Rondônia state. This fish farm has *C. macropomum* breeding in supply dam and tanks, where fish are treated with commercial feed. It was reported by the fish farmers that the fish had a history of low weight gain and decreased food intake. *C. macropomum* weighing about 1.5 kg (Figure 2) was clinically evaluated where the body surface, fins, buccal and brachial cavity were carefully analyzed.

The fish farmers performed euthanasia for brain concussion, according to training carried out by other researchers. Followed by necropsy and intestinal removal. The alimentary canal was removed entirely, making a transversal cut in the esophagus and a cut in the rectum near the urogenital papilla. The viscera samples were stored separately in sterile sealed plastic bags, labeled and kept on ice in an isothermal

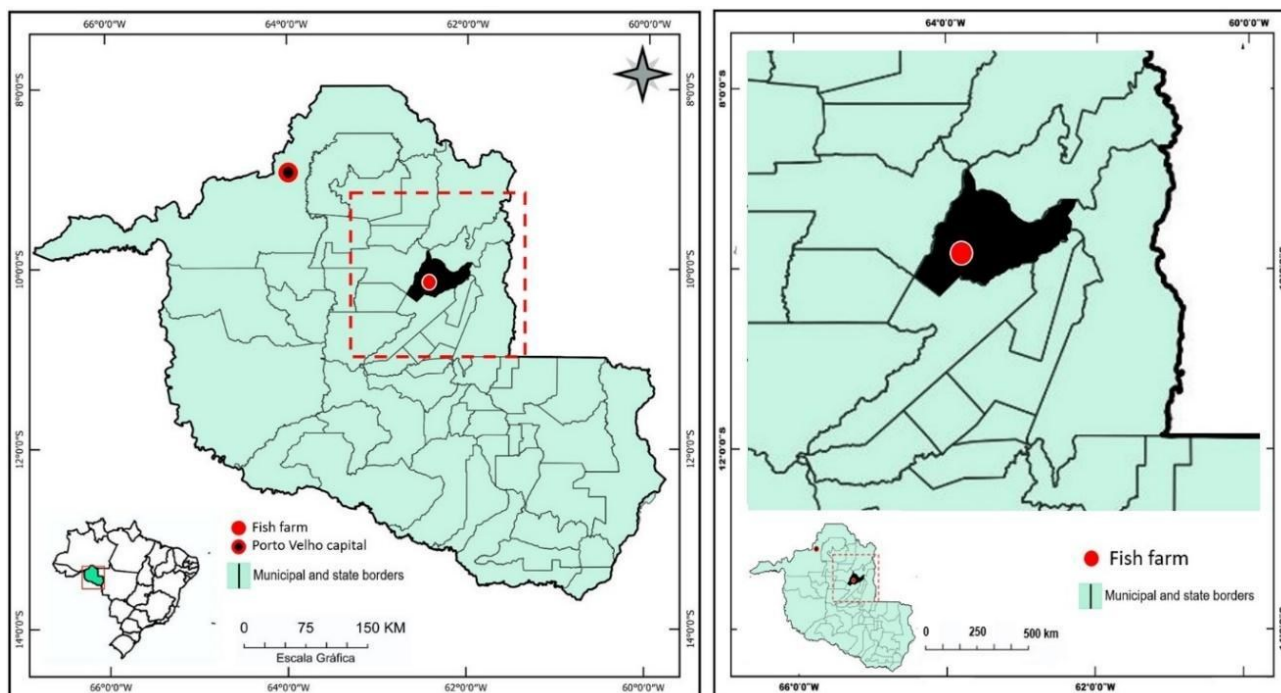


Figure 1. Geographic location of Theobroma municipality, Rondônia state, Brazil.

box and sent to the Laboratory. The necropsy steps mentioned above were performed according to methodology of Jerônimo et al. (2017).

In the laboratory, the intestine was carefully dissected and the presence of *N. buttnerae* verified, with support from specialized Literature for identification of intestinal parasites (VALLADÃO et al., 2019; JERÔNIMO et al., 2022). Acanthocephala were removed from the intestine and fixed in an AFA solution (alcohol – Formaldehyde and Acetic acid) under coverslip pressure where they were analyzed, examined and described under optical microscopy (OLIVEIRA et al., 2019). The intestine was examined for abnormalities such as abnormal positions, bumps, discolorations, parasite cysts, lesions and other pathological signs that could be caused by Acanthocephala. The parasites were processed and identified according to Rocha et al. (2018).

Regarding the statistical analysis of the parasite indices, a quantitative approach was used to identify, at the level of the parasitic infrapopulation, the ecological descriptors of prevalence, abundance, average abundance, intensity and average intensity for species of parasites found in fishes. Prevalence was calculated through the number of infected hosts in relation to the number of examined hosts multiplied by 100. While the intensity was found by the number of individuals

of a parasite species in a host. The average intensity was then defined by the total parasites number of a species found in the sample divided by the number of individuals infected with each species of parasite. Regarding the average abundance, it was defined by the total number of individuals infected with a species of parasite divided by the total number of infected individuals (BUSH et al. 1997).

The data obtained were stored and organized in Epi info™ software, version 3.5.3 - 2011 (OS: MS-Windows, C Sharp programming language). In this way, they were transformed into information and showed in results. For data analysis, the Jamovi software, version 2.3.18, made available by the Universidade Federal do Pará (UFPA) was used.

RESULTS AND DISCUSSIONS

In the current study, in dry season the water quality parameters of tanks showed average values of 6.89 pH, 4.67 mg/L dissolved oxygen, 70.00 $\mu\text{S}/\text{cm}^2$ electrical conductivity, 30.22°C temperature, 1.14 $\mu\text{g}/\text{L}$ total ammonia and 58.00 cm water transparency. While the water quality parameters of supply dam showed average values of 6.60 pH, 4.88 mg/L dissolved oxygen, 80.00 $\mu\text{S}/\text{cm}^2$ electrical conductivity, 29.62°C temperature, 1.14 $\mu\text{g}/\text{L}$ total ammonia and 53.00 cm water transparency. These average values are suitable for the cultivation of *C. macropomum* according to Cavali et al. (2021).

C. macropomum were found sick in Theobroma municipality, Rondônia state, exhibiting marked emaciation (Figure 3 A) and intestine with severe infestation by *N. buttnerae* (Acanthocephala) (Figure 3 B, C and D), shown spacing of the intestinal wall (arrows).

All 50 fish examined were parasitized by at least one *N. buttnerae* (Acanthocephala). This parasite was found in the digestive system of the examined fishes. Therefore, 100% of prevalence, 430 of intensity, 8.6 of average intensity and 8.6




Figure 2. (A) *C. macropomum* cachectics with suspected parasitosis, in a fish farm in the municipality of Theobroma, state of Rondônia, with a record of diseases and mortality (arrows point to fish with erratic swimming at the edge of the tank). (B) One of the dead fish on the edge of the supply dam, evidence of cachexia and growth retardation. Serious situation of one of the parasitized fish found dead floating in one of the fish farms.

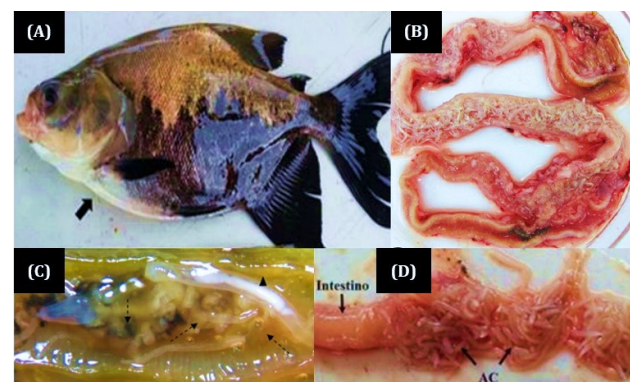


Figure 3. *C. macropomum* parasitized by *N. buttnerae* (Acanthocephala). (A) *C. macropomum* found sick and apathetic, and it is possible to observe belly with apparent swelling (arrow is pointing to edema region). (B) Fish open alimentary canal exposing the parasitized intestine. (C) Juveniles (dotted arrow) and adults (arrow tip) of *N. buttnerae*. (D) Signs of small lesions (ruptures) in the intestinal wall (arrows AC).

of average abundance were found (Table 1). Barreto et al. (2019) published a study similar to the current study, in two fish farms in the Cacaulândia municipality, Rondônia state. These authors reported parasitic infestation by *N. buttnerae* in 60 *C. macropomum* with average standard length of 42.13 ± 2.71 and 38.83 ± 0.23 cm. Of the 60 fish, 59 were hosting at least one parasite in the digestive system. Therefore, these authors found prevalences of 96.67 and 100%, 730 and 140 of intensity, 235.67 and 48.27 of average intensity and 228.10 and 48.27 of average abundance.

The Table 1 shows the parasitological indices where it is important to emphasize that the history of the property did not obtain any cases until the present moment. The parasitic patterns observed in this study confirm infection of *N. buttnerae* in small intestine of *C. macropomum* from fish farm. It is possible to observe *N. buttnerae* with its invaginated proboscis and the upper hooks, which are larger than the lower hooks (Figure 4), as observed in study by Lourenço et al. (2018). *N. buttnerae* was the only intestinal parasite found in the specimen studied, and its distribution pattern shows a preference for posterior portion of the intestine (small intestine) of *C. macropomum*. Likewise, Jeronimo et al. (2017) reported presence of the parasite in small intestine of the host. The parasites found had an average of 2.5 cm, (Figure 4) similar data appear in study by Barreto et al. (2019), where helminths were about 2.7 cm long. Pereira et al. (2018) recorded *N. buttnerae* up to 4 cm. The available *C. macropomum* showed cachexia where it should have weighed between 2.0 and 3.5 kg, according to length presented by species at first sexual maturation (BAHAR et al., 2020).

Area of occurrence of this helminth has increased in recent years, mainly in Northern region of Brazil, infecting *C. macropomum* (JERÔNIMO et al., 2017; MATOS et al., 2017; PEREIRA et al., 2018) with the first record of high infection made by Malta et al. (2001) in a region close to Manaus city, Amazonas state. When fish are confined to high stocking densities, nutritional problems begin to arise. As a result of stress, the animals start to eat less, causing excess feed in the tank water, which makes them more susceptible to infectious or parasitic diseases (BELO et al., 2014).

When the animal is infected by more than one species of parasite in the intestine, interspecific competition occurs, which causes the most abundant species to shown dominance, with a preference for some areas of the digestive tract (GONÇALVES et al., 2022). Cestoids prefer the posterior

portion of the intestine. When co-infection occurs, the high densities of Acanthocephala shown dominate the posterior portion of the intestine, resulting in migration of cestodes to anterior region of the intestine (GRAY; HAYUNGA, 1980). In the current study, the only species of parasite found in the intestine of *C. macropomum* was the Acanthocephala *N. buttnerae*, found with a high frequency in posterior part of the intestine, which governs the possibility of distribution influenced by competition. In the study by Aguiar et al. (2018) carried out in Manaus city, Amazonas state, it was reported that the 12 studied specimens of *C. macropomum* were infected by *N. buttnerae* with a high concentration of parasites. However, in this case there was a clear preference on the part of *N. buttnerae* for the intermediate regions of the intestinal tube, where the highest densities were recorded. The preference *N. buttnerae* for intermediate portions of the intestine may related to nutritional requirements.

The relation between host and parasite can occur in a balanced way, however, when high infections occur, the direct competition between host and parasite for absorption of nutrients can generate a deficit in the growth of the host and cases of undernutrition in fish (SILVA et al., 2017; SOUZA et al., 2019). Data similar to this study were recorded by Jerônimo et al. (2017) in fish farms located in Rondônia and Amazonas states, where *C. macropomum* were highly parasitized by *N. Buttnerae*. Although the author did not record

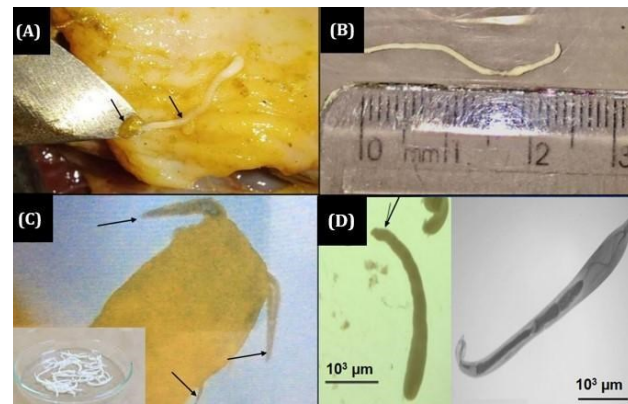


Figure 4. Indicator morphological features of *N. buttnerae* (Acanthocephala) found parasitizing *C. macropomum*. (A) Helminth with elongated body with cylindrical appearance (arrows). (B) Helminth measuring 2.5 cm. (C) Protractile proboscis covered with hooks (arrows). (D) Rear end pointed by arrows and morphological aspect when applying objective of 100x.

Table 1. Comparison of the prevalence (%), intensity, average intensity and average abundance of *N. buttnerae* (Acanthocephala) helminths in *C. macropomum* farmed in Theobroma municipality fish farm, Rondônia state, Brazil.

Parasites	Parasitological indices			
	Prevalence (%)	Intensity	Average intensity	Average abundance
<i>N. buttnerae</i> (Acanthocephala)	100.00	430.0	8.6	8.6

mortalities due to acanthocephalosis, damages that compromised the feed conversion of the fish were recorded. *C. macropomum* infected with *Acanthocephala* continue to feed, but were unable to gain weight because the parasites have an efficient nutrient withdrawal system from foods processed by their host (JERÔNIMO et al., 2017). Barreto et al. (2019) carried out a study in Cacaúlândia municipality, Rondônia state, among the 59 animals studied, all were parasitized by at least one specimen of *Acanthocephala N. buttnerae*. However, despite the high rate of contamination, no cases of malnutrition were observed in fish.

Knowing that the high infection by *N. buttnerae* causes morphological damage to intestine and can compromise quality of *C. macropomum* and consequently the production of fish farming in Brazilian Amazon region, the knowledge of the intermediate host of this parasite and the understanding of its life cycle represents important information to prevent and fight infections by this parasite. Lourenço et al. (2018) describes the life cycle of the parasite, where fish feces containing the parasite eggs are released into the environment and later ingested by Ostracoda (*Cypridopsis vidua*) intermediate host. The acanthor larva contained within the egg hatches in intestinal lumen of the intermediate host (HI), where it attaches itself and passes through successive ontogenic stages until it reaches the infective phase of the definitive host (HD), cystacanthus, which in turn continues its development inside the egg of the fish intestine. There is still no hypothesis formed regarding the primary source of infection by parasite, what is assumed is the transmission by wild fish, since there are properties that capture water from rivers where free-living tambaquis inhabit, or also, by the introduction of infected fish for breeding stock formation. Due to increasing rate of infection by *Acanthocephala*, some measures have been taken in fish farms in the North region, such as the rotation of species in cultivates of *C. macropomum* and *Brycon cephalus* (matrinxã), to break the cycle of the parasite, since *N. buttnerae* is considered species-specific (VALLADÃO et al., 2019).

In fish farms that do not present any type of contamination, contamination of the aquatic environment may occur from uptake of contaminated water, as the life cycle of *N. buttnerae* involves zooplankton components, such as crustaceans (Amphipod, Copepod, Isopod or Ostracoda), as intermediate hosts (PEREIRA et al., 2018). The tambaqui is infected by ingesting a crustacean containing cystacanth, the infective larval form of the parasite (NICKOL, 2006; SANTOS et al., 2013). In the Rondônia state, the parasitic fauna of *C. macropomum* reared in excavated ponds used for fattening and pay-fishing was studied by Godoi et al. (2012). The fish weighed an average 907g no *N. buttnerae* were found. The parasitic fauna was evaluated in *C. macropomum* raised in cages in the Amapá state and no species of intestinal parasites was found. The fish weighed 2 kg on

average (SANTOS et al., 2013). The absence of *N. buttnerae* in respective studies may be related to absence of intermediate host in the environment, without which, *N. buttnerae* cannot complete its life cycle.

Studies demonstrated reactions that compromise host tissue in *Acanthocephala* infections. Damage to intestine of *C. macropomum* due to high infection rates of *N. buttnerae* was reported by Matos et al. (2017), who carried out the study in Amazonas state, the authors reported presence of nodules, hypertrophy of goblet cells, thickening of the muscle layer, metaplasia in muscle tissue, severe edema of leukocyte infiltration in blood vessels and necrotic foci. Jerome et al. (2017) and Aguiar et al. (2018) reported histological changes such as structural changes in the villi, thickened submucosal layer with edema, and muscle layer shown metaplasia.

Fish inspection activities are fundamental for preservation of consumer health in cases of infestation, since this type of action has as its main mission to control future impacts on collective health that may be caused by the poor commercialization of these fish. In Brazil at the federal level, sanitary and industrial inspection of fish and fish products has been a statutory obligation of the Ministério da Agricultura, Pecuária e Abastecimento (MAPA) since year 1933, the most recent being Decree No. 9013, of March 29, 2017, updated Decree no. 10468, of August 18, 2020. This decree issued by the Departamento de Inspeção de Produtos de Origem Animal (DIPOA) and the Federal Inspection Service (SIF), which regulates the inspection of establishments and of products of animal origin that carry out trade, whether interstate or international. Inspection is essential so that all companies can carry out their activities within the law and in order to preserve the quality of the fish (CHAGAS et al., 2012). According to Decree No. 9.013, article 499 of RIISPOA, fish with a repugnant, mutilated, traumatized or deformed appearance, as well as with massive muscular infection by parasites, which may or may not harm the health of the consumer (BRASIL, 2017).

Faced with the previously mentioned aspects of parasitized or dead fish. According to RIISPOA/MAPA, dead fish and visibly sick fish must be removed from the tanks daily. This is necessary, as these animals, when they rot, contaminate other healthy fish. Then the dead fish must be discarded in composters, so that sanitary management is carried out. Therefore, it is not recommended to bury dead fish in areas close to the ponds. Because they can lead to soil contamination and groundwater, in addition to attracting birds and other animals.

It is important to inform measures to prevent *N. buttnerae* infestations. As it is known, parasites take advantage of the opportunity that fish are immunosuppressed, due to some environmental stress, caused by water pollution (leaching of pesticides from agriculture) or even by sudden fluctuations in

dissolved oxygen, pH, ammonia concentration, etc. (BARBOSA et al., 2022). Therefore, applications of good management practices (GMP) and continuous monitoring of water quality are necessary. It can exemplified, to avoid environmental stress, taking care with adequate levels of stocking density. When the density is increased, that is, it is planned to increase productivity, a production strategy must managed, such as installing artificial mechanical aerators, for vigorous oxygenation of the water (MACEDO; SIPAÚBA-TAVARES, 2010). Other examples are biosecurity practices, installing screens to prevent invasion by predatory birds (they can introduce parasites). Also, with newly acquired fingerlings, bathing in water with 2 to 3% salt (20 to 30g/liter = 20 to 30kg/1,000 liters) can applied for 2 to 20 minutes, depending on the fish species tolerance to treated. This vaccine will prevent the entry of parasites into the water of fish farming tanks (VALLADÃO et al., 2019).

CONCLUSION

C. macropomom cultivated in the Western Amazon region, especially in outbreaks reported in Theobroma municipality from Rondônia state, have been facing problems due to parasitism of *N. buttnerae* (Acanthocephala). The knowledge of the intermediate host of this parasite and understanding of its life cycle are important to prevent and fight infections. Therefore, it is suggested to carry out a study of zooplanktonic biodiversity and to correlate it with Acanthocephala outbreaks. In addition to histopathological studies of the lesions caused and the levels of infections, and thus, correlate them with hepatosomatic and splenosomatic indices.

ACKNOWLEDGMENTS

To the CAPES/Brasil through PROCAD Amazônia (UNIR/UFAC/USP) and also the CNPq/FAPERO for financial support and for granting a postdoctoral scholarships.

REFERENCES

- AGUIAR, L. S. et al. Distribution of the acanthocephalan *Neoechinorhynchus buttnerae* and semiquantitative analysis of histopathological damage in the intestine of tambaqui (*Colossoma macropomum*). **Pasasiltology Research**, v. 117, p. 1-10, 2018. <https://doi.org/10.1007/s00436-018-5840-8>.
- BAHAR, N. H. A. et al. Meeting the food security challenge for nine billion people in 2050: What impact on forests? **Global Environmental Change**, v. 62, 102056, 2020. <https://doi.org/10.1016/j.gloenvcha.2020.102056>.
- BARBOSA, E. F. et al. Pesticide residues detected in *Colossoma macropomum* by the modified QuEChERS and GC-MS/MS methods. **Acta Scientiarum. Technology**, (Manuscript accepted), 2023.
- BARRETO, J. C. et al. Identification of the endoparasitic fauna *Colossoma macropomum* (Cuvier, 1818) cultivated in Cacaúlândia – RO. **Brazilian Journal of Science of the Amazon**, v.8, n.4, p.1-7, 2019. <https://doi.org/10.47209/2317-5729v.8.n.4.p.1-7>.
- BELO, M. A. A. et al. Deleterious effects of low level of vitamin E and high stocking density on the hematology response of pacus, during chronic inflammatory reaction. **Aquaculture**, v.422-423, p.124-128, 2014. <http://dx.doi.org/10.1016/j.aquaculture.2013.12.013>.
- BRASIL. Ministério da Agricultura, Pecuária e Abastecimento - MAPA. Decreto Nº 9.013, de 29 de março de 2017. Brasília, **Diário Oficial da União** - Seção 1 de 30 de março de 2017a. Brasília: MAPA, 2017.
- BUSH, A. O. et al. Parasitology meets ecology on its own terms: Margolis et al. Revisited. **Journal of Parasitology**, v.83, p.575-583, 1997. <http://dx.doi.org/10.2307/3284227>.
- CAVALCANTE, P. H. O. et al. Orientattractis moravecii n. sp. and *Rondonia rondoni* Travassos, 1920 (Nematoda: Atractidae), parasites of *Pimelodus blochii* (Osteichthyes, Pimelodidae) from the Acre and Xapuri Rivers, Western Amazon, Brazil. **Parasitology**, v.144, p.226-236, 2017. <http://dx.doi.org/10.1017/S0031182016001736>.
- CAVALI, J. et al. Morphometric evaluations and yields from commercial cuts of black pacu *Colossoma macropomum* (Cuvier, 1818) in different body weights. **The Scientific World Journal**, 2021. <https://doi.org/10.1155/2021/3305286>.
- CHAGAS, E. C. et al. *Neoechinorhynchus buttnerae* parasitic infection in tambaqui (*Colossoma macropomum*) on fish farms in the state of Amazonas. **Boletim do Instituto de Pesca**, v.45, n.2, p.1-6, 2019. <https://doi.org/10.20950/1678-2305.201945.2.499>.
- CHAGAS, E. C. et al. Effect of sodium chloride on physiological responses and monogenean control in tambaqui (*Colossoma macropomum*). **Acta Amazonica**, v.42, n.3, p.439-444, 2012. <https://doi.org/10.1590/S0044-59672012000300017>.
- COSTA, C. M. S. et al. *In vitro* culture of *Neoechinorhynchus buttnerae* (Acanthocephala: Neoechinorhynchidae): Influence of temperature and culture media. **Brazilian Journal of Veterinary Parasitology**, v.27, n.4, p.562-569, 2018. <https://doi.org/10.1590/S1984-296120180079>.
- GODOI, M. I. M. et al. Parasitehost relationship between the tambaqui (*Colossoma macropomum* Cuvier 1818) and ectoparasites, collected from fish farms in the city of Rolim de Moura, State of Rondônia, Western Amazon, Brazil. **Acta Amazonica**, v.42, p.515-524, 2012. <https://doi.org/10.1590/S0044-59672012000400009>.
- GONÇALVES, M. et al. Embryonic development of eggs and stereological analysis of body of *Neoechinorhynchus buttnerae* (Golvan, 1956) (Eoacanthocephala: Neoechinorhynchidae). **Parasitology**, v.149, n.2, p.181-192, 2022. <https://doi.org/10.1017/S0031182021001712>.
- GRAY, A. J.; HAYUNGA, E. G. Evidence of alternative site selection by *Glaridacris laruei* (Cestoidea: Caryophyllidae) as a result of interspecific competition. **Journal of Parasitology – BMC Journal**, v.66, n.2, p.371-372, 1980. <https://doi.org/10.1645/17-58>
- IBGE. Instituto Brasileiro de Geografia e Estatística. **Produção da Pecuária Municipal**. Brasília: IBGE, 2020.
- JERÔNIMO, G. T. et al. *Neoechinorhynchus buttnerae* (Acanthocephala) infection in farmed *Colossoma macropomum*:

- A pathological approach. **Aquaculture**, v.469, p.124-127, 2017. <https://doi.org/10.1016/j.aquaculture.2016.11.027>.
- JERÔNIMO, G. T. et al. Fish parasites can reflect environmental quality in fish farms. **Reviews in Aquaculture**, 2022. <https://doi.org/10.1111/raq.12662>.
- LOURENÇO, F. S. et al. The development of *Neoechinorhynchus buttnerae* (Eoacanthocephala: Neoechinorhynchidae) in its intermediate host *Cypridopsis vidua* in Brazil. **Acta Parasitologica**, v.63, n.2, p.354-359, 2018. <https://doi.org/10.1515/ap-2018-0040>.
- LOURENÇO, F. S. et al. Ocorrência de *Neoechinorhynchus* (*Neoechinorhynchus*) *buttnerae* GOLVAN, 1956 (Acanthocephala: Neoechinorhynchidae) em *Colossoma macropomum* (Cuvier, 1818) (Characiformes: Serrasalminae) proveniente de uma piscicultura da Amazonia brasileira. **Folia Amazonica**, v.26, p.1-8, 2017. <https://doi.org/10.24841/fa.v26i1.414>.
- MACEDO, C. F.; SIPAÚBA-TAVARES, L. H. Eutrophication and water quality in fish farming: consequences and recommendations. **Boletim do Instituto de Pesca**, v.36, n.2, p.149-163, 2010.
- MALTA, J. C. O. et al. Infestações maciças por acantocéfalos, *Neoechinorhynchus buttnerae* Golvan, 1956, (Eoacanthocephala: Neoechinorhynchidae) em tambaquis jovens, *Colossoma macropomum* (Cuvier, 1818) cultivados na Amazônia Central. **Acta Amazonica**, v.31, n.1, p.133-143, 2001. <https://doi.org/10.1590/1809-43922001311143>
- MATOS, L. V. et al. Morphological and histochemical changes associated with massive infection by *Neoechinorhynchus buttnerae* (Acanthocephala: Neoechinorhynchidae) in the farmed freshwater fish *Colossoma macropomum* Cuvier, 1818 from the Amazon State, Brazil. **Parasitology Research**, v.116, n.3, p.1029-1037, 2017. <https://doi.org/10.1007/s00436-017-5384-3>.
- NICKOL, B. B. Phylum Acanthocephala. In: WOO, P.T.K. (Eds.). **Fish diseases and disorders**. v. 1: Protozoan and Metazoan Infections. Canadá: University of Guelph, p. 444-465, 2006.
- PEIXE BR. **Anuário Brasileiro da Piscicultura**, PEIXE BR 2021. Pinheiros, SP: PEIXE BR, 2022.
- PEIXE BR. **Anuário Brasileiro da Piscicultura**, PEIXE BR 2019. Pinheiros, SP: PEIXE BR, 2020.
- PEREIRA, J. N.; MOREY, G. A. M. First record of *Neoechinorhynchus buttnerae* (Eoacanthocephala, Neoechinorhynchidae) on *Colossoma macropomum* (Characidae) in a fish farm in Roraima, Brazil. **Acta Amazonica**, v.48, p.42-45, 2018. <https://doi.org/10.1590/1809-4392201702411>.
- PETENUCCI, M. E. et al. Fatty acid composition and nutritional profiles of *Brycon* spp. from central Amazonia by different methods of quantification. **Journal of Food Science and Technology**, v.56, p.1551-1558, 2019. <https://doi.org/10.1007/s13197-019-03654-4>.
- OLIVEIRA, M. L. B. et al. The digestive tube of *Piaractus brachipomus*: gross morphology, histology, histochemistry of the mucosal layer and the effects of parasitism by *Neoechinorhynchus* sp. **Journal of Fish Biology**, 2019. <https://doi.org/10.1111/jfb.13934>.
- ROCHA, M. J. et al. Changes in hematological and biochemical parameters of tambaqui (*Colossoma macropomum*) parasitized by metazoan species. **Brazilian Journal of Veterinary Parasitology**, v.27, p.488-494, 2018. <https://doi.org/10.1590/S1984-2961201800073>.
- SANTOS, E. F. et al. Parasitic fauna of tambaqui *Colossoma macropomum* (Characidae) farmed in cages in the State of Amapá, eastern Amazon. **Acta Amazonica**, v.43, n.1, p.105-111, 2013. <https://doi.org/10.1590/s0044-59672013000100013>.
- SILVA, G. A. L. et al. The impact of *Neoechinorhynchus buttnerae* (Golvan, 1956) (Eoacanthocephala: Neoechinorhynchidae) outbreaks on productive and economic performance of the tambaqui *Colossoma macropomum* (Cuvier, 1818), reared in ponds. **Latin American Journal of Aquatic Research**, v.45, p.496-500, 2017. <https://doi.org/10.3856/vol45-issue2-fulltext-25>.
- SOUZA, D. C. M. et al. Immune response of teleost fish to helminth parasite infection. **Brazilian Journal of Veterinary Parasitology**, v.28, p.533-547, 2019. <https://doi.org/10.1590/S1984-29612019080>.
- VALENTI, W. C. et al. Aquaculture in Brazil: past, present and future. **Aquaculture Reports**, v.19, p.100611, 2021. <https://doi.org/10.1016/j.aqrep.2021.100611>.
- VALLADÃO, G. M. R. et al. Challenges in the control of acanthocephalosis in aquaculture: special emphasis on *Neoechinorhynchus buttnerae*. **Reviews in Aquaculture**, 2019. <https://doi.org/10.1111/raq.12386>.