







Metacarpal fracture *in utero* in a bovine neonate

Fratura in utero de metacarpo em neonato bovino

Maria Damaris Ribeiro Cavalcante¹ , Giani Lourenço Augusto² , Salviano Tramontin Belettini³ ,
Carla Faria Orlandini de Andrade⁴ , Hugo Henrique Martin Campos⁵ , André Giarola Boscarato^{3*} 

ABSTRACT: Long bone fractures are common in juvenile cattle, however, cases of fractures occurring in the intrauterine environment during pregnancy are rare. The objective of this report is to present a case of an open consolidated fracture of the metacarpal that occurred *in utero*, in a newborn calf, in which the surgical approach used was successful. A 48-hour-old female bovine was treated at the Veterinary Hospital of Paranaense University, who presented a complete, open and poorly consolidated transverse diaphyseal fracture in uterus during the gestational period on clinical and radiographic examination. As a therapeutic approach, open reduction was chosen, with ostectomy followed by stabilization with type IA external skeletal fixator. Four 4mm transcortical pins were positioned proximally and distally to the newly formed fracture line, followed by two more pins in the proximal phalanges region, seeking to stabilize the metacarpophalangeal joint, since flexural deformity of that joint was observed after the realignment of the longitudinal axis of the metacarpal, even after the section of the superficial and deep digital flexor tendons and suspensory ligament. The ESF was removed after 32 days, when radiographic signs of neoproliferation and bone consolidation were observed. In a last evaluation 15 months after the surgical correction, a complete and satisfactory recovery was observed regarding the development and well-being of the animal.

KEYWORDS: Calf; Ostectomy; Osteosynthesis; Malformation.

RESUMO: Fraturas de ossos longos são comuns em bovinos jovens, entretanto, são raros os casos de fraturas que ocorrem no ambiente intrauterino durante a gestação. O objetivo deste relato é apresentar um caso de fratura exposta consolidada do metacarpo ocorrida *in utero*, em um bezerro recém-nascido, no qual a abordagem cirúrgica utilizada foi bem-sucedida. Foi atendida no Hospital Veterinário da Universidade Paranaense uma fêmea bovina, com 48 horas de idade, que apresentou ao exame clínico e radiográfico uma fratura diafisária transversa completa, exposta e mal consolidada ocorrida no útero durante o período gestacional. Como abordagem terapêutica optou-se pela redução aberta, com ostectomia seguida de estabilização com fixador esquelético externo tipo IA. Quatro pinos transcorticais de 4mm foram posicionados proximal e distalmente a linha de fratura recém-formada, seguidos de mais dois pinos na região das falanges proximais, buscando estabilizar a articulação metacarpofalângica, uma vez que foi observada deformidade flexural dessa articulação após o realinhamento do eixo longitudinal do metacarpo, mesmo após a secção dos tendões flexores digitais superficiais e profundos e do ligamento suspensor. O FSE foi retirado após 32 dias, quando foram observados sinais radiográficos de neoproliferação e consolidação óssea. Em última avaliação 15 meses após a correção cirúrgica, foi observada recuperação completa e satisfatória quanto ao desenvolvimento e bem-estar do animal.

PALAVRAS-CHAVE: Bezerro; Ostectomia; Osteossíntese; Mal formação.

INTRODUCTION

Traumatic fractures are relatively frequent in newborn and juvenile cattle. These usually occur during handling with adult animals, trampling by the mother (Mulon, 2013), or even during delivery, caused by the application of excessive traction or the use of inappropriate methods to extract the calf (Pentecost;

Niehaus; Anderson, 2016; Akin, 2017). There are few descriptions of cases of fractures that occurred in the intrauterine environment not related to the moment of delivery, and for the bovine species, there are no reports described so far. In large animals, only two cases of fracture *in utero* are currently described in the literature, both in the equine species. One such case was

¹ Aprimoramento Profissional em Medicina Veterinária, Universidade Paranaense

² Médico Veterinário, Hospital Veterinário, Universidade Paranaense

³ Programa de Pós-Graduação em Ciência Animal com Ênfase em Bioativos, Universidade Paranaense (UNIPAR)

⁴ Instituto Federal de Goiás, campus Urutaí, GO, Brazil.

⁵ Mestrando, Programa de Pós-Graduação em Ciência Animal com Ênfase em Bioativos, Universidade Paranaense (UNIPAR)

*Corresponding author: andreboscarato@prof.unipar.br

Received: 09/18/2022. Accepted: 08/21/2023

observed in a fetus after miscarriage (Murdaugh, *et al.* 1985) and, more recently, another case was described as a cause of dystocia of fetal origin (Lecton, 2021). Even in humans, intra-uterine bone fractures are rare and are associated with prenatal neuromuscular diseases, osteopetrosis or osteogenesis imperfecta (Skryabin; Askelrov, 2018). The objective of this report is to present a case of bone malunion in a poorly consolidated open fracture of the metacarpal that occurred *in utero*, in a Holstein heifer, which was successfully treated by ostectomy and application of type IA external skeletal fixator.

CASE REPORT

A female bovine, 48 hours old, was treated at the Veterinary Hospital of Paranaense University, referred for treatment of a fracture in the left thoracic limb. The owner reported that during birth, there was a need for help, characterizing dystocia of fetal origin and, immediately after birth, a change compatible with fracture in the left thoracic limb was noticed.

Clinical examination revealed evident functional impotence of the limb, with a lateral deviation of approximately 90° in the middle third of the metacarpal (Fig. 1A), and the presence of an open lesion covered by granulation tissue at the probable focus of the fracture (Fig. 1B).

Radiographic examination showed bone consolidation and narrowing of the medullary canal at the proximal and distal ends of the fracture (Fig. 1C). Based on these findings, the diagnosis of complete, open and poorly consolidated transverse diaphyseal fracture was established, and it was concluded that it was a consolidated fracture that occurred *in utero* during the gestational period.

As a therapeutic approach, open reduction was chosen, with ostectomy followed by stabilization with type IA external skeletal fixator (ESF). The calf was fasted for 4 hours and then submitted to general anesthesia induction, with pre-anesthetic medication consisting of a combination of diazepam 0.1mg/kg (Compaz, Cristália, Brazil) and ketamine 1mg/kg (Ketamin, Cristália, Brazil) intravenously. After positioning in the right

lateral decubitus position and orotracheal intubation, the anesthetic plane was maintained with isoflurane (Isoforine, Cristália, Brazil) vaporized in oxygen. Brachial plexus block was performed with 2% lidocaine (7mg/kg) without vasoconstrictor (Bloc, J.A Saúde Animal, Brazil). As an analgesic adjuvant in the intraoperative period, tramadol hydrochloride 1mg/kg (Tramadol, Cristália, Brazil) was used intramuscularly. After standard preoperative asepsis, the surgical approach consisted of a linear incision through the skin and subcutaneous tissue, starting on the dorsal surface of the proximal portion of the metacarpal and extending distally to the limb, in order to expose the site of the lesion bone consolidation (Fig. 2A). After blunt division of the adjacent tissues, ostectomy was performed using a chisel and hand saw, allowing the longitudinal realignment of the metacarpal (Fig 2B). Then, four 4mm transcortical pins were positioned in the proximal and distal regions of the newly formed fracture line, which were fixed with self-curing acrylic resin. After bone stabilization, flexural deformity of the metacarpophalangeal joint was observed due to shortening of the tendon units. Thus, we opted for tenotomy of the superficial and deep digital flexor tendons and placement of two more transcortical pins in the proximal phalanges to stabilize the referred joint (Figs 2C and D).

In the postoperative period, the limb was kept with an occlusive bandage, to protect the surgical wound and the insertion points of the transcortical pins, and the dressings were periodically performed every 24 hours, using gauze and topical PVPI. As an initial complication, a shortening of the limb by approximately 3 cm was observed. In this way, aiming at better support to the ground and ambulation, a wooden club was fixed on the plantar surface of the digits with acrylic resin, and an aluminum splint was associated with the occlusive bandage on the cranial surface of the limb. Both were maintained for a period of 35 days (Fig. 3A). Drug therapy consisted of cephalothin 55mg/kg, IV (Keflin Antibióticos do Brasil, Brazil) for 14 days, flunixin meglumine 1.1mg/kg, IV (Flumax, J. A Saúde Animal, Brazil) for five days and tramadol hydrochloride (1mg/kg) every 24 hours, in the first 48 hours. After seven days of stopping the antimicrobial,

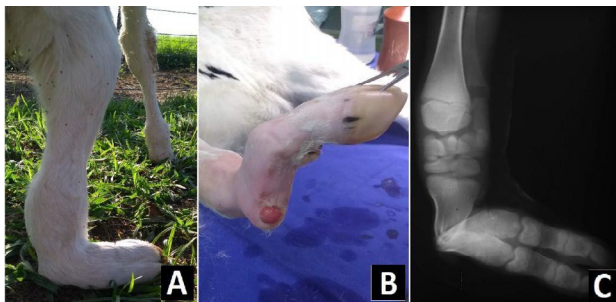


Figura 1. Bovino, fêmea, 48 horas após o nascimento, membro torácico esquerdo apresentando impotência funcional com acentuado desvio lateral em seu eixo axial (A). Tecido de granulação na extremidade proximal do metacarpo, evidenciando fratura aberta (B). Imagem radiográfica evidenciando fratura mal consolidada com desvio axial do metacarpo no membro torácico esquerdo (C).

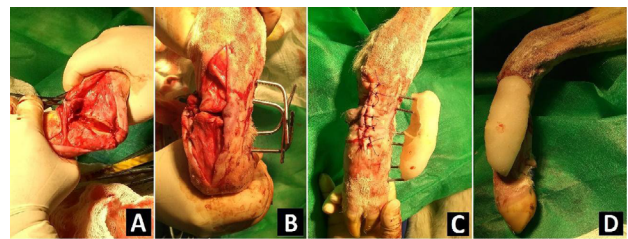


Figura 2. Abordagem cirúrgica com exposição da consolidação óssea no foco de fratura congênita mal consolidada com desvio lateral do eixo longitudinal do metacarpo (A). Realinhamento das extremidades diafisárias proximal e distal após ostectomia e posicionamento de implantes transcorticais de 4mm (B). Aspecto dorsal (C) e lateral (D) do membro após estabilização com fixador esquelético externo tipo IA.

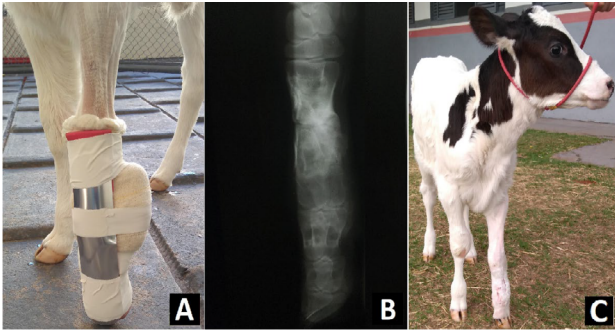


Figura 3. External coaptation with bandages and aluminium splint, with notable pinch support, compensating for the shortening of the limb (A). Radiographic image after removal of the transcortical implants showing bone consolidation on the 32nd postoperative day (B). Heifer in quadrupedal station showing satisfactory ambulation, 39 days after the surgical procedure (C).

purulent secretion was observed in the surgical wound, and a new antimicrobial therapy was instituted with the association of gentamicin 3.3mg/kg and potassium benzylpenicillin 24.0000UI/kg (Gentopen, J. A Saúde Animal, Brazil) every 12 hours for seven days, observing resolution of the infection. The animal was kept in a stall with restricted movement during the postoperative period, with controlled walks twice a day, after the 5th day of surgery. The ESF was removed after 32 days, after radiographic signs of neoproliferation and bone consolidation (Fig. 3B). The use of a splint next to the occlusive bandage was maintained for another seven days, with the aim of providing some support for the limb and rehabilitating ambulation, which was satisfactory (Fig. 3C), with definitive medical discharge after this period.

DISCUSSIONS

In the bovine species, endochondral ossification occurs between 10 and 11 weeks, from the deposit of calcium and phosphorus, which in this phase, intensifies in the diaphyseal region of the long bones (Trujillo *et al.*, 2011). Thus, the presence of bone consolidation and a break in the skin, with granulation tissue adjacent to the probable focus of the fracture, suggest, in the present case, its occurrence at some point after endochondral ossification, but with sufficient time for tissue repair, in the period comprising the final two thirds of pregnancy. This evidence allowed classifying the alteration as a congenital fracture that occurred *in utero* during the gestational period.

As a possible differential diagnosis, osteogenesis imperfecta is cited. Zhang *et al.* (2020) describe a case of a Holstein calf with osteopenia of oligogenic origin. However, the bilateral fractures observed in the tibia were comminuted, and occurred spontaneously on the fourth and seventh day after birth. In humans, congenital long bone fractures have also been associated with osteogenesis imperfecta (Chamunyonga; Masendeke; Matekeve, 2019) and other autosomal recessive diseases such as congenital myopathy (Knierim *et al.*, 2016; Böhm *et al.*, 2018).

Congenital fractures of long bones are uncommon in domestic species. Retrospective studies showing congenital limb defects in calves have not reported this change (Yardimci; Ozak; Nisbet, 2011; Mosbah *et al.*, 2012; Schleining; Bergh, 2014) and fractures identified in the perinatal period in cattle are usually related to trauma and inadequate obstetric maneuvers (Arican *et al.*, 2014; Akin, 2017). However, two cases have been described in the equine species. One of these was observed in a 7-month fetus, after a miscarriage, who presented bone malunion in a consolidated tibial fracture (Murdaugh *et al.*, 1985). More recently, in a report very similar to the present study, Lecton *et al.* (2021) described a chronic fracture of traumatic origin, with incomplete consolidation and misalignment, causing dystocia of fetal origin. Despite the uncertain etiology and due to the lack of evidence regarding other causal agents, as in the previously cited reports, it is proposed that an abdominal trauma in the pregnant female may have affected the appendicular skeleton of the fetus, causing the fracture.

According to Pentecost, Niehaus and Anderson (2016) the metacarpal and metatarsal bones represent the most commonly fractured bones in cattle. The lack of protection by adjacent tissues in this area culminates in extreme vulnerability of bones to external trauma (Ferguson, 1982). Thus, several techniques are described and used in the stabilization of long bone fractures in calves, including the use of external coaptation (Orlandini *et al.*, 2015), locked compression plates (Schleining; Bergh, 2014; Lindt *et al.*, 2021) and variations of external skeletal fixators (Gülaydin; Sarierler, 2018; Rawat *et al.*, 2020).

Because it was a fracture that was consolidated in a situation of poor union with lateral deviation of the longitudinal axis of the limb, open reduction was necessary for osteotomy followed by osteosynthesis with type IA ESF. The technique has been used for most long bones of domestic animals, as it is effective in canceling torsional, shear and lever forces at the fracture line (Anderson; St Jean, 1996). Furthermore, it is considered the most suitable method for the fixation of open fractures, corrective osteotomies and temporary joint immobilization, as in the present case, since the implants remain distant from the fracture line, covering non-inflamed or potentially infected tissues (Bakici; Karsli; Cebeci, 2019). As the animal in the present study was a neonate, the ESF type I was considered adequate, since, in addition to the effective possibility of fracture resolution, it presents good ergonomics and less interference in the animal's ambulation, considering its size/weight, in addition to lower cost when compared to ESF type II. As described by Vogel and Anderson (2014), despite the limited density of cortical bone, this technique has been used successfully in neonates. The weight bearing results in axial load on the transfixation pins, perpendicular to their construction, resulting in a support system for the limb that does not promote displacement or pullout of the transcortical implants.

Flexural deformities of congenital origin are often identified in bovine neonates, and are, in most cases, bilateral (Gençcelep; Karasu; Kayıkçı, 2019). However, in the present report, moderate flexural deformity was observed only in the intraoperative period, after bone realignment of the affected limb. Thus, it is suggested that the displacement of structures due to metacarpal fracture associated with rapid intrauterine fetal development may have contributed to the shortening of the flexor structures. The treatment used consisted of transection of the superficial and deep digital flexor tendons and suspensory ligament, according to the approach described by Sato, Kato and Tajima (2020), and in agreement with the authors, no complications such as limb hyperextension were observed.

Postoperative management was performed similarly to that conducted by Tushar Rawat *et al.* (2020). However, the use of an aluminum splint, together with bandages, was recommended, in order to preserve stability and provide adequate extension of the interphalangeal joints. According to Pentecost, Niehaus and Anderson (2016), this approach is indicated to improve the stability and longevity of internal and external fixation constructions after surgical treatment of long bone fractures. The degree of bone repair determined the period of permanence of transcortical implants, which was considered normal, according to the classification by Aithal *et al.* (2004), as it remained within the 60-day interval, with no complications or deformations related to the implants.

Congenital anomalies are relatively frequently found in calves, occurring both in the axial skeleton (Boscarato *et al.*,

2021; Toma *et al.*, 2021) and in the appendicular skeleton (Yardimci; Ozak; Nisbet, 2011; Singh *et al.*, 2020). Most of them are hereditary (Leipold; Hiraga; Dennis, 1993; Yardimci; Ozak; Nisbet, 2011; Schons *et al.*, 2020), many of them are considered unfavorable regarding the prognosis of surgical treatment in the short or long term, while others have a favorable prognosis, according to the degree and characteristics of the malformation (Mosbah *et al.*, 2012). In a last evaluation 15 months after the surgical correction, a complete and satisfactory recovery was observed regarding the development and well-being of the animal. There was a change in the morphological structure of the horny case of the digits, with greater growth and elevation of the heels, a fact that contributed to the reduction of dysmetria between the limbs.

CONCLUSIONS

Congenital alterations in cattle, in general, are considered unfavorable in terms of prognosis. However, under the conditions of this study, it can be concluded that open reduction with ostectomy associated with a type 1A external skeletal fixator was an effective approach for the treatment of congenital consolidated metacarpal fracture. Despite the low incidence, it is expected that this report can provide a scientific technical basis and enable therapeutic approaches for similar cases.

ACKNOWLEDGEMENTS

The authors thank Universidade Paranaense for the infrastructure and academic support, and the collaboration of the J.A Saúde Animal laboratory.

REFERENCES

- AITHAL, H. P. *et al.* The use of a circular external skeletal fixation device for the management of long bone osteotomies in large ruminants: an experimental study. **Journal of Veterinary Medicine Series A**, v. 51, n. 6, p. 284-293, 2004.
- AKIN, I. Calf metacarpal fractures in association with bovine dystocia: Case series among calves. **Ataturk Universitesi Veteriner Bilimleri Dergisi**, v. 12, n. 3, p. 235-241, 2017.
- ANDERSON, D.E.; ST JEAN, G. External skeletal fixation in ruminants. **Veterinary Clinics of North America: Food Animal Practice**, v. 12, n. 1, p. 117-152, 1996.
- ARICAN, M. *et al.* A retrospective study of fractures in neonatal calves: 181 cases (2002-2012). **Pakistan Veterinary Journal**, v. 34, n. 2, p. 247-250, 2014.
- BAKICI, M.; KARSLI, B.; CEBECI, M. T. External skeletal fixation. **International Journal of Veterinary and Animal Research**, v. 2, n. 3, p. 69-73, 2019.
- BÖHM, J. *et al.* Novel ASCC1 mutations causing prenatal-onset muscle weakness with arthrogyriposis and congenital bone fractures. **Journal of medical genetics**, v. 56, n. 9, p. 617-621, 2018.
- BOSCARATO, A. G. *et al.* Abordagem cirúrgica em bezerros com onfalite. **Acta Scientiae Veterinariae**, v. 49, p. 1833, 2021.
- CHAMUNYONGA, F.; MASENDEKE, K. L.; MATEVEKE, B. Osteogenesis imperfecta and pregnancy: a case report. **Journal of Medical Case Reports**, v. 13, n. 1, p. 1-4, 2019.
- FERGUSON, J. G. Management and repair of bovine fractures. **The Compendium on continuing education for the practicing veterinarian**, v. 4, p. 128-135, 1982.
- GENÇCELEP, M.; KARASU, A.; KAYIKCI, C. Degree of deformity and certain hormone, vitamin and trace element levels in the serum of calves with congenital flexural deformity. **Medycyna Weterynaryjna**, v. 75, n. 06, p. 360-364, 2019.
- GÜLAYDIN, A.; SARIERLER, M. Treatment of Long Bone Fractures in Calves with Ilizarov External Fixator. **Veterinary and Comparative Orthopaedics and Traumatology**, v. 31, n. 05, p. 364-372, 2018.

- KNIERIM, E. *et al.* Mutations in subunits of the activating signal cointegrator 1 complex are associated with prenatal spinal muscular atrophy and congenital bone fractures. **The American Journal of Human Genetic**, v. 98, n. 3, p. 473-489, 2016.
- LECTION, J. *et al.* Malunion of an In Utero Metacarpal Fracture in a Standardbred Mare Presenting for Dystocia. **Journal of Equine Veterinary Science**, v. 96, p. 103321, 2021.
- LEIPOLD, H. W.; HIRAGA, T.; DENNIS, S. M. Congenital defects of the bovine musculoskeletal system and joints. **Veterinary Clinics of North America: Food Animal Practice**, v. 9, n. 1, p. 93-104, 1993.
- LINDT, B. *et al.* Closing wedge osteotomy and medial distal tibia plate application for treatment of severe bilateral angular limb deformities in the hindlimbs of an 8-month-old foal. **Equine Veterinary Education**, v. 34, n. 6, p. 218-227, 2021.
- MOSBAH, E. *et al.* Congenital limb deformities in some farm animals. In: **Proceedings of the 5th Animal Wealth Research Conference in the Middle East and North Africa**, p. 23-38, 2012.
- MURDAUGH, D. *et al.* Malunion of an in utero open tibial fracture in an aborted equine fetus. **Journal of Equine Veterinary Science**, v. 5, n. 4, p. 189-191, 1985.
- MULON, P. Y. Management of long bone fractures in cattle. **In Practice**, v. 35, n. 5, p. 265-271, 2013.
- ORLANDINI, C. F. *et al.* Imobilização com muleta de Thomas modificada e gesso sintético para reparação de fraturas de ossos longos em grandes animais. **Acta Scientiae Veterinariae**, v. 43, p. 1-7, 2015.
- PENTECOST, R.; NIEHAUS, A. J.; ANDERSON, D. E. Surgical management of fractures and tendons. **Veterinary Clinics: Food Animal Practice**, v. 32, n. 3, p. 797-811, 2016.
- RAWAT, T. *et al.* Management of compound long bone fractures by free form external skeletal fixation using epoxy putty in bovine calves: a review of 20 cases. **Ruminant Science**, v. 9, n. 1, p. 159-167, 2020.
- SATO, A.; KATO, T.; TAJIMA, M. Flexor tendon transection and post-surgical external fixation in calves affected by severe metacarpophalangeal flexural deformity. **Journal of Veterinary Medical Science**, v. 82, n. 10, p. 1480-1483, 2020.
- SCHLEINING, J. A.; BERGH, M. S. Surgical correction of angular and torsional metatarsal deformity with cylindrical osteotomy and locking compression plates in a calf. **Veterinary Surgery**, v. 43, n. 5, p. 563-568, 2014.
- SCHONS, L. C. *et al.* Reconstrução cirúrgica da tibia em fratura mal consolidada em um cão. **Ciência Animal**, v. 30, n. 3, p. 146-154, 2020.
- SKRYABIN, E. G.; ASKELROV, M. A. Fractures of long tubular bones in newborns: mechanisms of injuries, methods of diagnosis, and treatment. **Pediatric Traumatology, Orthopaedics and Reconstructive Surgery**, v. 6, n. 4, p. 70-76, 2018.
- SINGH, G. *et al.* Monstrosities as a cause of dystocia-a study of 13 cases. **Veterinary Practitioner**, v. 21, n. 1, p. 103-106, 2020.
- TOMA, H. S. *et al.* First occurrence of Arnold Chiari type II malformation and associated abnormalities in a Gir calf produced in vitro from Brazil-case report. **Arquivo Brasileiro de Medicina Veterinária e Zootecnia**, v. 73, n. 04, p. 916-922, 2021.
- TRUJILLO, H. A. G. *et al.* Ossificação endocondral em embriões e fetos de bovinos. **Arquivo Brasileiro de Medicina Veterinária e Zootecnia**, v. 63, n. 4, p. 799-804, 2021.
- VOGEL, S. R.; ANDERSON, D. E. skeletal fixation of fractures in cattle. **Veterinary Clinics: Food Animal Practice**, v. 30, n. 1, p. 127-142, 2014.
- YARDIMCI, C.; OZAK, A.; NISBET, H.O. Treatment of unilateral congenital flexural and torsional limb deformities with circular external skeletal fixation system in two calves. **Veterinary and Comparative Orthopaedics and Traumatology**, v. 24, n. 02, p. 151-156, 2011.
- ZHANG, X. *et al.* Osteogenesis imperfecta in a male holstein calf associated with a possible oligogenic origin. **Veterinary Quarterly**, v. 40, n. 1, p. 58-67, 2020.