

## POST-MORTEM LESIONS OF UROLITHIASIS IN A LESSER SEED FINCH (*Sporophila angolensis*)

[Lesão post-mortem de urolitíase em um Curió (*Sporophila angolensis*)]

Guilherme Augusto Marietto-Gonçalves<sup>1\*</sup>, Breno Sousa Salgado<sup>2,3</sup>

<sup>1</sup> Médico Veterinário e Biólogo, Mestre; Laboratório de Ornitopatologia, Departamento de Clínica Veterinária, Faculdade de Medicina Veterinária e Zootecnia, Universidade Estadual Paulista – FMVZ-UNESP, Botucatu, SP, Brasil

<sup>2</sup> Médico Veterinário, Mestre; Laboratório de Patologia Comparada e Investigativa, Departamento de Clínica Veterinária, Faculdade de Medicina Veterinária e Zootecnia, Universidade Estadual Paulista (FMVZ-UNESP), Botucatu, SP, Brasil; <sup>3</sup> Fundação de Ensino e Pesquisa de Itajubá (FEPI), Itajubá, MG, Brazil.

**RESUMO** - A Urolitíase é uma doença que, apesar de ser um problema comumente observado na prática veterinária, é incomum em aves. Até o presente momento, tal doença não foi ainda relatada em Passeriformes. Assim, o objetivo do presente artigo é descrever um caso de urolitíase em uma fêmea adulta de curió (*Sporophila angolensis*) criada como pássaro de estimação, a qual apresentava distensão abdominal, estresse respiratório, e apatia, anteriormente a morte. A ave apresentava histórico de ser alimentado com uma dieta rica em proteína. Após sua morte, foi conduzida a necropsia no sentido de se determinar a causa da mesma. Neste procedimento, observou-se macroscopicamente acentuada ascite, hidropericárdio, e cálculos ureterais no ureter esquerdo. Testes adicionais relativos a avaliação microbiológica bacteriana e viral, bem como a composição do cálculo, não puderam ser realizados devido ao fato de que o proprietário não consentiu tais procedimentos em virtude dos custos envolvidos. Haja vista que a ave era alimentada com uma dieta rica em proteína, uma relação entre os ureterólitos e o desequilíbrio na dieta foi sugestivo para a participação das proteínas no desenvolvimento do cálculo. Adicionalmente, conclui-se que a presença do cálculo no ureter resultou em bloqueio do fluxo urinário, ascite, e conseqüente falha respiratória aguda, devido ao preenchimento dos sacos aéreos com líquidos.

**Palavras-Chave:** *Sporophila angolensis*, Curió, Urolitíase, Patologia aviária.

**ABSTRACT** - Urolithiasis is a disease that despite being a commonly observed problem in veterinary practice is uncommon in birds. Such disease was not reported in passeriforms to date. Accordingly, the aim of the present article is to describe a case of urolithiasis in an adult female lesser seed finch (*Sporophila angolensis*) pet bird which presented abdominal distension, respiratory distress, and apathy prior to death. The bird had history of being fed with a diet rich in protein. After the bird death, a necropsy was conducted in order to determine the cause of death. At necropsy, accentuated ascites, hydropericardium, and ureteral stones in the left ureter could be grossly observed. Additional tests related with viral and bacterial microbiological testing and with the determination of calculi composition could not be performed since the owner did not consent with the procedures because of the cost. Since the bird was fed on a high protein diet, a relationship between the ureteroliths and dietary imbalance was suggested with participation of protein in calculi development by providing the organic nuclei. Additionally, we conclude that the presence of calculi in the ureter resulted in urinary flow blockage, ascites, and consequent acute respiratory failure due to filling of air sacs with liquid.

**Keywords:** *Sporophila angolensis*, lesser seed finch, urolithiasis, avian pathology.

\* Autor para correspondência: gmarietto\_ornito@fmvz.unesp.br

## INTRODUÇÃO

Urolithiasis is a common veterinary health concern in which dogs, cats, pigs and cattle are the most affected species (Robinson *et al.*, 2008). Other mammals have also been reported to develop urolithiasis, including horses (Saam, 2001; Macbeth, 2008), sheep (Riet-Correa *et al.*, 2009), cattle (Ozmen, 2005), goats (Halland *et al.*, 2002), whales (Harms *et al.*, 2004), deer (Hattel *et al.*, 2004), and ferrets (Del Angel-Caraza *et al.*, 2008).

Although urolithiasis is more commonly observed in mammals, nonmammals can also develop urinary stones since uroliths have been observed in avian species (Dennis & Bennet, 2000), tortoises (Homer *et al.*, 1998) and mollusks (Robinson *et al.*, 2008).

Despite being reported in avian species, urolithiasis is an uncommon disease in such animals and has only been documented in psittaciforms (Dennis & Bennet, 2000) and galliforms (Blaxland *et al.*, 1980; Cowen *et al.*, 1987); as far as we know, there are no reported cases of this disease in passeriforms. According to that, herein we report a case of urolithiasis in a Lesser seed finch [*Sporophila angolensis* (ex *Oryzoborus angolensis*)] (Sigrist, 2009).

## CASE REPORT

An adult female lesser seed finch pet bird, estimated to be 2-years-old, was presented for post-mortem examination immediately after its death with a history of abdominal distension, respiratory distress, and apathy. The bird was fed with a commercial seed mix, along calcium carbonate, polivitaminic, yellow mealworms, and a homemade boiled egg, powder milk, corn flakes, and cereal mix. No treatment prior to death was provided to the bird and it was maintained under refrigeration after death until the necropsy procedure. At necropsy, generalized congestion, ascites, hydropericardium, cardiomegaly with right ventricle distension, pulmonary edema, hepatomegaly, nephromegaly, and unilateral ureteral calculi were grossly observed in the left ureter. The ureteroliths varied in size from 0.1 mm to 0.2 mm in diameter and presented almost exclusively a round shape (Figure 1); additionally, they had a rough whitish exterior surface and a white porous interior material, and there was a tendency for the ureteroliths to crumble

Because of the coelomic and pericardial effusions, pulmonary edema, ureterolithiasis, and no evidence of liver disease, the cause of death was concluded to be acute respiratory failure due to fluid filling of air sacs caused by the circulatory disturbances that resulted from the urinary blockage. Unfortunately, histopathologic examination and testing for infectious agents could not be performed since the owner did not allow the realization of those procedures because of cost.

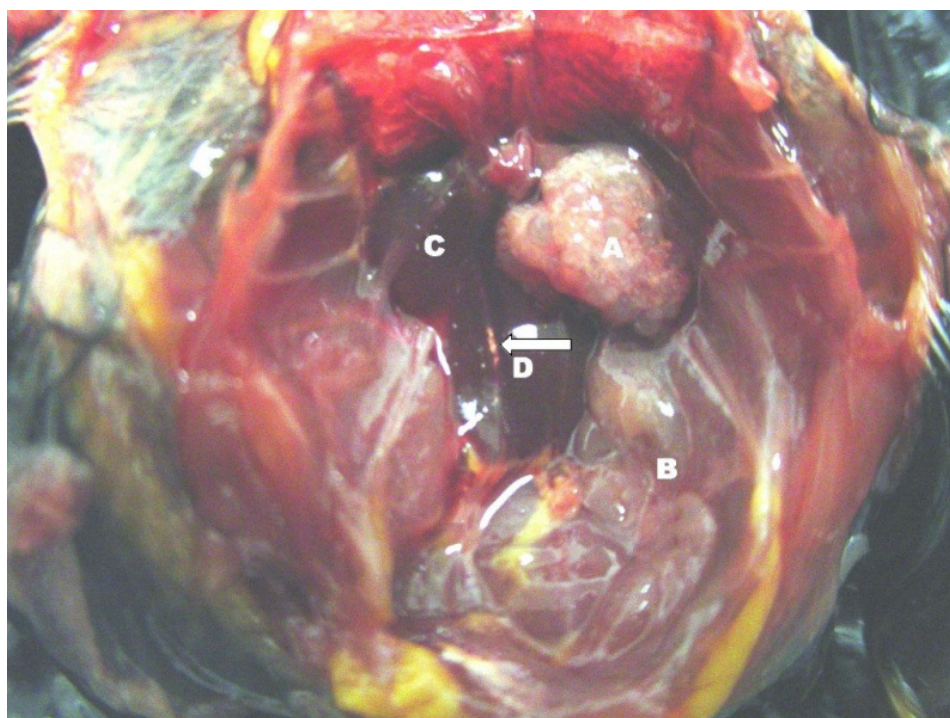


Figura 1 – Ventral view of the coelomic cavity in the abdominal region during necropsy. A - Ovary; B - Oviduct; C - Right kidney; D – Uroliths in the left ureter (white arrow) blocking urinary flow.

## DISCUSSÃO

Urolithiasis is simply the presence of urinary tract calculi, and can be classified according to its anatomic location as nephrolithiasis, ureterolithiasis and urethrolithiasis. Although this disease can be considered an important cause of renal failure in pullets and caged laying hens, reports of urinary calculi in companion birds have been uncommon (Pollock, 2006); this feature makes documentation of morbidity and mortality cases associated to urolithiasis in these animals an extremely important task as a part of data base for managing them and to better understand the pathophysiology of the disease in different avian species. The birds which develop urinary stones often appear normal until ureteral flow is blocked, leading to lethargy, straining, and death (Mallinson *et al.*, 1983; Niznik *et al.*, 1985; Lierz, 2003).

In the present case, generalized congestion, ascites, hydropericardium, cardiomegaly with right ventricle distension and pulmonary edema were observed in association with urinary blockage by ureteroliths; these alterations indicate that a circulatory disturbance occurred in a retrograde manner because of the increase in hydrostatic pressure caused by the blockage of urinary flow. Additionally, nephromegaly was observed, probably because that uroliths presence led to compensatory hypertrophy of remaining renal tissue (Pollock, 2006). Since birds cannot breathe adequately in presence of ascites – because air sacs are filled with fluids and the air flow cannot be correctly traversed – we concluded that the cause of death of the animal was acute respiratory failure due to air sacs fluid filling caused by circulatory disturbances that resulted from the urinary blockage.

Urinary calculi formation involves a complex sequence of events, including the state of urinary saturation of calculogenic materials, the presence of urinary inhibitors of crystallization, and various urinary promoters of crystal aggregation and growth (Robinson *et al.*, 2008). In avian species, urolith formation has been associated with severe dehydration (Julian, 1982), excess dietary calcium, dietary electrolyte imbalances (Wideman *et al.*,

1985), high protein intake (Pollock, 2006), cryptosporidiosis (Sréter & Vargas, 2000), polyomavirus infection (Johné & Müller, 2007), infectious bronchitis virus (Blaxland *et al.*, 1980; Cowen *et al.*, 1987; Cavanagh, 2007), *Mycoplasma synoviae* infection, mycotoxicosis, or shipping stress (Pollock, 2006). In the present case we suggest that dietary imbalance contributed to calculi formation since the bird was fed on a high protein diet; this high protein intake could have supplied the organic nuclei for the formation of urinary calculi, followed by mineral deposition; unfortunately, the accurate determination of the urinary calculi chemical composition could not be performed since the owner did not allow us to perform any additional tests related to his bird due to the cost.

Additionally, although the hepatomegaly and splenomegaly were likely associated with congestive heart failure in the present case, other causes of these lesions must be included in the differential diagnosis such as polyomavirus (Johné & Müller, 2007) and *Cryptosporidium* (Sréter & Vargas, 2000) infections. Such infectious agents can also be involved in uroliths formation; consequently, the differentiation between infections and dietary imbalance must be performed. Histopathologic examination and testing for infectious agents could not be performed since the owner did not allow the realization of those procedures; however, the history of the animal was indicative of dietary imbalance, leading us to consider the association of urolith formation and high protein intake in the present case.

This is the first report of post-mortem identification of urolithiasis in passerines and, particularly, in lesser seed finches. We conclude that, in this case, the bird died from acute respiratory failure associated with ascites due to urinary blockage by calculi.

## REFERÊNCIAS

- Blaxland J.D., Borland E.D., Siller W.G. & Martindale L. 1980. An investigation of urolithiasis in two flocks of laying fowls. *Avian Pathology*. 9:5-19.
- Cavanagh D. 2007. Coronavirus in poultry and other birds (Review). *Avian Pathology*. 34:439-448.
- Cowen B.S., Wideman R.F. & Rothenbacher H. 1987. An outbreak of avian urolithiasis on a large commercial egg farm. *Avian Diseases*. 31:392-397.
- Del Angel-Caraza J., Chávez-Moreno O., García-Navarro S. & Pérez-García C. 2008. Mixed urolith (struvite and calcium

oxalate) in a Ferret (*Mustela putorius furo*). *Journal of Veterinary Diagnostic Investigation*. 20:682-683.

Dennis P.M. & Benett R.A. 2000. Ureterotomy for removal of two ureteroliths in a parrot. *Journal of American Veterinary Medical Association*. 217:865-868.

Halland S.K., House J.K. & George L.W. 2002. Urethroscopy and laser lithotripsy for the diagnosis and treatment of obstructive urolithiasis in goats and pot-bellied pigs. *Journal of American Veterinary Medical Association*. 220:1831-1834.

Harms C.A., Piccolo R.L., Rotstein D.S. & Hohn A.A. 2004. Struvite penile urethrolithiasis in a Pigmy sperm whale (*Kogia breviceps*). *Journal of Wildlife Disease*. 40:588-593.

Hattel A.L., Shaw D.P., Love B.C., Wagner D.C., Drake T.R. & Brooks J.W. 2004. A retrospective study of mortality in Pennsylvania captive White-tailed deer (*Odocoileus virginianus*): 2000-2003. *Journal of Veterinary Diagnostic Investigation*. 16:515-21.

Homer B.L., Berry K.H., Brown M.B., Ellis G. & Jacobson E.R. 1998. Pathology of diseases in wild desert tortoises from California. *Journal of Wildlife Disease*. 34:508-23.

Johne R. & Müller H. 2007. Polyomavirus of birds: etiologic agents of inflammatory disorders in a tumor virus family. *Journal of Virology*. 81:11554-559.

Julian R. 1982. Water deprivation as a cause of renal disease of chickens. *Avian Pathology*. 11:615-617.

Lierz M. 2003. Avian renal disease: pathogenesis, diagnosis, and therapy. *Veterinary Clinics of North American Exotic Animal Practice*. 6:29-55.

Macbeth B.J. 2008. Obstructive urolithiasis, unilateral hydronephrosis, and probable nephrolithiasis in a 12-year-old Clydesdale gelding. *Canadian Veterinary Journal*. 49:287-290.

Mallinson E.T., Rothenbacher H., Wideman F.R., Snyder D.B., Russek E, Zuckerman A.I. & Davidson J.P. 1983. Epizootiology, pathology, and microbiology of an outbreak of urolithiasis in chickens. *Avian Disease*. 8:25-43.

Niznik R.A., Wideman R.F., Cowen B.S. & Kissel R.E. 1985. Induction of urolithiasis in single com white Leghorn pullets: effect on glomerular number. *Poultry Science*. 64:1430-1437.

Ozmen, O. 2005. Kidney pathology in non-obstructive urolithiasis in cattle. *Journal of Veterinary Medical Association*. 51:405-408.

Pollock C. 2006. Diagnosis and treatment of avian renal disease. *Veterinary Clinics of North American Exotic Animal Practice*. 9:107-128.

Riet-Correa F., Simões S.V.D., Vasconcelos J. 2009. Urolitíase em caprinos e ovinos. *Pesquisa Veterinária Brasileira*.28:319-322.

Robinson M.R., Norris R.D., Sur R.L. & Preminger G.M. 2008. Urolithiasis: not just a 2-legged animal disease. *Journal of Urology*. 179:46-52.

Saam D. 2001. Urethrolithiasis and nephrolithiasis in a horse. *Canadian Veterinary Journal*. J. 42:880-883.

Sigrist T. 2009. *The Avis Brasilis Field Guide to the Birds of Brazil*. 1ª ed. Avis Brasilis Editora, Vinhedo. 476p.

Sréter R. & Varga I. 2000. *Cryptosporidiosis in birds: a review*. *Veterinary Parasitology*. 97:201-278.

Wideman R.F., Closser Jr. J.A., Roush W.B. & Cowen B.S. 1985. Urolithiasis in pullets and laying hens: role of dietary calcium and phosphorus. *Poultry Science*. 64:2300-2307.