



Clinical Report

## Primary surgical repair of prostatic urethral rupture following multiple pelvic fracture in a dog

Vinicius Gonzalez Peres Albernaz<sup>1\*</sup>, Juliany Gomes Quitzan<sup>1</sup>, Renato Tavares Conceição<sup>1</sup>, Bruna Ribeiro Paiva<sup>1</sup>, Isabella de Almeida Fabris<sup>1</sup>, Paula Barreto da Rocha<sup>1</sup>

<sup>1</sup> Departamento de Cirurgia e Anestesiologia Veterinária, Universidade Estadual Paulista "Júlio de Mesquita Filho", Botucatu, São Paulo, Brazil,

### ARTICLE INFO

*Article history*

Received 14 October 2016

Received in revised form 27 January 2017

Accepted 06 February 2017

*Keywords:*

Urethra  
Laceration  
Trauma  
Surgery  
Canine

### ABSTRACT

Abdominal urethral rupture commonly occurs in male dogs after traumatic pelvic fractures and can lead to uroperitoneum, causing peritonitis and azotemia. The primary complications of urethral damage include strictures, incontinence and innervation injury. Here, we describe a case report of prostatic urethral rupture, treated by primary suture repair, that yielded early healing and recovery in a ten-year-old, male, mixed-breed dog who visited our facility within 24 hours of being struck by a car. Positive contrast urethrocytography resulted in leakage of the contrast medium into the abdominal cavity in a point caudal to the urinary bladder. Additional radiography revealed multiple pelvic fractures. During surgery, we found a laceration of the right prostatic lobe causing urethral rupture. We performed a full thickness simple continue suture with 7-0 polyglactin 910 to reestablish urethral continuity. The prostate capsule was also sutured in a simple continue pattern. A previously placed indwelling urinary catheter was kept inside to divert urine flow. On the third postoperative day, the animal withdrew the urinary catheter and started to urinate by himself. The conservative treatment of pelvic fractures enabled complete return to function on the 55th day. One hundred and fifty days after the trauma, no evidence of urinary stricture or another clinical sign was observed. Urethral wounds can be treated surgically by primary suturing and urinary diversion. A short healing time was experienced, and the indwelling urinary catheter was removed three days after surgery since there was no more urine leakage and the animal began voiding normally.

### INTRODUCTION

Urethral trauma occurs frequently in male dogs due to their having longer and more accessible urethras than females (BOOTHE, 2000). Such trauma can be associated with pelvic fractures or luxation, which represent 17-25% of all canine fractures (MESSMER; RYTZ; SPRENG, 2001). When a major force results in a pelvic fracture, the pelvis is compressed and its soft contents, including the bladder

and prostate, are tightened. These changes can cause the urethra to partially or completely rupture (KORAITIM et al., 1996). Abdominal urethral injury is more likely to cause urine leakage to the peritoneal or retroperitoneal space (BOOTHE, 2000). Uroperitoneum can cause abdominal pain, dehydration, haematuria or dysuria, progressive depression and hypothermia (BOOTHE, 2000).

\* Corresponding author: [vinicius.gp.albernaz@gmail.com](mailto:vinicius.gp.albernaz@gmail.com)

The primary complications of urethral trauma include strictures, urine leakage, incontinence and damage to the innervation of urethral sphincter (BOOTHE, 2000). Here, we describe a case report of prostatic urethral rupture in a dog treated by direct suture repair that yielded early healing and recovery. We also compare our findings with the literature. Additionally, we show a complex multiple pelvic fracture treated conservatively.

### CASE REPORT

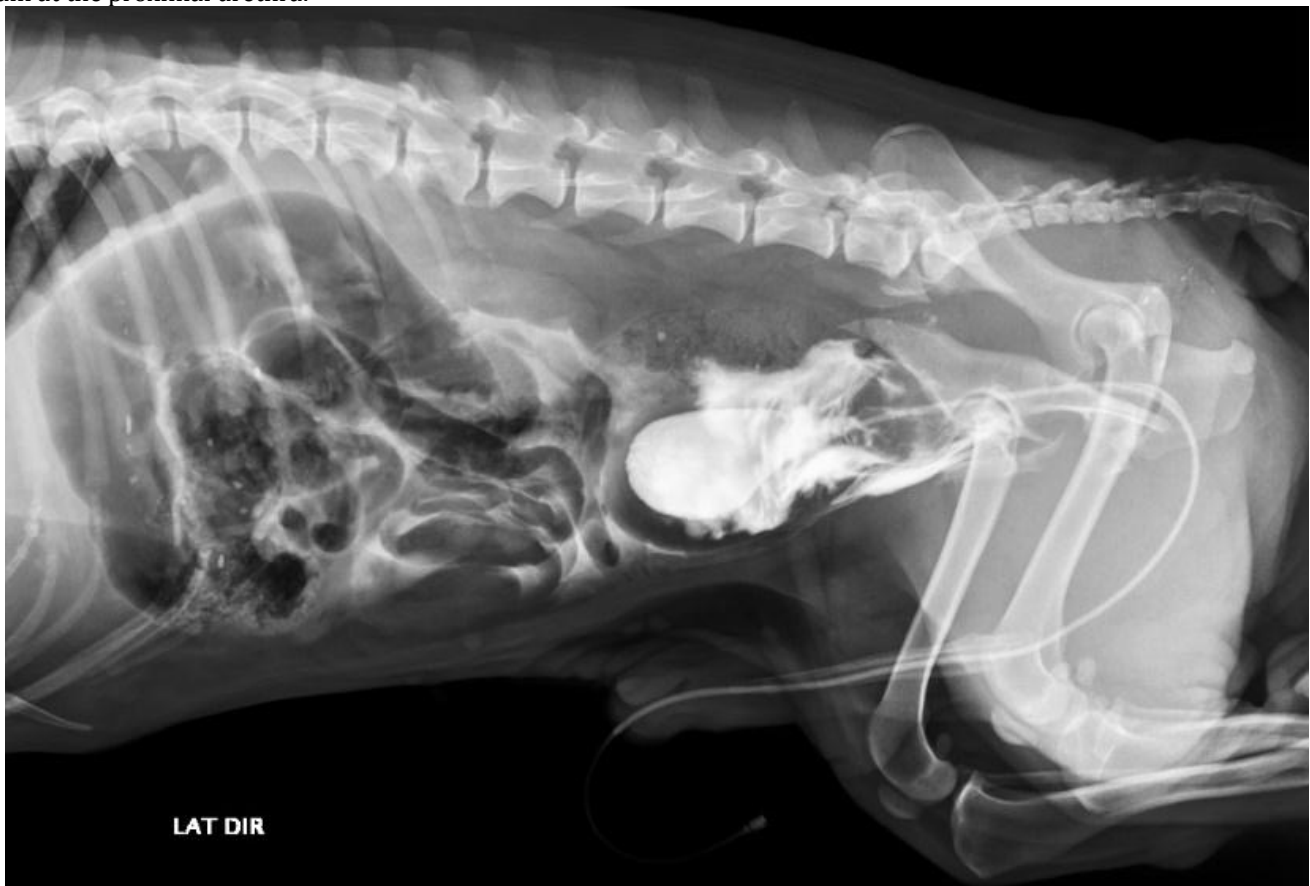A ten-year-old, male, mixed-breed, unneutered dog was brought to the veterinary hospital emergency room 24 hours after being struck by a car. The owner reported that the animal did not urinate after the trauma and could not stand on either of his pelvic limbs. Upon examination, the dog was quiet, alert, conscious and mildly dehydrated with pink mucous membranes and a capillary refill time of 2 seconds. Upon palpation, the abdominal region was painful and tense with a large area of mainly inguinal hematoma. Upon physical examination, we noted an asymmetry of the pelvic sides with increased mobility of the hemipelvis. A 10

Fr indwelling urinary catheter was placed and 6 ml.kg<sup>-1</sup> of sterile saline solution was administered with the goal of filling the bladder and evaluating its integrity. Only 2 ml.kg<sup>-1</sup> was recovered, however, suggesting leakage of urine into the peritoneal cavity.

A complete blood count revealed mild normochromic normocytic anemia, leukocytosis, neutrophilia and azotemia.

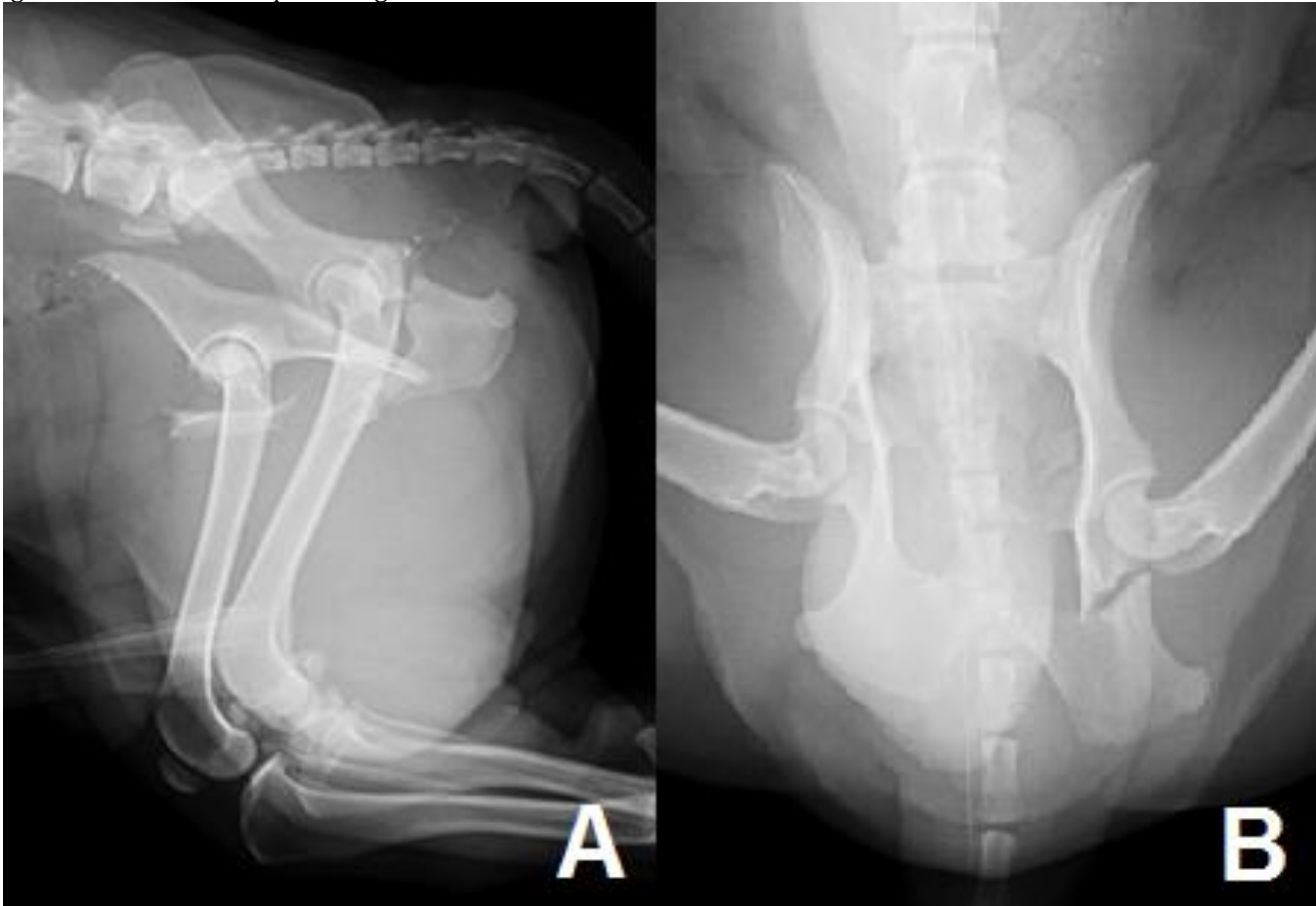
Positive contrast cystourethrography confirmed a rupture of the lower urinary tract, resulting in leakage of the contrast medium into the abdominal cavity (Figure 1). The urinary bladder was apparently intact because the contrast overflow point was caudal, raising suspicion of urethral rupture. Additional radiography revealed an oblique fracture of the right ilium body, multiple cranial and caudal pubic fractures, two fractures in the ischium body, and bilateral sacroiliac luxation (Figure 2). The iliac body and pubic fragment were found to be significantly moved in the ventral cranial direction and had apparently entered the caudal abdominal cavity.

Figure 1 – Cystourethrography with positive contrast showing an apparently intact urinary bladder and leakage of the contrast medium at the proximal urethra.



Source: Author's collection.

Figure 2 – Radiography of the pelvis in latero-lateral (A) and ventrodorsal (B) view. Both images show an oblique fracture of the right ilium body, ischium body, multiple pubic fractures and bilateral sacroiliac luxation. Severe cranial and ventral dislodgment of the ilium and pubic fragment can also be seen.



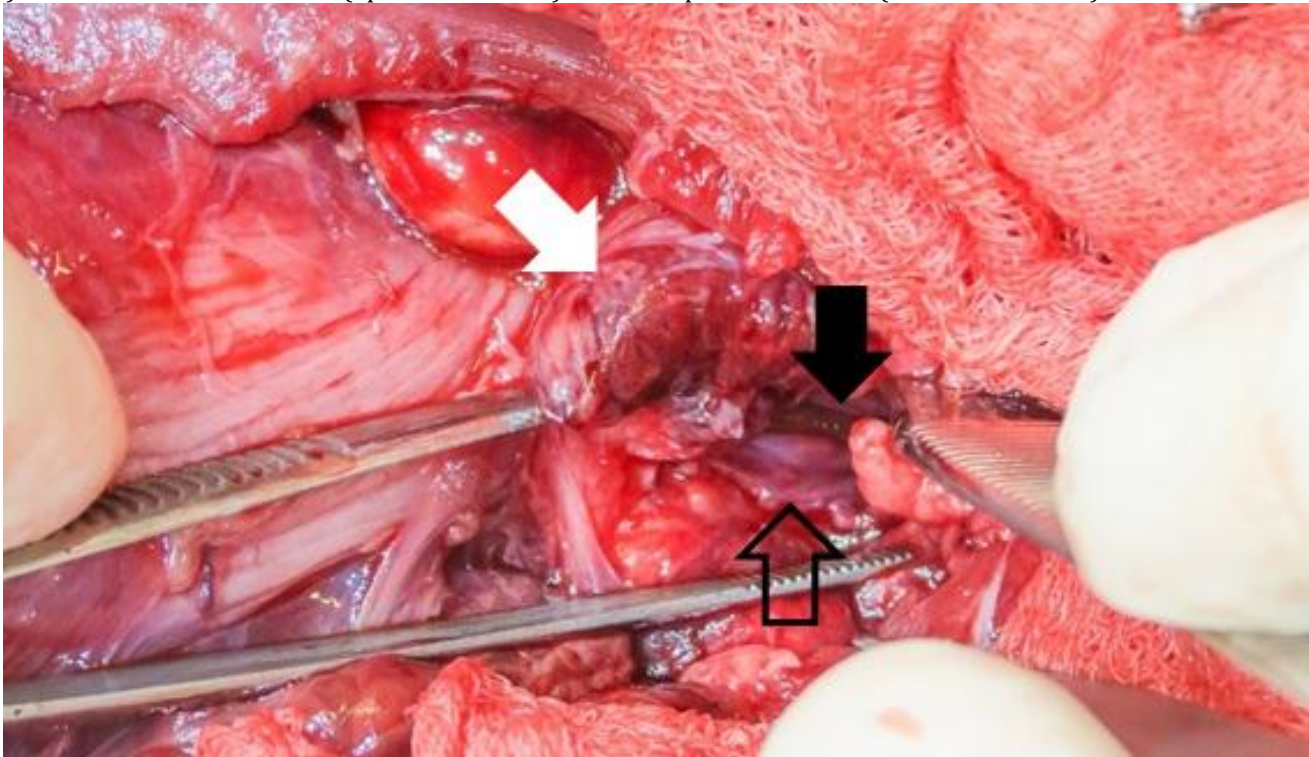
Source: Author's collection.

Through a median celiotomy, a surgical exploration of the abdominal cavity was performed. The urinary bladder wall was intact, but we noted a laceration in the right prostatic lobe. The 3-cm laceration had cut through the prostatic tissue and resulted in the rupture of the prostatic membranous urethra in equal lengths (Figure 3). Aided by a surgical magnification loupe (420 mm), we sutured the membranous urethra using 7-0 polyglactin 910 (Vicryl™, Ethicon, São Paulo, Brazil) in a full thickness simple continue pattern with the previously placed indwelling urinary catheter used as a stent. We noted leakage of the saline solution even after complete closure of the urethral laceration. To help seal up the urinary pathway, we sutured the prostate capsule using 3-0 polyglactin 910 (Vicryl™, Ethicon) in a simple continue pattern. Even after complete closure of the prostate and urethral defect, a small amount of solution still leaked. Palpation of the iliac

and hypogastric region inside the abdomen revealed an ileum body fragment within the peritoneal cavity. This fragment was likely the cause of urethral rupture, and it was reduced without fixation. The urinary catheter was fixed to ensure urine drainage.

During the postoperative period, the dog received ceftriaxone, dipyron, ranitidine hydrochloride, meloxicam, tramadol hydrochloride and 5 ml.kg<sup>-1</sup>.h<sup>-1</sup> lactate ringer's solution intravenously. Urine output monitoring revealed a normal production of urine (1–2 ml.kg<sup>-1</sup>.h<sup>-1</sup>) during the dog's entire hospital stay. On the third day, the dog inadvertently withdrew his urinary catheter and started to urinate by himself. Since normal urination persisted and no evidence of urine leakage was seen in an ultrasound, the dog was discharged to complete him treatment at home.

Figure 3 – Intraoperative view of the right prostatic lobe laceration. Note the presence of the urinary catheter (solid black arrow) in the membranous urethra (open black arrow) inside the prostatic wound (solid white arrow).



Source: Author's collection.

The owner of the dog did not agree with the surgical treatment of his pet's multiple pelvic fractures. A conservative treatment protocol based on cage rest for 4 weeks, lactulose and previously cited analgesic and anti-inflammatory drugs for 10 days was proposed. Approximately 15 days after the trauma, the animal regained his left pelvic limb function and was able to walk. On the 55th day after surgery, complete functional recovery of the pelvic limb was observed with only mild support lameness. Pelvic radiographies revealed complete bone healing and good alignment of the pelvic axis bilaterally. However, mild pelvic canal stenosis was also noted. One hundred and fifty days after the trauma, the animal was still in good condition and experiencing normal urination and defecation. No evidence of urethral stricture has been seen to date.

### DISCUSSION

It can be difficult to diagnose uroperitoneum because its clinical symptoms can be unspecific and related to diseases of multiple organ systems (BJORLING, 1984). One must pay attention to the history of the patient, which can include recent trauma, previous abdominal surgery or invasive procedures of the lower urinary tract, as well as the patient's attitude, appetite and ability to urinate on his or her own (BJORLING, 1984). Hematuria, oliguria or

anuria may be present in urethral rupture (BOOTHE, 2000). Animals with urine retention secondary to urinary tract trauma are expected to be azotemic (AUMANN; WORTH; DROBATZ, 1998). In this case report, one of the owner's complaints about his pet was his lack of urination. When associated with azotemia and radiographic imaging, this condition raised suspicious of a urinary trauma. Cystourethrography and a filling bladder test confirmed the leakage of urine.

Urinary tract trauma can occur secondary to blunt or penetrating trauma (TANKO et al., 2015). Blunt trauma can cause laceration or punctures due to bone fragments and shearing of ligamentous attachments, with potentially severe consequences (DREITLEIN; SUNER; BASLER, 2001; TANKO et al., 2015). Urethral injuries can be classified as laceration, transection and obstruction (BOOTHE, 2000). This dog suffered a blunt vehicular trauma, but lesions to his prostatic urethra were due to penetrating trauma caused by bone fragments from pelvic fractures, which led to worse injuries than those associated with blunt trauma. One study revealed that 39% of dogs with pelvic fracture were diagnosed with concurrent urinary tracts injuries and that 9% presented urethral rupture or avulsion (SELGER, 1982). Another retrospective study demonstrated a 37% rate of incidence of intra-abdominal injury following pelvic fracture, with only 3 of 31 dogs

presenting uroabdomen (HOFFBERG; KOENIGSHOF; GUIOT, 2016).

Conservative therapy is indicated for minor urethral injuries, such as contusion or minor lacerations, which was not the case in this study. According to the literature, large urethral defects can heal spontaneously by second intention if the mucosa remains intact and the urine flow is diverted (WEAVER; SCHULTE, 1962; MCLOUGHLIN, 2011; BLEEDORN; BJORLING, 2012).

Surgical procedures include temporary or permanent urine diversion, suturing of defects and urethral anastomosis (BOOTHE, 2000). In this case report, we conducted primary suture repair of a prostatic urethral laceration caused by a penetrating ilium fragment. The use of magnification loupes improved the identification of urethral mucosa (BLEEDORN; BJORLING, 2012). Even with magnification, we found that ensuring correct suture placement and avoiding mucosal tissue was difficult. However, excellent apposition could be obtained that allowed only a small amount of urine to leak. The primary factors interfering with urethral healing include a lack of mucosal continuity and urine leakage (BELLAH, 1989a). Urethral tissue edema makes it hard to identify layers and results in suboptimal suture placement and poor apposition (BELLAH, 1989b).

The principles of urethral suture include accurate approximation of the ends, tension-free apposition and the use of minimally reactive sutures (BOOTHE, 2000). In this case, we sutured using 7-0 polyglactin 910 in a full thickness simple continue pattern. The previously placed indwelling urinary catheter was used as a stent, followed by a suture in the prostate capsule using 3-0 polyglactin 910 in simple continue pattern. The choice of a 7-0 absorbable suture was made because of its low urinary reaction, fast absorption, low cost and small caliber, which decreased the risk of stenosis (MCLOUGHLIN, 2011). Studies have demonstrated that procedures involving both suture and catheterization have less dysuria and urethral stricture compared with only-suture procedures, suggesting that urine leakage at the site of the anastomosis is a critical factor for stricture formation (LAYTON et al., 1987).

Some authors have recommended maintenance of intraurethral catheter for 7–21 days after surgical repair of an injury (WEAVER; SCHULTE, 1962; BOOTHE, 2000; MACPHAIL, 2013). In general, urine flow should be diverted from pelvic or perineal urethral incisions or traumatized sites until epithelialization is complete (BOOTHE, 2000). In this dog, we used an indwelling urinary catheter to divert urine flow, but the animal withdrew it inadvertently before the planned time.

Nonetheless, three days of urine divert was adequate to enable normal urine flow through the urethra. This improvement occurred thanks to the urethral border apposition sutures. A reduction in the number of days of catheterization is associated with remarkable advantages, such as a decrease in genitourinary tract colonization by bacteria, infection and other urethral injuries, such as stricture (BIARDEAU; CORCOS, 2016). Other options to treat traumatic urethral injury—such as urethrostomy and/or tube cystostomy—were not necessary.

The complications of urethral injuries include stricture formation, incontinence, urethrocuteaneous fistula formation and urine leakage (ANSON, 1987; MCLOUGHLIN, 2011). A retrospective analysis has noted that multiple traumatic injuries are a unique prognostic factor associated with poor outcomes in dogs and cats with urethral rupture (ANDERSON et al., 2006).

Despite multiple pelvic fractures in this case having a clear indication of surgical repair due to the affected weight-bearing arch, bilateral pelvic injury and severe displacement of fragments (JOHNSON, 2013), the owner did not agree with this option and preferred conservative management. This case report reveals that even a severely displaced ilium fracture can be successfully treated conservatively with appropriate management. Mild persistent lameness was present, as has been described in studies evaluating conservative treatment of pelvic fractures (VASSALO et al., 2015).

The treatment of pelvic fractures depends on several factors such as the severity of concomitant injuries, the degree of instability and pain, ability of the animal to ambulate and financial considerations (JOHNSON, 2013).

## CONCLUSION

This paper reports a primary suture repair of a prostatic urethra laceration caused by penetrating ileum fracture. We noted a shorter recovery time than those reported in the literature, and our procedure was not associated with any complications. In addition, the conservative treatment of multiple pelvic fractures with large fragment displacement enabled full return to function.

## REFERENCES

- ANDERSON, R. et al. Prognostic factors for successful outcome following urethral rupture in dogs and cats. *Journal of American Animal Hospital Association*, v. 42, n. 2, p.136-146, 2006.
- ANSON, L. W. Urethral trauma and principles of urethral surgery. *Compendium on Continuing Education for the Practising Veterinarians*, v. 9, n. 10, p.981-988, 1987.



AUMANN M., WORTH, L. T., DROBATZ, K. J. Uroperitoneum in cats: 26 cases (1986-1995). **Journal of the American Animal Hospital Association**, v. 34, n. 4, p.315-324, 1998.

WEAVER R. G., SCHULTE J. W. Experimental and Clinical Studies of Urethral Regeneration. **Surgery, Gynecology & Obstetrics**, v. 115, n. 1, p. 729-736, 1962.

BELLAH, J. R. Problems of the Urethra. Surgical Approaches. **Problems Veterinary Medicine**, v. 1, n. 1, p.17-35, 1989a.

BELLAH, J. R. Wound healing in the urinary tract. **Seminars in Veterinary Medicine and Surgery Small Animal**, v. 4, n. 4, p.294-303, 1989b.

BIARDEAU, X., CORCOS, J. Intermittent catheterization in neurologic patients: Update on genitourinary tract infection and urethral trauma. **Annals Physical and Rehabilitation Medicine**, v. 59, n. 2, p.125-129, 2016.

BJORLING, D. E. Traumatic injuries of the urogenital tract. **Veterinary Clinics of North America Small Animal Practice**, v. 14, n. 1, p.61-76, 1984.

BLEEDORN J. A., BJORLING D. E. Urethra. In: TOBIAS K. M., JOHNSTON S. A. (Ed.) **Veterinary Surgery Small Animal**. 1st ed. St. Louis: Elsevier Saunders, 2012, v. 2, p. 1993-2010.

BOOTHE H.W. Managing Traumatic Urethral Injuries. **Clinical Techniques in Small Animal Practice**, v. 15, n. 1, p.35-39, 2000.

DREITLEIN D. A., SUNER S., BASLER J. Genitoruinary Trauma. **Emergency Medicine Clinics of North America**, v. 19, n. 3, p.569-590, 2001.

HOFFBERG J. E., KOENIGSHOF A. M., GUIOT L. P. Retrospective evaluation of concurrent intra-abdominal injuries in dogs with traumatic pelvic fractures: 83 cases (2008-2013). **Journal of Veterinary Emergency and Critical Care**, v. 26, n. 2, p.288-294, 2016.

JOHNSON A. L. Management of Specific Fractures. In: FOSSUM, T.W. (Ed) **Small Animal Surgery**. 4th edn. St. Louis: Elsevier Mosby, 2013, v. 1, p. 1106-1214.

KORAITIM, M. M., et al. Risk factors and mechanism of urethral injury in pelvic fractures. **British Journal of Urology**, v. 77, n. 6, p.876-880, 1996.

LAYTON, C. E., et al. Intrapelvic Urethral Anastomosis – A Comparison of Three Techniques. **Veterinary Surgery**, v. 16, n. 2, p.175-182, 1987.

MACPHAIL C. M. Surgery of the Bladder and Urethra. In: FOSSUM, T.W. (Ed) **Small Animal Surgery**. 4th edn. St. Louis: Elsevier Mosby, 2013, v. 1, p. 735-779.

MCLOUGHLIN, M. A. Complications of lower urinary tract surgery in small animals. **Veterinary Clinics of North America Small Animal Practice**, v. 41, n. 5, p.889-913, 2011.

MESSMER, M., RYTZ, U., SPRENG, D. Urethral entrapment following pelvic fracture fixation in a dog. **Journal of Small Animal Practice**, v. 42, n. 7, p.341-344, 2001.

SELCER, B. A. Urinary tract trauma associated with pelvic trauma. **Journal of the American Animal Hospital Association**, v. 18, n. 1, p. 785, 1982.

TANKO M.S., et al. Traumatic Urinary Bladder Injuries in Small Animals. **Journal of Veterinary Medicine and Animal Health**, v. 7, n. 1, p.27-32, 2015.

VASSALO F. G. et al. Gait Analysis in dogs with pelvic fractures treated conservatively using a pressure-sensing walkway. **Acta Veterinaria Scandinavica**, v. 57, n. 1, p.1-7, 2015.