




Short communication

Unilateral idiopathic renal hematuria in a dog

Hematúria renal idiopática unilateral em um cão

Giovana Biezus¹ , Jéssica Aline Withoef¹ , Thierry Grima de Cristo¹ , Marília Gabriela Luciani¹ , Paulo Eduardo Ferian¹ , Renata Assis Casagrande^{1*} 

¹ Departamento de Medicina Veterinária, Universidade do Estado de Santa Catarina, Lages, Santa Catarina, Brasil.

ARTICLE INFO

Article history

Received 24 September 2018

Accepted 03 April 2019

Keywords:

Renal hemorrhage

Nephrectomy

Nephrectomy

ABSTRACT

Idiopathic renal hematuria is diagnosed in situations where the cause of hematuria is not clear, even after ruling out all possible differential diagnoses. A 14-year-old female Cocker Spaniel with continuous hematuria as the only clinical sign for two months. Concomitant changes were ruled out by blood tests, urinalysis, and abdominal ultrasonography. It was evidenced that hematuria originated from the left kidney through ureteral catheterization and the diagnosis of idiopathic renal hematuria was determined by excluding other possible causes of renal hematuria. Idiopathic renal hematuria is a rarely reported disease but has great importance as a differential diagnosis in cases where the main clinical sign is hematuria.

RESUMO

A hematúria renal idiopática é diagnosticada em situações onde a razão da hematúria não é esclarecida, descartando-se todos os possíveis diagnósticos diferenciais. Um cão, fêmea, Cocker Spaniel com 14 anos de idade manifestou hematúria contínua como único sinal clínico, por dois meses. Foram descartadas alterações concomitantes, por meio de exames de sangue, urinálise e ultrassonografia abdominal. A hematúria proveniente do rim esquerdo foi evidenciada através de cateterização ureteral e o diagnóstico de hematúria renal idiopática foi obtido por meio da exclusão de outras possíveis causas de hematúria renal. A hematúria renal idiopática é uma doença pouco relatada, no entanto apresenta grande importância como diagnóstico diferencial nos casos onde o principal sinal clínico é a hematúria.

Palavras-chave:

Hemorragia renal

Nefrectomia

Nefrologia

INTRODUCTION

Hematuria is a common clinical sign in the veterinary clinical routine and may indicate the presence of diseases in the urinary or genital tract. Commonly caused by urinary tract infections, inflammatory diseases, neoplasms, and traumas, it may occur less frequently due to vascular diseases and coagulopathies. When it occurs throughout urination and is the only essential clinical sign, upper urinary tract diseases in the kidneys and ureters should be investigated for the

purpose of establishing the primary cause of bleeding (DiBARTOLA; WESTROPP, 2015).

Idiopathic renal hematuria (IRH) is a poorly described clinical condition in veterinary medicine. The first reports of IRH date back to the 1980s and have been described sporadically over time (HOLT; LUCKE; PEARSON, 1987; MISHINA et al., 1997; HAWTHORNE et al., 1998; BERENT *et al.*, 2013; DI CICCIO et al., 2013; ADELMAN; BARTGES; WHITTEMORE, 2017). This condition is diagnosed when continuous or intermittent hematuria comes from one or both kidneys (MISHINA et

* Corresponding author: renata.casagrande@udesc.br

al., 1997). Generally, it does not promote histological changes in the renal parenchyma, making it impossible to determine the etiology (STONE; DENOVO; RAWLINGS, 1983). Hematuria is often reported as the only clinical sign, but in cases where blood loss is massive, there is a risk of developing anemia and the formation of blood clots that can obstruct the urinary tract (BERENT; WEISSE, 2013; STONE; DENOVO; RAWLINGS, 1983).

To confirm that hematuria comes from the kidneys, urethrocytostomy becomes the diagnostic method with less invasiveness, but in cases where it is not available, laparotomy for cystotomy and catheterization of the ureters is the only possible diagnostic method (MISHINA et al., 1997; BERENT et al., 2013). For the diagnosis of IRH, urinalysis, complete blood count, serum biochemistry, excretory urography, and ultrasonography should be performed to rule out the possible causes of hematuria, concluding, therefore, that it's triggering

mechanism is unknown. (MISHINA et al., 1997). The present report aims to describe a case of IRH in a dog.

CASE REPORT

A 14-year-old canine female, Cocker Spaniel, was treated with hematuria and blood clots in the urine for approximately two months, worsening in the last 20 days, and absence of other alterations in the physical examination. In the anamnesis, the dog guardian reported that the patient did not present alterations in addition to hematuria, reports vaccination and control of periodic parasites and absence of previous diseases.

Complete blood counts, serum biochemistry, abdominal ultrasonography and uroculture with antibiogram were performed. The only change observed was increased serum creatinine levels (Tables 1 and 2).

Table 1 – Results of complete blood counts during clinical approaches dog diagnosed with idiopathic renal hematuria.

Parameters	1	2 (15 th day)	3 (17 th day)	4 (19 th day)	References values ¹
RBC (x10 ⁶ /μL)	5,48	4,18	1,72	2,24	5,5 - 8,5
Hemoglobin (g/dL)	13,0	10,6	3,5	5	12 - 18
Hematocrit (%)	39	32	12	16	37 - 55
MCV (fL)	71,2	77,6	69,8	71,4	60 - 77
MCHC (%)	33,33	33,1	29,2	31,3	32 - 36
Nucleated Eryth. (/100 L.)	0	0	22	0	*
Platelets (x10 ³ /μL)	432	407	281	402	200 - 500
WBC (/μL)	13430	14930	21311	14100	6000 - 17000
N. bands (/μL)	0	0	260	423	0-300
N. segmented (/μL)	10073	9555	21060	12972	3000-11500
Lymphocytes (/μL)	1612	3882	2600	141	1000 - 4800
Eosinophils (/μL)	940	597	0	0	150 - 1250
Basophils (/μL)	0	0	0	0	Rare
Monocytes (/μL)	806	896	2080	564	150 - 1350

Source: By the author. ¹ Reference values by Weiss e Wardrop (2010); RBC: red blood cell count; MCV: mean corpuscular volume; MCVC: mean corpuscular hemoglobin concentration; Eryth.: erythrocytes; WBC: white blood cell count; N.: neutrophils; *Unusual cells in the bloodstream.

Table 2 – Results obtained in the evaluation of serum biochemistry during the clinical approaches of the dog with renal idiopathic hematuria.

Parameters	1	2 (15 th day)	3 (17 th day)	Reference values ¹
Urea (mg/dL)	47,56	-	167,42	21 - 59,92
Creatinine (mg/dL)	1,57	1,23	2,74	0,5 - 1,5
Alanine aminotransferase (UI/L)	44,27	-	1,38	21 - 86
Alkaline phosphatase (UI/L)	39,05	-	-	20 - 156
Gamaglutamyl transferase (UI/L)	-	3,87	-	1,2 - 6,4
Total serum protein (g/dL)	5,5	-	-	5,4 - 7,1
Albumin (g/dL)	2,47	-	-	2,6 - 3,3

Source: By the author. ¹ Reference values by Kaneko; Harvey; Bruss (1997).

On ultrasonography, the bladder was distended by a liquid, with no alterations in the wall thickness, and in the lumen, there was an echogenic and heterogeneous

non-vascularized circular structure with well-defined contours measuring 2,33 cm in diameter (Figure 2A). Both kidneys had no alterations in imaging tests.

Urine analysis was reddish, with sui generis odor, intense turbidity and a density of 1.026; in the chemical evaluation, showed three protein crosses and pH 6; in the cytological and sediment analysis fields were filled by erythrocytes, accompanied by 20 to 30 leukocytes. In the uroculture, there was no bacterial growth in 48 hours of incubation. To the exclusion of coagulation disorders, tests of activated partial thromboplastin, prothrombin time and coagulation time were performed, without evident alterations.

One week after the first clinical approach, a new ultrasonographic evaluation of the urinary tract was performed and the bladder had a focal ventrocranial wall thickening (0.303cm [ref. 0,2cm]) and in the lumen, the same structure of the previous examination was visualized.

After fifteen days, due to the persistence of clinical signs, new hematological and biochemical analyzes were performed for pre-anesthetic evaluation of the patient (Tables 1 and 2), this time demonstrating a slight decrease in red blood cell count. The patient underwent exploratory cystotomy for inspection of the bladder wall and removal of the structure visualized on ultrasonography.

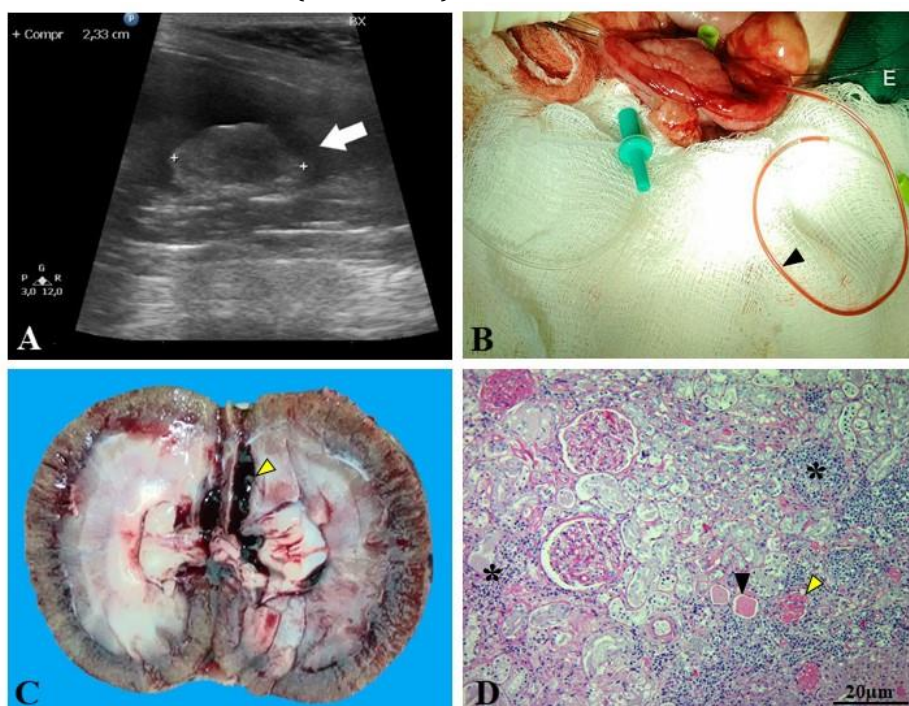During the surgical approach, although the mucosa was unaltered, a dark red, shiny friable mass, compatible with a clot, was observed. At the inspection of the mucosa, no bleeding point was detected. Thus, mucosal

lavage and retrograde catheterization followed by double-layer cystorrhaphy were performed as recommended by Macphail (2015). For the procedure, a 3-0 Polyglycolic Acid yarn was chosen. After surgery, antibiotic therapy was instituted with amoxicillin and potassium clavulanate (20mg/kg, BID), tramadol hydrochloride (4mg/kg, TID) and sodium dipyrone (25mg/kg, TID).

In the postoperative period, the patient's urine was clear, but after 24 hours he returned to present severe hematuria, in addition, the conjunctive and oral mucosa became intensely pale. The third hemogram showed normocytic and hypochromic anemia accompanied by mature neutrophilia (Table 1), requiring a blood transfusion. With the worsening of the clinical condition and the absence of evidence of lower urinary tract disease, hemorrhage from the upper urinary system was suspected.

The patient underwent a second cystotomy, performed in the same way previously described. Urethral catheters (# 4) were introduced into the ureters in the retrograde direction, which demonstrated hematuria from the left kidney (Figure 2B), and left total nephrectomy was performed. The removed kidney was incised sagittally, allowing blood clots to be visualized in the renal pelvis (Figure 2C). In addition, the surgical specimen was referred for histopathological analysis, in which discrete multifocal lymphoplasmacytic glomerulonephritis was evident (Figure 2D).

Figure 2 - Dog diagnosed with idiopathic renal hematuria. A) Image of the bladder obtained during the first abdominal ultrasonography, demonstrating an echogenic and heterogeneous circular area with well-defined contours of 2,33 cm in diameter (arrow). B) Catheterization of the right (D) and left (E) ureters, demonstrating hematuria from the left kidney (arrow). C) Left kidney incised after nephrectomy demonstrating blood clot in the pelvis (arrow). D) Photomicrography of the left kidney with lymphoplasmacytic glomerulonephritis (asterisks), multifocal glomerular sclerosis (yellow arrow) and amorphous eosinophilic intratubular material (black arrow).



In the immediate postoperative period, the patient remained stable and without hematuria, after 48 hours developed vomiting and ranitidine (2mg / kg, BID) and metoclopramide (0.5mg / kg, TID) were added to the treatment. A fourth and last hemogram was performed with an increase in RBC and hematocrit compared to the third, and WBC was normalized (Table 1). In the third serum biochemistry analysis, creatinine levels were elevated compared to previous serum tests (Table 2).

New abdominal ultrasonography was also performed, in which hyperechogenic free intracavitary fluid was detected, suggesting marked cellularity; In addition, hyperechoic reactive mesentery and irregular and discrete presence of reverberation artifact (pneumoperitoneum) were noted. The intracavitary fluid was collected and the creatinine value obtained was (2.83 mg / dL). Due to these changes, bladder suture dehiscence was suspected, with consequent leakage of urine and the development of peritonitis. The patient died three days after the second cystotomy and before the new surgical procedure to correct the dehiscence.

The cause of the death was confirmed by the necropsy where a large amount of serosanguineous liquid was visualized in the abdominal cavity; the bladder adhered to the intestinal loops and peritoneum with abundant fibrin deposition, a wall discontinuity area of approximately 2cm was observed, with suture threads adjacent to the edges. The right kidney had a heterogeneous white-brown coloration. In the microscopic evaluation, the right kidney presented the same changes described for the left kidney. In the bladder, only fibrinonecrotic and suppurative cystitis was observed at the site of suture dehiscence.

DISCUSSION

The diagnosis of IRH was obtained after exclusion of any other disease leading to bleeding of the structures of the urinary tract, discarding possible traumas, neoplasias, inflammatory or infectious diseases, and coagulopathies, based on the absence of erythrogram, leukogram and hemostasis changes, of serum biochemistry, negative uroculture, and imaging.

Among the clinical signs demonstrated throughout the clinical evolution, only hematuria was observed. In other reports, hematuria has also been described as the only clinical sign, with development ranging from 2 to 5 months (HOLT; LUCKE; PEARSON, 1987; BERENT et al., 2013). Continuous blood loss led to the formation of blood clots present in both the lumen of the bladder and the pelvis of the kidneys. In some cases, they may still lead to a urethral obstruction, generating strangury, dysuria, and hydronephrosis (HAWTHORNE et al., 1998).

The complication of the patient's hematuria after the first cystotomy led to the development of a second clinical sign, anemia, which is also observed in other reports of severe hematuria (DI CICCIO et al., 2013). Anemia, usually regenerative, develops by the massive

loss of blood and normalization of hematological patterns is obtained in response to nephrectomy in cases where hematuria is unilateral (HOLT; LUCKE; PEARSON, 1987). As in this patient, cases of severe hematuria in which the risk of death is imminent, blood transfusion is required (BERENT; WEISSE, 2013).

Although the alterations in the imaging evaluation are of great importance for the differential diagnosis, in this disease, there are no radiographic or ultrasonographic changes that characterize it, except blood clots along the urinary tract, mainly in the bladder (BERENT et al., 2013), as was observed in this patient.

In most cases of IRH, the absence of azotemia is reported (BERENT *et al.*, 2013). The discrete increase in serum creatinine observed in this patient's first examination may be considered insignificant, since serum urea concentrations and urine density were not altered. In addition, in the second laboratory evaluation creatinine was normalized even without therapeutic intervention. However, in some cases, azotemia may develop, being related to secondary problems, such as urethral obstruction due to blood clots (HOLT; LUCKE; PEARSON, 1987; HAWTHORNE et al., 1998). In the present report, the significant increase in creatinine in the third exam is not related to the clinical alterations mentioned above, but to the dehiscence of cystorrhaphy, which led to extravasation of urine into the abdominal cavity.

Exploratory laparotomy proved to be useful as a diagnostic method, allowing assessment of structures, identification of the source of bleeding, and inspection of the wall of the bladder and urethra. This approach becomes necessary when methods such as urethroscopy are not available (HAWTHORNE et al., 1998; BERENT et al., 2013). The definitive diagnosis of renal hematuria in these cases can be obtained by direct visualization of the presence of blood in the urine through ureteral catheterization (HOLT; LUCKE; PEARSON, 1987), as performed in this report.

Histopathological analysis of the kidneys characterized mild lymphoplasmacytic glomerulonephritis, which cannot be considered a cause of hematuria since it is common in elderly animals by the deposition of immunocomplexes in the glomeruli and is often an incidental postmortem finding (INKELMANN et al., 2012). It is also noted that the histopathological examination showed the same alteration in both kidneys, but hematuria originated only from the left kidney, an important fact to demonstrate that the histopathological alteration is not related to hematuria.

IRH tends to be unilateral, but in some cases, it may be present bilateral (HOLT; LUCKE; PEARSON, 1987). In cases in which bilateral involvement is suspected, it is recommended to use techniques that preserve the integrity of the renal parenchyma, such as partial occlusion of the renal artery and administration of sclerosing agents such as povidone-iodine (MISHINA *et*

al., 1997; BERENT et al., 2013). But these techniques require trained professionals and specific equipment. It has justified the use of nephrectomy in cases in which hemorrhage is serious and promotes the risk of death of the animal and in cases where hematuria is unilateral, in these cases the total nephrectomy of the affected kidney a curative intervention (STONE; DENOVO; RAWLINGS, 1983; BERENT; WEISSE, 2013; ADELMAN; BARTGES; WHITTEMORE, 2017).

The patient's prolonged clinical follow-up after the surgical procedure was not possible since death occurred due to dehiscence of the bladder suture. Although the patient is receiving antibiotic therapy, the possibility of bacterial resistance must be taken into account, since the polyglycolic acid is rapidly degraded when there is bacterial contamination in the urine, these factors may have influenced the dehiscence of the suture, promoting fibrinonecrotic cystitis evidenced in the histopathological evaluation (FILHO et al., 2015).

CONCLUSION

Continuous hematuria, absence of concomitant diseases and the presence of blood from the left kidney observed through ureteral catheterization, characterized unilateral idiopathic renal hematuria. Although it is a rare clinical condition, it is necessary to include it within the differential diagnoses when encountering a patient with hematuria.

REFERENCES

- ADELMAN, L. B.; BARTGES, J.; WHITTEMORE, J. C. Povidone iodine sclerotherapy for treatment of idiopathic renal hematuria in two dogs. **Journal of the American Veterinary Medical Association**, v. 250, n. 2, p. 205-210, 2017.
- BERENT, A. C. et al. Endoscopic-guided sclerotherapy for renal-sparing treatment of idiopathic renal hematuria in dogs: 6 cases (2010-2012). **Journal of the American Veterinary Medical Association**, v. 242, n. 11, p. 1556-1563, 2013.
- BERENT, A.; WEISSE, C. Idiopathic Renal Hematuria/Benign Essential Renal Hematuria, In: MONNET E. **Small Animal Soft Tissue Surgery**. 1 ed. Ames: John Wiley & Sons, Inc, 2013. cap. 59, p. 615-622.
- DiBARTOLA, S. P.; WESTROPP, J. L. Manifestações clínicas das doenças do trato urinário. In: NELSON, R. W.; COUTO, C. G. **Medicina interna de pequenos animais**. Rio de Janeiro: Guanabara Koogan, 2015. cap.41, p. 629-637.
- DI CICCO, M. F. et al. Management of bilateral idiopathic renal hematuria in a dog with silver nitrate. **Canadian Veterinary Journal**, v. 54, p. 761-764, 2013.
- FILHO, S. H. A. et al. Aspectos gerais dos fios de sutura utilizados ou com potencial aplicabilidade na medicina veterinária. **Enciclopédia Biosfera**, v. 11, n. 22, p. 319-350, 2015.
- MACPHAIL, C.M. Cirurgia da bexiga e da uretra. In: FOSSUM, T. W. **Cirurgia de pequenos animais**. 4.ed. Rio de Janeiro: Elsevier, 2014. cap. 26, p. 735-779.
- HAWTHORNE, J. C. et al. Recurrent urethral obstruction secondary to idiopathic renal hematuria in a puppy. **Journal of the American Animal Hospital Association**, v. 34, p. 511-514, 1998.

HOLT, P. E.; LUCKE, V. M.; PEARSON, H. Idiopathic renal haemorrhage in the dog. **Journal of Small Animal Practice**, v. 28, p. 253-263, 1987.

INKELMANN, M. A. et al. Lesões do sistema urinário em 1.063 cães. **Pesquisa Veterinária Brasileira**, v. 32, n. 8, p. 761-771, 2012.

KANEKO, J.J., HARVEY, D.W., BRUSS, W.L. **Clinical biochemistry of domestic animals**. 5th ed. San Diego: Academic Press, 1997. 932 p

MISHINA, M. et al. Idiopathic renal hematuria in a dog: the usefulness of a method of partial occlusion of the renal artery. **The Journal of Veterinary Medical Science**, v. 59, p. 293-295, 1997.

STONE, E. A.; DENOVO, R. C.; RAWLINGS, C. A. Massive hematuria of nontraumatic renal origin in dogs. **Journal of the American Veterinary Medical Association**, v. 183, n. 8, p. 868-871, 1983.

WEISS, D. J.; WARDROP K. J. **Schalm's veterinary hematology**. 6 ed. Ames: Blackwell Publishing Ltd, 2010. 1206 p.