












Case report

## Subcutaneous advancement flap for snout reconstruction after traumatic injury in a dog: case report

Retalho em avanço de padrão subdérmico para reconstrução de focinho após lesão traumática em canino: relato de caso

Jaese Farias Chaves<sup>1\*</sup> , Marcella Pinheiro Souto<sup>1</sup> , Lisiane Diniz e Souza<sup>1</sup> , Ana Celi Santos Costa<sup>1</sup> , Lais Andressa Silva de Souza<sup>2</sup> , Gabriele Sousa Silva<sup>1</sup> , Angelo Renan Moraes da Costa<sup>1</sup> , Katiane Schwanke<sup>1</sup> , Fabrícia Geovânia Fernandes Filgueira<sup>3</sup> 

<sup>1</sup> Veterinary Hospital, Castanhal campus, Federal University of Pará, Brazil

<sup>2</sup> São Paulo State University, Brazil

<sup>3</sup> Adílio Santos de Azevedo Veterinary Hospital, Sousa campus, Federal Institute of Paraíba, Brazil

### ARTICLE INFO

#### Article history

Received 08 January 2019

Accepted 06 May 2019

#### Keywords:

Reconstructive surgery

Subcutaneous flap

Muzzle

Canine

Anaplasty

### ABSTRACT

Reconstructive plastic surgery in companion animals is increasing in surgical blocks. Pedicle skin flaps on the face of dogs and cats are of difficult execution, making it challenging for the surgeon. The objective of this work is to report a skin reconstruction of a dog's face after trauma. A male dog of unknown breed, presenting trauma of unknown cause with total loss of snout and part of incisive bone, was attended at the Veterinary Hospital of the Federal University of Pará, Brazil. Emergency care was performed and the animal was referred for surgical debridement of the lesion and posterior plastic correction. A subcutaneous facial advancement flap was used to cover the wound, demonstrating that this is a good option in this region due to the low elasticity of the skin. There were no interurrences in the postoperative period and the animal presented good functional and cosmetic results.

### RESUMO

A cirurgia plástica reconstrutiva em animais de companhia vem cada vez mais tomando espaço dentro do bloco cirúrgico. Retalhos pediculados de pele em face de cão e gato são de difícil execução tornando-se desafiador para o cirurgião. O objetivo deste trabalho é relatar a reconstrução cutânea de face de um cão após trauma. Foi atendido no Hospital Veterinário da Universidade Federal do Pará um cão, macho, sem raça definida, apresentando trauma de causa desconhecida com perda total de focinho e parte de osso incisivo. Foi realizado o atendimento emergencial e encaminhado para desbridamento cirúrgico da lesão e posterior correção plástica. Foi realizado um retalho de padrão subdérmico de avanço facial para cobertura da ferida, demonstrando este ser uma boa opção nessa região devido à pouca elasticidade da pele. Não houve intercorrências no pós-operatório e o animal apresentou bons resultados funcionais e cosméticos

#### Palavras-chave:

Cirurgia reconstrutiva

Flap subdérmico

Focinho

Canino

Anaplastia

### INTRODUCTION

Reconstructive surgery in companion animals is used to repair large losses of cutaneous tissue when primary closure is not acceptable because of over-tension usually due to tumor resections, but may also be due to burns and primary or secondary infections that cause tissue

necrosis and traumas in general. There are numerous technical methods of reconstructive surgery, such as skin grafts and flaps, or use of sutures for tension relief or relaxation incisions (PAVLETIC, 2018; SCHEFFER et al., 2013).

\* Corresponding author: [jaesefch@live.com](mailto:jaesefch@live.com)

Application of subcutaneous pedicle flaps is one of the most commonly used reconstructive surgical techniques in veterinary medicine, in which the skin adjacent to the site of lesser stress of the defect is divulsed, becoming a sufficient loose elastic cut to cover the wound. This technic evolves with good aesthetic results and is easy to execute (PARGANA, 2009).

Complications are expected, as in any surgical procedure, and are subject to the general condition of the patient, condition of the area receiving the graft, and the type of surgical procedure used. Seroma is commonly observed as an intercurrance in the postoperative period, besides dehiscence, edema, infection, and necrosis (PAVLETIC, 2018).

Skin lesions on the face are difficult to reconstruct due to the lack of cutaneous elasticity in this region; usually the doctor opts for a palliative treatment with dressings and follow-up of wound healing by second intention (HUPPES et al., 2016). In these cases, when treating surgical wound closure, there are basically advancement flap techniques, mainly in the snout area, which requires more delicate care due to the lack of skin mobility in this region (MOTA et al., 2012).

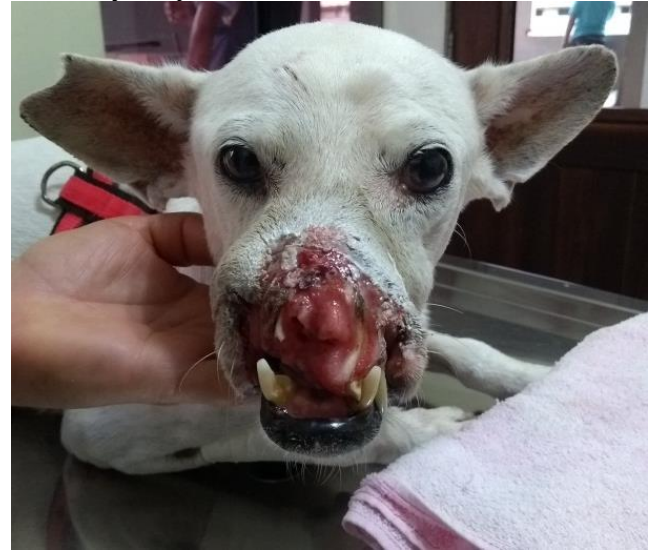Thus, the objective of this work is to report a case of cutaneous reconstruction of snout using the subcutaneous facial advancement flap technique in a dog that suffered a trauma of unknown origin.

### CASE REPORT

A male, uncastrated dog of unknown breed and unknown age was attended at the Veterinary Hospital of the Federal University of Pará, Brazil. It presented a facial trauma and complete skin and bone losses in the muzzle region for 22 days (Figure 1). The animal had been subjected to emergency care in the place of residence, where the wound was cleaned and medicated with topical enrofloxacin (Alantol®; 10 mg kg<sup>-1</sup>) for five days, and ketoprofen (2 mg kg<sup>-1</sup>) for four days. The animal was fed only with moist feed because of the tissue loss in the upper lip region. The dog had ticks and fleas diffusely across the body and was not vaccinated or wormed.

The dog was evaluated and subjected to physical examination: it presented heartbeat rate of 188 beats per minute and respiratory rate of 40 breaths per minute, rectal temperature of 38.4 °C, capillary perfusion time of two seconds, and pink ocular and oral mucous membranes. Abdominal palpation revealed hepatosplenomegaly. The animal was referred to fluid therapy for correction of the fluid loss that was established by the physical examination, with lactated ringer's solution at volume of 300 ml and with tramadol hydrochloride at 4 mg kg<sup>-1</sup>.

Figure 1 - Dog with facial trauma attended at the Veterinary Hospital.



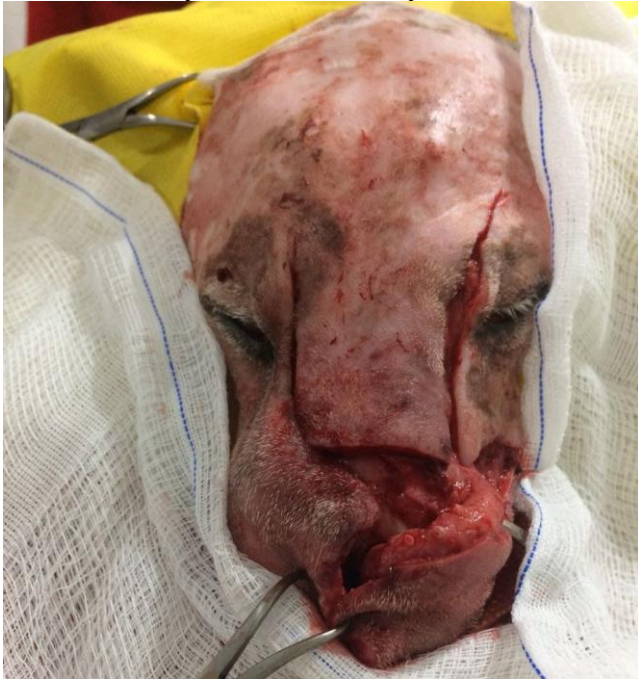Then, a skull x-ray was performed to investigate other lesions, which showed an incomplete simple transverse fracture in the nasal bone, loss of the incisive bone, and fracture of the upper right canine tooth.

After medical evaluation, a first surgical debridement procedure was recommended for the removal of all devitalized tissue and a second surgery for wound repair. Therefore, preoperative complete blood count and serum biochemistry were performed, which showed a slight anemia (red blood cells 4.65 million mm<sup>-3</sup> - Ref. 5.5 - 8.5 million mm<sup>-3</sup>; hematocrit 32% - Ref. 35 - 55%; hemoglobin 10.1 g dL<sup>-1</sup> - Ref. 12 - 18 g dL<sup>-1</sup>; total leukocytes 32,500 mm<sup>3</sup> - Ref. 6,000 - 17,000 mm<sup>3</sup>). Plaquetogram and dosage of serum enzymes (urea, creatinine, aspartate aminotransferase, alanine aminotransferase, and alkaline phosphatase) presented no alterations. A broad-spectrum antibiotic therapy was carried out with amoxicillin and potassium clavulanate (20 mg kg<sup>-1</sup>) every 12 hours and dipyrone (25 mg kg<sup>-1</sup>) every eight hours.

The debridement of the wound with removal of small necrotic areas was performed at the sixth day of treatment, and the first incisor tooth was extracted due to contamination. The animal continued to be medicated with antibiotic plus analgesic (tramadol hydrochloride) at 4 mg kg<sup>-1</sup> every eight hours.

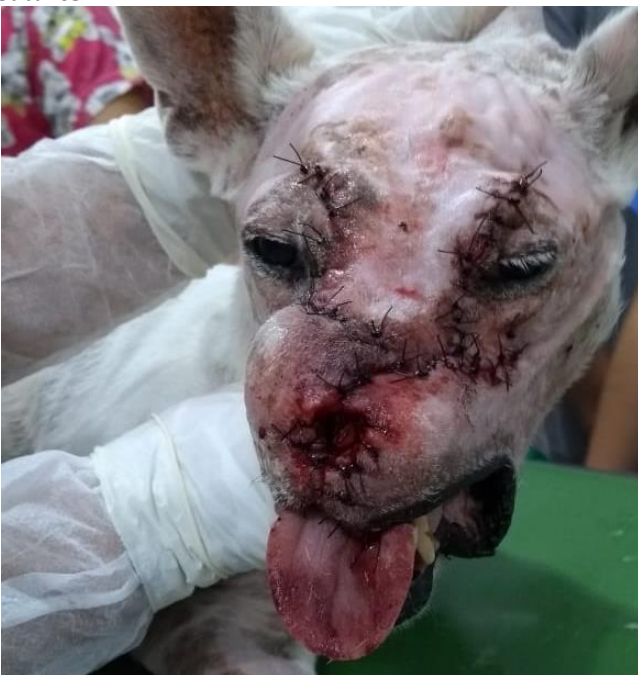On the fourteenth day of treatment, the animal was subjected to reconstructive surgical procedure of the face (Figure 2). The preanesthetic medication consisted of midazolam (0.3 mg kg<sup>-1</sup>, IV), induction with propofol (5 mg kg<sup>-1</sup>, IV), followed by orotracheal intubation and maintenance of anesthesia with isoflurane and oxygen at 100% in an open system without rebreathing.

Figure 2 – Animal during the transoperative, showing the advancement flaps in subcutaneous pattern



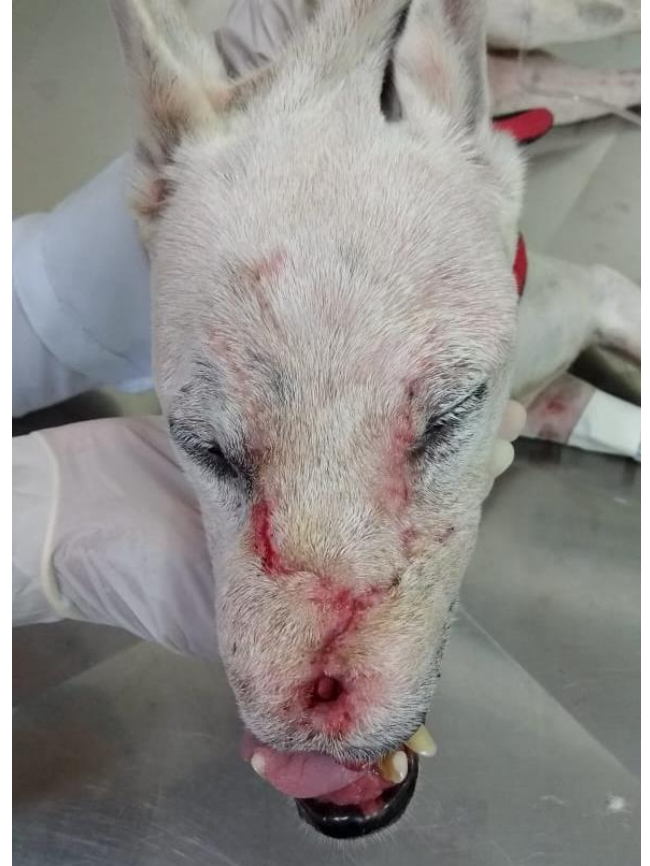After previous antiseptics with 2% chlorhexidine degermant and definitive antiseptics with 0.5% alcoholic chlorhexidine, sterile field cloths were placed. The skin was cut in parallel lines between the eyes until it reached the lesion site, the flap was divulsed enough to cover the lesion without covering the nostrils. Subsequently, the masseter muscles were laterally sectioned on the sides of the face, dividing skin and subcutaneous tissue. An incision was made on the face left side towards the eyeball to better move the flap. Then, the flaps were positioned and skin sutures were made with 2-0 nylon strands in a single, separate pattern (Figure 3).

Figure 3 – Immediate postoperative showing the dermal sutures.



Rifamycin spray every 12 hours for 20 days and tramadol hydrochloride ( $4 \text{ mg kg}^{-1}$ ) was prescribed as postoperative medication. Skin stitches were removed at twenty days of surgery (Figure 4); healing was efficient and the animal was feeding well.

Figure 4 – Removal of stitches and efficient healing of the skin.



## DISCUSSION

Skin lesions in the head and neck regions in small animals are more related to the excision of neoplasia; however, avulsion traumas can also occur, especially in animals with free access to streets (LANNA NETA; SILVEIRA, 2015), as in the case of the present report.

Conservative treatment in face lacerations is usually the first therapeutic option of the Veterinarian. Facial reconstruction techniques are challenging mainly because of the low elasticity of the skin in this region (HUPPES *et al.*, 2016). Therefore, in the case of the present report, the option was the surgical technique of subcutaneous facial advancement flap for wound coverage, since it presents good aesthetic and functional results (COLOMBO *et al.*, 2016; SOUZA *et al.*, 2014).

Reconstructive surgeries are subject to postoperative complications, such as seroma, dehiscence of stitches, infection, edema, and necrosis (PAVLETIC, 2018). Intensive care with bandaging after skin reconstruction should be well developed and performed thoroughly. Colombo *et al.*, (2016) affirm the importance of postoperative bandaging subsequent to an advancement



flap after removal of malignant neoplasia. Fortunately, in the present case, there was dehiscence of only stitch, which did not compromise the wound healing. The wound was not covered due to the difficult handling of the location, however, there were no emergency interurrences that could damage the cicatricial process, such as edema or seroma.

A similar result with subcutaneous advancement flap on a dog face was also discussed by Souza et al. (2014), who described the advancement flap in the frontal region of a boxer bitch after excision of an infundibular cyst. However, different from that reported by these authors, the use of the Bürrow's triangle technique was not necessary in the of the present case report.

According to Pavletic (2018), the occurrence of necrosis in reconstructive surgeries is mainly due to insufficient blood supply, which is directly related to the skin tension lines at the time of the technique execution. Therefore, the base of the flap must have satisfactory width for an appropriate blood supply, which was considered in the procedure described in the present report, denoting that the technique was performed correctly, respecting the face tension lines, which favored the non-appearance of post operation complications.

Surgical debridement is an effective technique for the preparation of the recipient bed in plastic surgeries (WOO *et al.*, 2015). In the present case report, the removal of the necrotic tissue was necessary to minimize the risks of contamination and prepare the area that would receive the flap.

## CONCLUSION

The subcutaneous advancement flap showed to be a good therapeutic alternative for reconstructive repair of skin on the snout of a dog, mainly because this region has difficult cutaneous flexibility, showing an efficient functional and aesthetic result, rehabilitating the animal in routine activities.

## REFERENCES

- COLOMBO, B. B. et al. Reconstrução cirúrgica com retalho pediculado de avanço após exérese de melanoma cutâneo facial em um cão - Relato de caso \*. **Revista Brasileira de Medicina Veterinária**, v. 38, n. 2, p. 128-132, 2016.
- HUPPES, R. R. et al. Retalho de padrão subdérmico após ressecção de nódulos cutâneos em região do crânio de cães e gatos - Relato de caso. **Revista Investigação**, v. 15, n. 7, p. 19-23, 2016.
- LANNA NETA, A. T.; SILVEIRA, D. S. Expectativa De Vida De Cães Errantes Castrados Pelo Projeto De Controle De Natalidade De Cães E Gatos Do Município De Alegre-ES. **Revista de Educação Continuada em Medicina Veterinária e Zootecnia CRMV-SP**, v. 13, p. 79, 2015.
- MOTA, A. K. R. et al. Integração de retalhos de plexo subdérmico para o recobrimento de feridas traumáticas em membros de cães - Avaliação clínica. **Medicina Veterinária**, v. 6, n. 2, p. 10-17, 2012.
- PARGANA, A. M. **Técnicas Reconstructivas Em Cirurgia Oncológica De Canídeos E Felídeos**. [s.l.] UNIVERSIDADE TÉCNICA DE LISBOA, 2009.

PAVLETIC, M. M. **Atlas of Small Animal Wound Management and Reconstructive Surgery**. 4ª ed. Hoboken, NJ: Wiley-Blackwell, 2018.

SCHEFFER, J. P. et al. Cirurgia reconstrutiva no tratamento de feridas traumáticas em pequenos animais. **Revista Brasileira de Medicina Veterinária**, v. 35, n. SUPPL. 1, p. 70-78, 2013.

SOUZA, L. et al. Retalho de avanço associado ao triângulo de bürrow após exérese de cisto infundibular em um cão: relato de caso. **PUBVET**, v. 8, n. 22, 2014.

WOO, K. Y. et al. The cost of wound debridement: a Canadian perspective. **International Wound Journal**, v. 12, p. 402-407. 2015.