



Literature Review

Ultrasound methods used for planning for cataract surgery in dogs

Métodos ultrassonográficos utilizados para o planejamento para a cirurgia de catarata em cães

Thais Guimarães Morato Abreu^{1*} , Marcus Antônio Rossi Feliciano^{2,3} , Ricardo Andres Ramirez Uscategui² , Gabriela Morais Madruga¹ , Ivan Ricardo Martinez Pádua¹ , José Luis Laus¹ 

¹ Department of Surgery Veterinary, UNESP Univ Estadual Paulista, Jaboticabal, São Paulo, Brazil.

² Department of Animal Reproduction UNESP Univ Estadual Paulista, Jaboticabal, São Paulo, Brazil.

³ Sector of Diagnostic Imaging, UFSM Universidade Federal de Santa Maria, Santa Maria, Rio Grande do Sul, Brazil.

ARTICLE INFO

Article history

Received 18 December 2018

Accepted 03 April 2019

Keywords:

Dogs

Doppler

Elastography

Ophthalmology

Ultrasonic biomicroscopy

Palavras-chave:

Cães

Doppler

Elastografia

Oftalmologia

Biomicroscopia ultrassônica

ABSTRACT

Cataract is an important disease on veterinary ophthalmology. Different techniques facilitate the classification of the cataracts, adding information obtained by the conventional eye exam. This review discusses different modalities of ultrasonography methods available for diagnosis and surgical planning in dogs with cataracts. A-Mode ultrasound is used to evaluate thickness and length of the lens. B-Mode also has the capacity to evaluate features of echogenicity, echotexture, position of the lens and the identification of retinal and vitreous degenerations. The ultrasonic biomicroscopy is useful in assessing the anterior capsule and the positioning of the lens. The Doppler method it is useful to detection of vascular changes in patients with cataracts. The elastography method however allows measuring the lens rigidity, which is extremely important for planning and surgical prognosis.

RESUMO

A catarata é considerada importante afecção em oftalmologia veterinária. Diferentes técnicas ultrassonográficas auxiliam na sua classificação das cataratas, complementando informações obtidas ao exame oftálmico convencional. Esta revisão descreve diferentes modalidades ultrassonográficas disponíveis para o auxílio diagnóstico e o planejamento cirúrgico em casos de catarata. A ultrassonografia modo A permite avaliar a espessura e o comprimento da lente. A ultrassonografia modo B permite avaliar características de ecogenicidade, ecotextura, bem como a posição da lente, identificação de descolamentos da retina e degenerações vítreas. A biomicroscopia ultrassônica mostra-se útil na avaliação da cápsula anterior e do posicionamento da lente. O método Doppler, na detecção de alterações vasculares em pacientes com catarata. A elastografia permite a avaliação do grau de rigidez de um tecido, condição importante para o planejamento e prognóstico cirúrgicos.

INTRODUCTION

Cataract is one of the main causes of blindness in dogs, and is a common finding in senile animals (ADKINS; HENDRIX, 2005; GELATT; MACKAY, 2005; PIGATTO et al., 2007; SAFATLE, 2010; SILVA, 2010). Due to the

increase in life expectancy, it affects most animal patients, therefore justifying the study of the condition and its etiology.

Cataracts may be characterized according to: 1) stage: incipient, immature, mature, intumescent, or

* Corresponding author: thaismorato@yahoo.com.br

hypermaturation (PETERSEN-JONES, 2002; DAVIDSON; NELMS, 2007; OFRI, 2013); 2) location: equatorial, nuclear, axial, anterior subcapsular, posterior subcapsular, posterior cortical, posterior polar, peripheral cortical, or lamellar/zonular; 3) development: embryonic, congenital, juvenile, senile, or acquired; 4) pathogenesis: complicated, diabetic, galactosemic, electrical, toxic, post-traumatic, or by radiation; and 5) consistency: fluid, soft, or hard (PETERSEN-JONES, 2002; SLATTER, 2005; DAVIDSON; NELMS 2007). Genetic etiologies are also associated with specific breeds (GELATT; MACKAY, 2005).

The most commonly used classification is according to stage (OFRI, 2013). Incipient cataracts show less than 15% opacity of the lenses, and no visual deficit (OFRI, 2013). Immature cataracts show partial loss of transparency, and visual deficits may be present depending on the affected area (GELATT; WILKIE, 2011). Mature cataracts show completely opaque lenses, with consequent visual deficit (RODRIGUES et al., 2010). Hypermaturation cases show degenerated lenticular fibers, protease release, and protein diffusion through the capsule (GELATT; WILKIE, 2011). Intumescent cataracts show increased lenticular volume and protein loss (OFRI, 2013). In the morgagnian stage, the cortex has liquefied, and the nucleus is solid and isolated (GELATT; WILKIE, 2011).

The volume of canine lenses is of 0.5 mL; the rigidity observed in dogs is similar to that observed in humans (WILLIAMS, 2004; SAMUELSON, 2007; COOK, 2008).

Treatment is exclusively surgical; therefore, diagnosis and staging are crucial for referral and prognosis. Different sonographic techniques make it easier to classify cataracts in dogs, providing complementary information to the conventional ophthalmologic examination by assessing echogenicity, echotexture, and rigidity.

Ocular ultrasounds are one of the most commonly used diagnostic methods; it is a non-invasive, low-cost technique recommended for screening and diagnosis of several ophthalmic conditions, mainly those affecting the posterior segment and the lenses. Ocular ultrasounds are essential for diagnosis, as well as to assess lens position, size, and thickness for surgical planning (FREITAS, 2008; COSTA et al., 2014).

In light of the usefulness of ultrasound techniques in veterinary ophthalmology, this review describes different methods for diagnosis and surgical planning of cataracts in dogs.

OPHTHALMIC ULTRASOUND

In 1956, Mundt; Hughnes published the very first reports on ophthalmic ultrasound (CORRÊA et al., 2002). However, the first reports in veterinary medicine only became available in the 1960s (DZIEZYC et al., 1987; MATTOON; NYLAND, 2015).

Ophthalmic ultrasounds provide information on echogenicity and echotexture as well as on lens thickness, length, and position (BENTLEY et al., 2003; MCMULLEN et al., 2006; LAUS, 2007; HERRERA, 2008; MARTINS et al., 2011). Ophthalmic ultrasounds are useful not only in surgical planning, but also to assess the position of the synthetic lens inserted after phacoemulsification (HERRERA, 2008). Studies on lens thickness in dogs with cataract have been performed (WILLIAMS, 2004; MARTINS et al., 2011).

Ultrasounds are easily accessible and useful in the study of a number of ophthalmic conditions, mainly in cases where transparent media become opaque (BROOKS, 1999; FREITAS, 2008), such as in corneal edema, hyphema, cataracts, and vitreous hemorrhage (DIETRICH; CANTISANI, 2014; KENDALL et al., 2015).

For the exam, the patient is contained in ventral decubitus or sitting position; the patient's skull is stabilized manually. Sedation or general anesthetics are only required in case of acute pain or aggressive behavior (CARVALHO et al., 2015). Under general anesthesia, the extraocular muscles relax, leading to enophthalmos and third eyelid protrusion, thus complicating the exam (GONZALEZ et al., 2001; SPAULDING, 2008). The probe may be placed either directly on the cornea or on the eyelids (transcorneal vs transpalpebral). In the transpalpebral technique, eyelids remain closed and the sterile acoustic gel is applied between the transducer and the eyelid. In the transcorneal technique, there is direct contact between the gel and the cornea; therefore, anesthetic eye drops are required (MCLEOD; RESTORI, 1985; GELATT, 2003; FIELDING, 2004). The transpalpebral technique is less troublesome because the patient cannot see the transducer; however, it shows more artefacts. The transcorneal method allows better assessment of vitreoretinal and retrobulbar structures; also, there is less air between the transducer and the surface (MATTOON; NYLAND, 2015). Regardless of the chosen procedure, eyes should be copiously rinsed afterwards (SPAULDING, 2008).

Probes of 20MHz are the most commonly used in veterinary ophthalmology frequencies range from 15 to 20 MHz (MARTINS et al., 2011). Smaller transducers of sector, micro-convex, or linear types are preferable. Some devices require fluid offset or stand-off pads to prevent air bubbles, especially in fixed-focus beams. The increased distance between the transducer and the cornea allow the clinician to better visualize the cornea, anterior chamber, and lens. However, the posterior segment is more easily assessed if the cornea is in close contact with the transducer. It is important to highlight that low-frequency transducers are associated with less detailed images of the bulb, and higher-frequency transducers are more often used to assess the anterior segment of the eye (SCHMIDT, 2010).

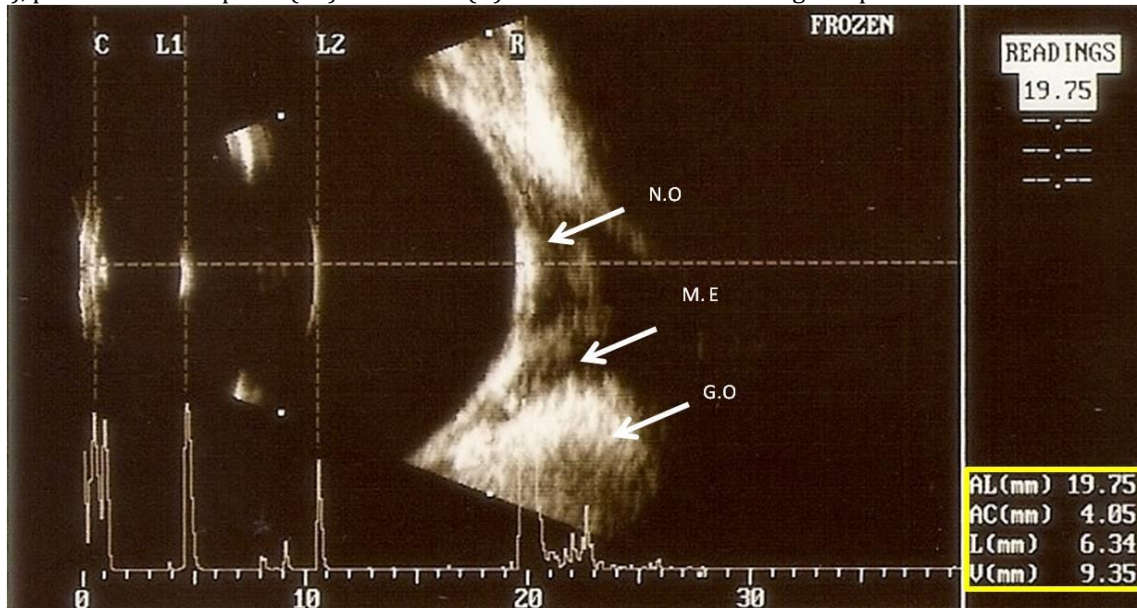
AMPLITUDE MODE ULTRASOUND (A-MODE)

Amplitude mode ultrasounds (A-mode) assess the axial dimensions of the eye bulb (TUNTIVANICH et al., 2007). Results are presented in a two-dimensional graph, allowing clinicians to assess acoustic impedance based on peak heights. Until recently, the use of A-mode ultrasounds in veterinary medicine was more restricted

to teaching and research institutions (GONZALEZ et al., 2001; MATTOON; NYLAND, 2015).

In A-mode, higher amplitudes are associated with epithelial and endothelial areas of the cornea, anterior and posterior capsules of the lenses, and retina-choroid-sclera complexes. In healthy patients, bidimensional ultrasounds (B-mode) show anechogenic anterior and posterior chambers, vitreous chambers, and interior of the lenses; in A-mode, no peaks are observed (Figure 1).

Figure 1 – Normal dog eye ultrasound, in modes A and B, with 20 MHz probe, illustrates the biometry of the eye bulb (yellow frame) of a Shih-Tzu adult individual. Note the wave amplitude patterns in the corneal (C) mode, anterior lens capsule (L1), posterior lens capsule (L2) and retina (R). Note in B mode the echogenic patterns of the different structures.



Studies on the standardization process of ocular biometrics in different species are already available (GONÇALVES et al., 2009; TONI et al., 2010; KOBASHIGAWA et al., 2015). The assessment of intraocular lens thickness and length within specific breeds and among individuals has been useful for research purposes in clinical practice, these variables are important for surgical planning of intraocular lens implant in dogs submitted to phacoemulsification (GAIDDON et al., 1991).

Even though bidimensional ultrasounds (B-mode) are also useful to measure eye structures. Sometimes operators may find it difficult to determine the axes and distinguish the anatomical limits of the structures. That does not happen in A-mode, which is more objective. Studies showed that the difference between the axial measures acquired by both methods is not statistically significant; both are equally accurate for the biometric assessment of eye bulb structures (COTTRILL et al., 1989; HAMIDZADA; OSUOBENI, 1999).

It is known that lenses thicken with age, both in humans and in dogs (PERKINS, 1988; HOFFER, 1993; WILLIAMS, 2004). Studies on lens size variability in dogs with different stages of cataract highlight the importance of

the technique, especially for surgical planning. Mature and intumescent cataracts lead to an increase in lenticular thickness, very often reducing the anterior chamber and narrowing the iridocorneal angle. These changes predispose to increased intraocular pressure. Therefore, the periodical assessment of intraocular pressure is recommended for patients with intumescent or mature cataracts (WILLIAMS, 2004).

In A-mode, patients with cataracts show peaks inside the lens depending on the stage of the condition (Figure 2).

BIDIMENSIONAL ULTRASOUND (B-MODE)

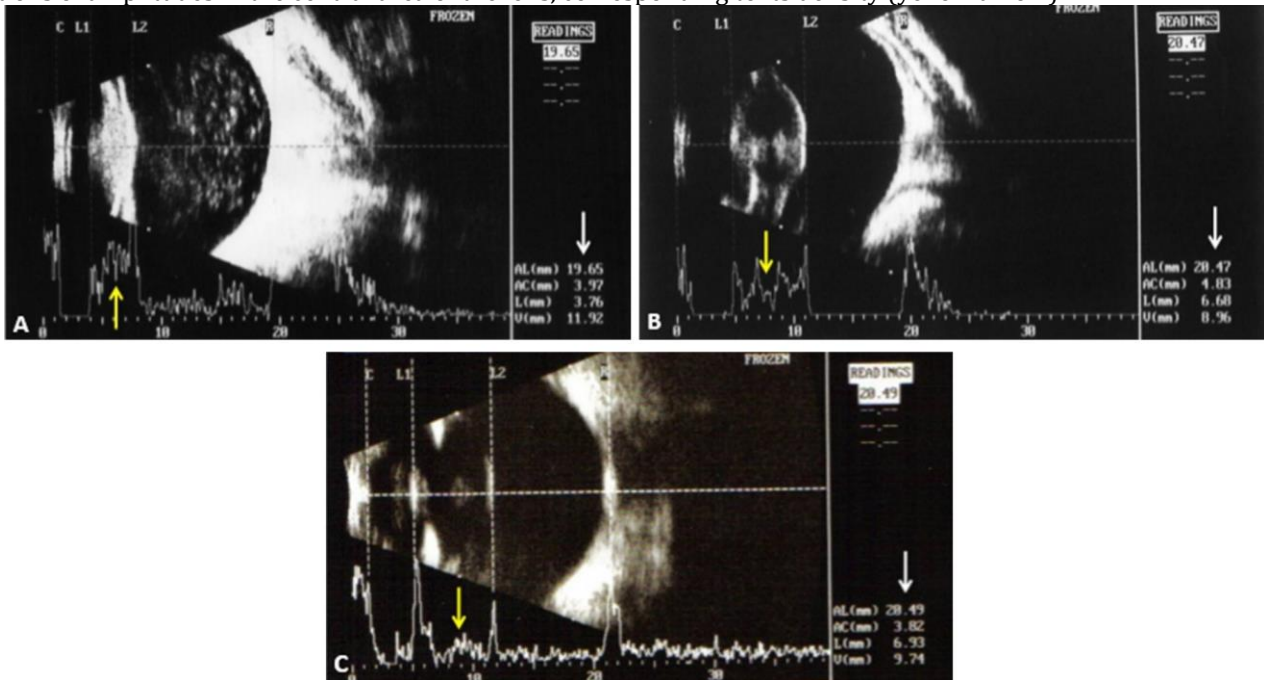Bidimensional ultrasound (B-mode) is commonly used in clinical practice. It provides different echotexture and echogenicity patterns according to the degree of acoustic impedance (BENTLEY et al., 2003; MATTOON ; NYLAND, 2015), as well as information on the position of cataractous lenses (GAIDDON et al., 1991; MOLGAT et al., 1993; BENTLEY et al., 2003; SQUARZONI et al., 2007). B-mode ultrasounds also identify retinal detachment and vitreous degeneration (LABRUYERE et al. 2008; PARK et al., 2015), which influence the decision-making process for surgical treatment (KUBAL, 2008; RAYMOND et al., 2009; WHANG et al., 2012). Additionally, B-mode

ultrasounds measure lens thickness and length, allowing clinicians to choose the right size of artificial substitutes (BRANDÃO et al., 2007; LUYET et al., 2008; BARBÉ et al., 2017).

In B-mode, healthy dogs show anechogenic lenses. Anterior and posterior capsules are convex and concave,

respectively, and both lenses are hyperechogenic and thin. The retina-choroid-sclera complex also appears hyperechogenic (MCNICHOLAS et al., 1994; HERRERA, 2008).

Figure 2 – Ultrasound image, with 20 MHz probe, in modes A and B, of eyes of dogs with cataract at different evolutionary stages. (A) Hypermature cataract, showing reduction of lens size and presence of hyperechoic points in the vitreous camera compatible with degeneration of the vitreous. (B) Mature cataract, showing increased hyperechogenicity of the capsule, cortex and central core area. (C) Immature cataract, showing an increase in the hyperechogenicity of the anterior and posterior capsules, as well as of the nucleus. Peaks correspond to each structure, biometric values (white arrow), and variations of amplitudes in the central area of the lens, corresponding to its density (yellow arrow).



The echogenicity of lens contents varies according to stage – incipient, immature, mature, or hypermature. In cortical cataracts, the anterior cortex is hyperechogenic. Intumescent cataracts are not a rare finding in diabetic patients; changes in glucose metabolism lead to an increase in aqueous flow into the lens, therefore forming vacuoles; B-mode ultrasounds show lentiglobus (BRAZITIKOS et al., 1999; WILLIAMS, 2004). Therefore, lenses tend to be bigger in size in intumescent cataracts when compared to other stages, even leading to shallower anterior chambers and capsule rupture (WILLIAMS, 2004). Immature cataracts show thinner lenses due to the outflow of soluble materials (LAURSEN; FLEDELIUS 1979; PERKINS, 1988).

Studies on lens thickness in dogs with different stages of cataract have led to different results. Martins et al. (2011) report no difference in lens axial length when comparing mature and immature cataracts, WILLIAMS (2004) observed significant increase in lens thickness in mature cataracts.

More advanced stages, notably hypermature and morgagnian cataracts, show irregular capsule surface

and reduced lenticular thickness, leading to deeper anterior chambers. Besides, the more mature the cataract, the higher the weight in lenticular zonules; consequently, displacements are more likely to happen. In subluxated lenses, the signs of longitudinal or transversal misalignments leading to changes in anterior chamber depths are mild. These findings are more prominent in full displacements. In anterior displacements, the anterior chamber becomes shallower and the anterior capsule of the lens is immediately posterior to the cornea. In posterior displacements, the lens is observed in the vitreous chamber as a spherical mass that moves freely next to the retina (WILLIAMS, 2004).

ULTRASOUND BIOMICROSCOPY

This technique is often common in ophthalmology and is characterized by high-frequency transducers (35, 50 and 100 MHz) yielding high-resolution images, mainly of microscopic structures (20 to 80 μ m) (HEWICK et al., 2014). Because the penetration of sound waves is limited to 5 to 10 mm, this method is more often used to assess the anterior segment of the eye (cornea, anterior

chamber, sclerocorneal junction, iridocorneal angle, iris, anterior and posterior chambers, and anterior capsule of the lens) (ISHIKAWA; SCHUMAN, 2004).

Ultrasound biomicroscopy has been used for early diagnosis of closed angle glaucoma, ciliary body effusion syndrome, and lens displacement, as well as to identify ciliary body cysts and tumors. It is also used to study the position of intraocular lens haptics. In the study of uveitis, supraciliary effusion and cyclic membranes can be observed (BHATT, 2014).

Capsular irregularities observed in advanced cataracts, added to the low image resolution in the area where the anterior and posterior capsules meet, make ultrasound biomicroscopy unreliable for length assessment. A 35 MHz transducer has recently been used to assess its reproductivity and repeatability to measure equatorial length for surgical planning in phacoemulsification in dogs; the anterior segment was represented by one single image, allowing accurate, high-resolution assessments of the margins of the lenticular capsules, therefore accurately measuring their lengths (BARBÉ et al., 2017).

DOPPLER

Doppler ultrasounds provide information on the vascular aspects of organic tissues, allowing clinicians to assess the presence and direction of blood flow, as well as systolic velocity and resistive and pulsatility indices. This technique is always associated with B-mode images. It has proven useful to diagnose vascular changes and to monitor patients with ocular hypertension or neoplasia, as well as to study the effects of glaucoma medications in the ophthalmic artery flow (CHOI et al., 2011).

This technique assesses systolic and diastolic velocities in the arterial flow. The vascular resistance index and perfusion are inversely correlated; higher resistance rates are associated with lower blood perfusion. It is important to highlight that the pressure applied by the transducer affects test results; therefore, operators must be trained in order to minimize potential bias. In order to ensure exam quality, patients are usually chemically restrained. If patients are agitated, blood flow will be affected by stress (FELICIANO et al., 2013).

The key vessels to be assessed in ophthalmology are the following: ophthalmic, posterior ciliary, long and short ciliary, and primary retinal arteries (NOVELLAS et al., 2007). Vascular patterns may be affected by systemic conditions associated with secondary ophthalmic manifestations, notably in diabetic and hypertensive patients; however, the same can be observed in primary ophthalmic conditions, such as glaucoma, progressive retinal atrophy, and intraocular neoplasias (RANKIN, 1999; GONZALEZ et al., 2001).

Feliciano et al. (2013) assessed the vascular patterns of 10 poodles affected by cataracts with Triplex Doppler and a 13 MHz transducer. Laminar flow was observed in all patients but one. This technique showed that vascular patterns were affected in dogs with cataracts and that, although resistance indices were stable (mean 0.76), pulsatility indices were increased (mean 1.79) when compared to the healthy dogs studied by NOVELLAS et al. (2007), which showed mean resistivity of 0.76 and mean pulsatility of 1.68.

ELASTOGRAPHY

Elastography provides information on echogenicity, echotexture, and dimensions as well as tissue levels of rigidity, which are crucial for the biomechanic study of tissues when palpation is not feasible (KONOFAGOU, 2004). The exam is safe and provides real-time information without chemical restraint (COMSTOCK, 2011).

Elastography is based on the principle of elasticity, assessing tissue rigidity according to its degree of deformation after mechanical compression. When compression is interrupted, tissues return to their previous size and shape; therefore, the higher the deformation, the lower the rigidity (DUDEA et al., 2011; BAMBER et al., 2013; BHARGAVA et al., 2013; CUI et al., 2013; BARR et al., 2015; KAY; PEPIN 2015; SHIINA et al., 2015).

Elastographic methods are classified as dynamic or static (TREECE et al., 2011; BAMBER et al., 2013). Dynamic elastography provides quantitative information on tissue rigidity based on shear velocity; static elastography assesses tissue rigidity based on the elastogram, where different colors represent different degrees of rigidity. In quantitative elastography, rigidity is proportional to the shear velocity detected by the equipment (BATHIA et al., 2012).

One study in dogs used qualitative Acoustic Radiation Force Impulse (ARFI) Elastography, where lighter and darker shades of grey represent lower and higher rigidity, respectively. In healthy lenses, ARFI elastography showed mosaic patterns consisting of a combination of lighter and darker shades. The same study observed high rigidity in lenticular capsules, shown in dark grey (Figure 3). ARFI elastography also showed loss of mosaic patterns in dogs with different degrees of cataract (Figure 4) (ABREU et al., 2018).

Figure 3 – Ultrasonographic images mode B (A and C) and elastogram in different shades of gray. (B and D), showing lens, ciliary body, vitreous humor (A and B) and fundus of eye (C and D), of eye of the Shih Tzu dog breed. The optic nerve (white arrows) is homogeneous and hyperechoic in B mode, and of medium gray to the elastogram. The vitreous humor (H.V) is anechoic in mode B, with black and light gray (mosaic) regions on the elastogram. The anterior and posterior capsules of the lens (*) are shown as hyperechogenic curvilinear structures in B mode and in a homogeneous pattern of dark gray tonality to the elastogram. The interior of the lens (L) is anechoic to mode B and heterogeneous (mosaic), consisting of black and light gray regions, to the elastogram. The ciliary body (yellow arrows) is homogeneous, with a slight hyperechogenicity to the B mode, and a medium gray tone to the elastogram.

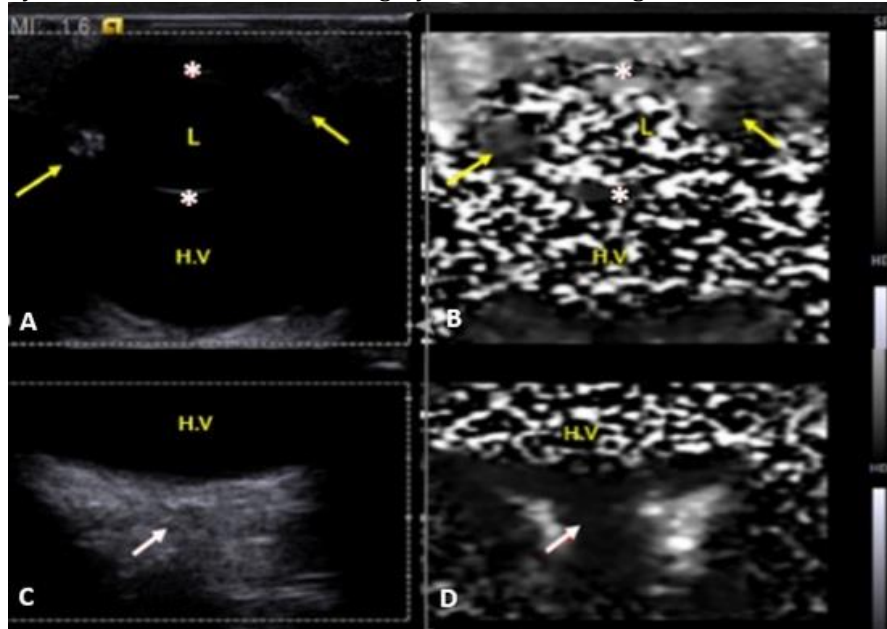
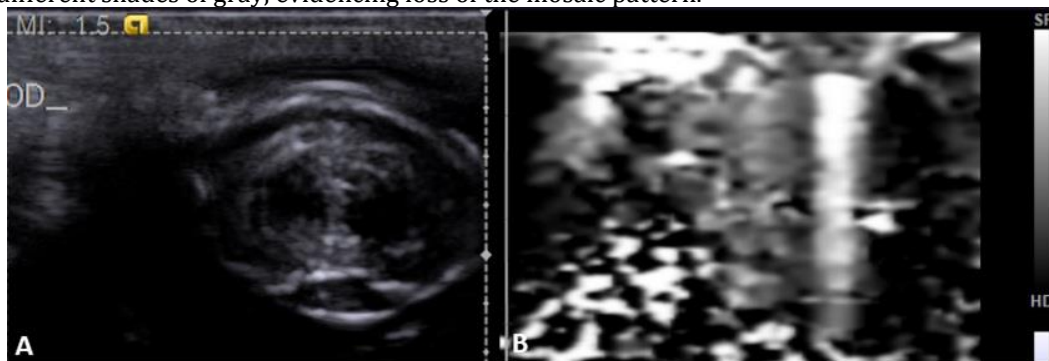


Figure 4 – Ultrasonographic images of canine lenses with mature cataract: A - evaluation of the lens in two-dimensional mode, showing hyperechogenicity of capsule, cortex and central area of the nucleus; B - evaluation of the lens to the elastogram in different shades of gray, evidencing loss of the mosaic pattern.



FINAL CONSIDERATIONS

Besides complementing diagnosis, ultrasound techniques have become essential for surgical planning in patients with cataract; they allow surgeons to assess lens echogenicity, echotexture, and biometrics, as well as lens rigidity and the effects of the condition on vascular parameters, providing useful information for prognosis. This review offers pertinent information that may assist specialists in the assessment of patients with cataract.

CONFLICTS OF INTEREST

None of the authors of this article has a financial or personal relationship with other people or organizations

that could inappropriately influence or bias the content of the paper.

ACKNOWLEDGMENTS

The authors thank CNPq (process 141007/2017-6) and FAPESP (processes 2012/16635-2) for an operating research grant and a young researcher scholarship.

REFERENCES

- ABREU, T. G. M. et al. Acoustic Radiation Force Impulse elastography of the eyes of brachycephalic dog. *Arquivo Brasileiro de Medicina Veterinária e Zootecnia*, v. 70, n. 4, p.1045-1052, 2018.
- ADKINS, E.A.; HENDRIX, D.V. Outcomes of dogs presented for cataract evaluation: A retrospective study. *Journal of the American Hospital Association*, v. 41, n. 4, p.235-240, 2005.

- BAMBER, J. et al. EFSUMB guidelines and recommendations on the clinical use of ultrasound elastography. Part 1: Basic principles and technology. **Ultraschall in der Medizin**, v. 34, n. 2, p.169-184, 2013.
- BARR, R.G. et al. WFUMB guidelines and recommendations for clinical use of ultrasound elastography: Part 2: Breast. **Ultrasound in Medicine and Biology**, v. 41, n. 5, p. 1148-1160, 2015.
- BARBÉ, C.; HARRAN, N. GOULLE, F. Intra- and interobserver reliability of lens equatorial length measurement using 35-MHz ultrasound biomicroscopy in dogs with cataract. **Veterinary Ophthalmology**, n. 20, v. 4, p.329-334, 2017.
- BENTLEY, E.; MILLER, P. E.; DIEHL, K. A. Use of high-resolution ultrasound as a diagnostic tool in veterinary ophthalmology. **Journal of the American Veterinary Medical Association**, n. 223, v. 11, p.1617-1622, 2003.
- BHARGAVA, S. et al. Elastography: A new imaging technique and its application. **Journal of International Medical Science Academy**, v. 26, n. 1, p.25-30, 2013.
- BHATT, D.C. Ultrasound biomicroscopy: An overview. **Journal of Clinical Ophthalmology and Research**, v. 2, n. 2, p.115-23, 2014.
- BRANDÃO, C. V. S. et al. Tonometria, paquimetria e comprimento axial ocular em cães glaucomatosos submetidos à ablação uveal intravítrea. **Arquivos Brasileiros de Medicina Veterinária e Zootecnia**, 59:914-919, 2007.
- BRAZITIKOS, P. D. et al. Ultrasonographic classification and phacoemulsification of white senile cataracts. **Ophthalmology**, v. 106, n. 11, p.2178-2183, 1999.
- BROOKS, D.E. Ocular imaging. In: GELATT, K.N. **Veterinary ophthalmology**. 3. ed. Baltimore: Williams ; Wilkins, 1999. p. 47-476.
- CARVALHO, C.F.; CINTRA, T.C.F. CHAMMAS, M. C. Elastography principle and considerations for clinical research in veterinary medicine cibe. **Journal of Veterinary Medicine and Animal Health**; v. 7, n. 3, p.99-110, 2015.
- CHOI, H. et al. EFFECTS of anti-glaucoma drugs on resistive index of the medial long posterior ciliary artery using color Doppler imaging in Beagle dogs. **Journal of Veterinary Science**, v. 12, n. 1, p.99-101, 2011.
- COMSTOCK, C. Ultrasound elastography of breast lesions. **Ultrasound Clinics**, v.6, n. 3, p.407-415, 2011.
- COOK, C. Canine cataract surgery. **Cataract & Refractive Surgery Today**, p.32-34, 2008.
- CORRÊA, Z. M. S. et al. Achados ecográficos em pacientes com catarata total. **Arquivos Brasileiros de Oftalmologia**, v. 65, n. 6, p.609-613, 2002.
- COSTA, A. P. A. et al. Ultrassonografia ocular em cães. **Enciclopédia Biosfera**, v. 10, n. 18, p.2905, 2014.
- COTTRILL, N. B.; BANKS, W. J.; PECHMAN, R. D. Ultrasonographic and biometric evaluation of the eye and orbit of dogs. **American Journal of Veterinary Research**, v. 50, n. 6, p.898-903, 1989.
- CUI, X. W.; JENSSSEN, C. New ultrasound techniques for lymph node evaluation. **World Journal of Gastroenterology**, v. 19, n. 30, p.4850-4860, 2013.
- DAVIDSON, M. G.; NELMS, S. R. Diseases of the canine lens and cataract formation. In: GELATT, K. N. **Veterinary Ophthalmology**, 4 ed. Ames: Blackwell Publishing, 2007. p. 859-887.
- DIETRICH, C. F.; CANTISANI, V. Current status and perspectives of elastography. **European Journal Radiology**, v. 83, n. 3, p.403-404, 2014.
- DUDEA, S. M. et al. VALUE OF ULTRASOUND ELASTOGRAPHY IN THE DIAGNOSIS AND MANAGEMENT of prostate carcinoma. **Medical Ultrasonography**, v. 13, n. 1, p.45-53, 2011.
- DZIEZYC, J. et al. Two-dimensional real-time ocular ultrasonography in the diagnosis of ocular lesions in dogs. **Journal of the American Animal Hospital Association**, v. 28, n. 2, p.60-65, 1987.
- FELICIANO, M. A. R. et al. Contribuição diagnóstica da ultrassonografia ocular e Doppler Triplex na avaliação de 10 cães Poodle com catarata. **Arquivo Brasileiro de Medicina Veterinária e Zootecnia**, v. 65, n. 2, p.359-363, 2013.
- FIELDING, J. A. The assessment of ocular injury by ultrasound. **Clinical Radiology**, v. 59, n. 4, p.301-3012, 2004.
- FREITAS, A. C. Ultra-sonografia oftálmica em cães (*Canis familiaris*) portadores de diabetes mellitus. **Jornal Brasileiro de Ciência Animal**, v. 1, n. 1, 2008.
- GELATT, K. N.; MACKAY, E. O. Prevalence of primary breed-related cataracts in the dog in North America. **Veterinary Ophthalmology**, v. 8, n. 2, p.101-111, 2005.
- GELATT, K. N.; WILKIE, D. A. Surgical procedures of the lens and cataract. In: GELATT, K. N.; GELATT, J. P. **Veterinary Ophthalmic Surgery**. Oxford: Saunders Elsevier, 2011. p. 305-352.
- GELATT, K. N. **Manual de oftalmologia veterinária**. 3. ed. São Paulo: Manole, 2003. p. 227-252.
- GONÇALVES, G. F. et al. Biometria ultrassonográfica bidimensional em tempo real de bulbo ocular de gatos domésticos. **Ciência Animal Brasileira**, v. 10, n. 6, p.829-834, 2009.
- GONZALEZ, E. M.; RODRIGUEZ, A.; GARCIA, I. Review of ocular ultrasonography. **Veterinary Radiology & Ultrasound**, v. 42, n. 6, p.485-495, 2001.
- HAMIDZADA, W. A.; OSUOBENI, E. P. Agreement between A-mode and B-mode ultrasonography in the measurement of ocular distances. **Veterinary Radiology & Ultrasound**, v. 40, n. 5, p.52-57, 1999.
- HERRERA, D. **Oftalmologia clínica em animais de companhia**. São Paulo: MetVet Livros, 2008. p. 117-122.
- HEWICK, S. A. et al. A comparison of 10 MHz and 20 MHz ultrasound probes in imaging the eye and orbit. **British Journal of Ophthalmology**, v. 88, n. 4, p.551-555, 2004.
- HOFFER, K. J. Axial dimension of the human cataractous lens. **Archives of Ophthalmology**, v. 111, n. 7, p.914-918, 1993.
- ISHIKAWA, H.; SCHUMAN, J. S. Anterior segment imaging: ultrasound biomicroscopy. **Ophthalmology Clinics of North America**, v. 17, n. 1, p.7-20, 2004.
- KAY, M.; PEPIN, A. Magnetic resonance elastography (MRE) in cancer: Technique, analysis, and applications. **Progress in Nuclear Magnetic Resonance Spectroscopy**, v. 90, p. 32-48, 2015.
- KENDALL, C. J. et al. Diagnostic Ophthalmic Ultrasound for Radiologists. **Neuroimaging Clinics of North America**, v. 25, n. 3, p.327-365, 2015.
- KOBASHIGAWA, K. K. et al. Parâmetros oftálmicos em cães adultos da raça Shih Tzu. **Ciência Rural**, v. 45, n. 7, 2015.
- KUBAL, W. S. Imaging of orbital trauma. **Radiographics**, v. 28, n. 6, p.1729-1739, 2008.
- KONOFAGOU, E. E. Quo vadis elasticity imaging? **Ultrasonics**; v. 42, n. 1-9, p.331-336, 2004.
- LABRUYERE, J. J. et al. Ultrasonographic evaluation of vitreous degeneration in normal dogs. **Veterinary Radiology & Ultrasound**, v. 49, n. 2, p.165-171, 2008.

- LAURSEN, A. B.; FLEDELIUS, H. Variations of lens thickness in relation to biomicroscopic types of human senile cataract. **Acta Ophthalmologica**, v. 57, n. 1, p.1-13, 1979.
- LAUS, J. L. *Oftalmologia Clínica e Cirúrgica em Cães e Gatos*. São Paulo: Roca, 2007. p. 116-133.
- LUYET, C. et al. Real time visualization of ultrasound-guided retrobulbar blockade: an imaging study. **British Journal of Anesthesia**, v. 101, n. 6, p.855-859, 2008.
- MARTINS, B. C. et al. Ultrasonographic analysis of senile cataractous lens of dogs and its correlation to phacoemulsification. **Arquivo Brasileiro de Medicina Veterinária e Zootecnia**, v. 63, n. 5, 2011.
- MATTOON, J. S.; NYLAND, T. G. *Small animal diagnostic ultrasound*. 3. ed. St. Louis: Copyright Elsevier Saunders, 2015. p. 130-131.
- MCLEOD, D.; RESTORI, M. Rapid B-scanning in ophthalmology. In: Barnett E, Morley P. **Clinical diagnostic ultrasound**. Oxford: Blackwell Scientific Publications, 1985. p. 111-20.
- MCMULLEN, R. J. et al. Keratometry, biometry and prediction of intraocular lens power in the equine eye. **Veterinary Ophthalmology**, v. 9, n. 5, p.357-360, 2006.
- MCNICHOLAS, M. M. J.; BROPHY, D .P. et al. Ocular sonography. **American Journal of Roentgenology**, v. 163, n. 4, p.921-926, 1994.
- MOLGAT, Y.M.; PAVLIN, C.J.; HURWITZ, J. J. Ultrasound biomicroscopy as a diagnostic tool in space-occupying lesions of the superotemporal conjunctival fornix. **Orbit**, v. 12, n. 3, p.121-126, 1993.
- MUNDT, G. H.; HUGHES, W. F. Ultrasonics in ocular diagnosis. **American Journal of Ophthalmology**, v. 41, n. 3, p.488-498, 1956.
- NOVELLAS, R.; ESPADA, Y.; GOPEGUI, R. R. Doppler ultrasonographic estimation of renal and ocular resistive and pulsatility indices in normal dogs and cats. **Veterinary Radiology & Ultrasound**, v. 48, n. 1, p.69-73, 2007.
- OFRI, R. Lens. In: MAGGS, D.J.; MILLER, P.E. et al. **Slatter's Fundamentals of Veterinary Ophthalmology**. 5ed. Missouri: Elsevier, 2013. p. 272-290.
- PARK, Y. W. et al. Retrospective study on the association between vitreous degeneration and cataract in dogs. **Veterinary Ophthalmology**, v. 18, n. 4, p.304-308, 2015.
- PETERSEN-JONES, S. The lens. In: Petersen-Jones S, Crispin S. **BSAVA Manual of Small Animal Ophthalmology**, 2 ed. Barcelona: Small Animal Veterinary Association, 2002. p. 204-218.
- PERKINS, E. S. Lens thickness in early cataract. **British Journal of Ophthalmology**, v. 72, n. 5, p.348-353, 1988.
- PIGATTO, J. A. T. et al. Avanços e benefícios da facoemulsificação. **Acta Scientiae Veterinariae**, v. 35, p.248-249, 2007.
- RANKIN, S. J. Color Doppler imaging of the retrobulbar circulation in glaucoma. **Survey of Ophthalmology**, v. 43, n 1, p.176-182, 1999.
- RAYMOND, S.; FAVILLA, I.; SANTAMARIA, L. Comparing ultrasound biometry with partial coherence interferometry for intraocular lens power calculations: a randomized study. **Investigative Ophthalmology Visual Science**, v. 50, p.2547-52, 2009.
- RODRIGUES, G. N. et al. Facoemulsificação em cães, com e sem implante de lente intra-ocular em piggyback: estudo clínico da inflamação pós-operatória. **Pesquisa Veterinária Brasileira**, v. 30, n. 2, p.103-107, 2010.
- SAFATLE, A. Importância do eletrorretinograma de campo total (Fullfield ERG) em cães da raça Cocker Spaniel Inglês portadores de catarata. **Pesquisa Veterinária Brasileira**, v. 30, n. 2, p.149-154, 2010.
- SAMUELSON, D. A. Ophthalmic anatomy. In: GELATT, K.N. **Veterinary Ophthalmology**, 4 ed. Iowa: Blackwell Publishing; 2007. p. 37-148.
- SCHMIDT, V. Ultrassonografia ocular e orbitária. In: MANNION, P. **Ultrassonografia de pequenos animais**. Rio de Janeiro: Revinter, 2010. p. 278-300.
- SHIINA, T. et al. WFUMB guidelines and recommendations for clinical use of ultrasound elastography: Part 1: Basic principles and terminology. **Ultrasound in Medicine and Biology**, v. 41, n. 5, p.1126-1147, 2015.
- SILVA, T. M. F. Catarata em cães: Revisão de literatura. **PUBVET**, v. 4, n. 2, p.717-722, 2010.
- SLATTER, D. Técnicas básicas de diagnóstico. In: SLATTER, D. **Fundamentos de Oftalmologia Veterinária**. 3 ed. São Paulo: ROCA, 2005. p.125-126.
- SPAULDING, K. Eye and orbit. In: PENNINGCK, D.; D'ANJOU, M. **Atlas of small animal ultrasonography**. Iowa: Blackwell Publishing, 2008. p.49-90.
- SQUARZONI, R. et al. Ultrasonographic evaluation of the eyes' posterior segment of diabetic and non-diabetic dogs with cataracts. **Pesquisa Veterinária Brasileira**, v. 27, n. 11, p.455-461, 2007.
- TONI, M. C. et al. Rabbits' eye globe sonographic biometry. **Veterinary Ophthalmology**, v. 13, n. 6, p.384-386, 2010.
- TREECE, G. et al. Real-time quasi-static ultrasound elastography. **Interface focus**, v. 1, n. 4, p.540-552, 2011.
- TUNTIVANICH, N. et al. Posnatal development of canine axial globe length measured by B-scan ultrasonography. **Veterinary Ophthalmology**, v. 10, n. 1, p.2-5, 2007.
- GAIDDON, J. et al. Use of biometry and keratometry for determining optimal power for intraocular lens implants in dogs. **American Journal Veterinary Research**, v. 52, n. 5, p.781-783, 1991.
- WHANG, W. J. et al. Comparison of postoperative refractive outcomes: IOLMaster® versus immersion ultrasound. **Ophthalmic Surgery, Lasers and Imaging**, 43:496-9, 2012.
- WILLIAMS, D. L. Lens morphometry determined by B-mode ultrasonography of the normal and cataractous canine lens. **Veterinary Ophthalmology**, v. 7, n. 2, p.91-95, 2004.