








Case Report

## Surgical treatment of intestinal obstruction by fecaloma in a puma (*Puma concolor*)

Tratamento cirúrgico da obstrução intestinal por fecaloma em um puma (*Puma concolor*)

Marcos Vinícius de Souza<sup>1\*</sup> , Yuri Amaral Teixeira Dias Coelho<sup>2</sup> , Ana Maria Quessada<sup>3</sup> , José Ricardo Pachaly<sup>4</sup> , Núbia Estéfane Gomes Botelho<sup>5</sup> 

<sup>1</sup> Prof. Dr. Docente do Curso de Graduação em Medicina Veterinária e Medicina no Centro Universitário UNIFACIG. R. Darcy César de Oliveira Leite, 600, Alfa Sul, Manhuaçu, MG, 36904-219, Brasil.

<sup>2</sup> Médico Veterinário Autônomo, Rua Américo Macedo, número 789, apartamento 302, Gutierrez, Belo Horizonte – MG, 30441-102

<sup>3</sup> Profa. Dra. Docente do Curso de Graduação em Medicina Veterinária da Universidade e Programa de Pós-graduação em Ciência Animal com Ênfase em Produtos Bioativos, Universidade Paranaense (UNIPAR), Praça Mascarenhas de Moraes, 4282, Centro, Umuarama, 87502-100, PR, Brasil.

<sup>4</sup> Prof. Dr. Diretor Científico do Instituto Brasileiro de Especialidades em Medicina Veterinária – ESPECIALVET. Rua Lopes Trovão, 250 - Zona 4, Maringá, PR, 87014-080, Brasil.

<sup>5</sup> Discente do curso de Medicina Veterinária no Centro Universitário UNIFACIG. R. Darcy César de Oliveira Leite, 600, Alfa Sul, Manhuaçu, MG, 36904-210, Brasil.

### ARTICLE INFO

#### Article history

Received 28 June 2019

Accepted 03 December 2019

#### Keywords:

Wild animals

Felids

Surgery

Diet

Intestinal obstruction

#### Palavras-chave:

Animais selvagens

Felinos

Cirurgia

Dieta

Obstrução intestinal

### ABSTRACT

The puma (*Puma concolor*) is a large felid native to the Americas and one of the endangered species of the Brazilian fauna. Digestive disorders such as fecalomas are common in veterinary practice. Fecalomas are masses of retained feces that accumulate in the large colon and progress to hard fecal concretions that are difficult and painful to expel. Inadequate diets and mechanical intraluminal or extraluminal intestinal obstructions are the major causes of fecaloma. Tenesmus, anorexia, vomiting and dehydration are common clinical signs. The diagnosis is based on medical history and physical examination, and can be confirmed by imaging assessment. Fecalomas are amenable to conservative and surgical treatment, depending on disease severity. This paper describes a case of fecaloma in a puma. The diagnosis was made during exploratory laparotomy and improper diet incriminated as the cause. Surgical intervention consisted of enterotomy followed by removal hardened retained feces. Postoperative dietary management consisted of a liquid follow by a soft diet, with reintroduction of the regular diet after full recovery. Dietary supplementation with vegetable fibers was prescribed for life to prevent recurrence.

### RESUMO

O puma (*Puma concolor*), também conhecido como onça-parda ou suçuarana, é um grande felídeo carnívoro exclusivo das Américas, e uma das espécies da fauna brasileira ameaçadas de extinção. As alterações do sistema digestório são comuns na prática clínica veterinária e dentre essas se encontram os fecalomas, massas de fezes retidas no cólon que se tornam concreções fecais difíceis e dolorosas de expulsar. As principais causas são dietas inadequadas, bem como distúrbios de pelve associados a osteopatias metabólicas ou traumas. Os sinais clínicos são tenesmo, anorexia, vômitos e desidratação. O diagnóstico é baseado em anamnese e exame físico, sendo confirmado por exames de imagem. O tratamento pode ser médico ou cirúrgico, dependendo da apresentação clínica. Este artigo relata o caso de um puma que apresentou fecalomas em função de dieta inadequada, sendo que o diagnóstico foi feito por meio de laparotomia exploratória. O ato cirúrgico progrediu para realização de enterotomia e remoção das fezes retidas, que se apresentaram bastante endurecidas. Após a cirurgia, o paciente recebeu dieta líquida e posteriormente pastosa, e apresentou recuperação completa. Para prevenção de recidivas indicou-se correção dietética com adição permanente de fibras vegetais à alimentação.

\* Corresponding author: [mvscardoso@yahoo.com.br](mailto:mvscardoso@yahoo.com.br)

## INTRODUCTION

Keeping wild animals in captivity requires special attention, good quality enclosures and adequate sanitary and nutritional management. Proper care provision accounting for individual and biological behavior of different species is vital for captive animal well-being, as inadequate management may impair health in a variety of ways (FOWLER, 1986; PACHALY *et al.*, 1993).

The puma (*Puma concolor*) is a large felid native to the Americas. The average lifespan of a puma in nature is nine years, compared to up to 20 years in captivity (SIGRIST, 2012). The species is widely distributed in Brazil and South America and can be found in all biomes. The puma is included in the list of endangered species of the Brazilian fauna. The effective puma population in the country has been estimated at about 4,000 individuals, assuming a population decline of more than 10% over three generations (21 years). Therefore, the species is classified as vulnerable and in need of conservation attention (AZEVEDO *et al.*, 2013).

Major current threats to *Puma concolor* include habitat loss and fragmentation due to agricultural expansion, mining activities and exploitation of native forests for charcoal production. Elimination of individuals by "sport hunting" or retaliation in response to predation of domestic animals, forest fires arising from sugar cane field burning and road accidents are other significant contributing factors for puma population decline in several areas (AZEVEDO *et al.*, 2013).

Digestive disorders are common in veterinary practice, constipation being often diagnosed in dogs and cats (HOLT; BROCKMAN, 2007). Constipation is defined as infrequent, difficult or even absent evacuation associated with fecal retention in the colon and rectum (JONES, 2004). Prolonged retention leads to desiccation and solidification of colonic contents in response to fluid absorption, and may culminate in formation of hard fecal masses (fecalomas) that are difficult and painful to expel (HEDLUND, 2005).

Mechanical bowel obstruction by intraluminal (bone, trichobezoars, neoplasms or rectal diverticula) or extraluminal (intramural neoplasia and extramural conditions such pelvic fractures, neoplasms, prostate hyperplasia and inflammatory processes) causes may lead to fecaloma formation. Neuromuscular dysfunctions such as Cauda Equina Syndrome, lumbosacral pathology, metabolic and endocrine disorders (e.g., dehydration, hypercalcemia, hypokalemia, and hypothyroidism) are other potential underlying causes of fecaloma. Poor cat litter box management, cage confinement, inadequate diet and continued use of opioid and anticholinergic drugs are additional risk factors for fecaloma formation (HEDLUND, 2005, JONES, 2004; HOLT; BROCKMAN, 2007; MOORE; MORGAN, 2008).

Tenesmus, rectal bleeding, anorexia, emesis, dehydration, lethargy and weight loss are common clinical signs of fecal retention (HOLMES, 2004; HOLLOW; BOCKMAN, 2008). The diagnosis is based on medical history and physical examination (JONES, 2004; HOLT; BROCKMAN, 2007). Abdominal palpation may reveal hardened fecal material (MOORE; MORGAN, 2008). However, imaging assessment is recommended to confirm the diagnosis, as the enlarged colon filled with compacted fecal material can often be seen on radiographs (HEDLUND, 2005).

The treatment of fecaloma entails elimination of underlying causes (JONES, 2004) and depends disease severity (JONES, 2004; HOLT; BROCKMAN, 2007). Digital bowel evacuation combined with laxatives, suppositories and enemas is initially recommended (HOLT; BROCKMAN, 2007). However, enterotomy may be required should these measures fail (JONES, 2004). Fluid replacement therapy (MOORE; MORGAN, 2008) must be provided and electrolyte imbalances corrected (JONES, 2004) prior to conservative or surgical management of fecalomas in dehydrated patients (MOORE; MORGAN, 2008). Elimination of underlying causes is vital to prevent recurrences and should be emphasized (JONES, 2004; MOORE; MORGAN, 2008). Laxatives and dietary fiber supplementation are often enough to prevent constipation (JONES, 2004, HOLT; BROCKMAN, 2007; MOORE; MORGAN, 2008).

## CASE REPORT

A captive seven-year-old adult male puma (*Puma concolor*) weighing 30.0 kg was submitted to clinical evaluation due to prostration and signs of discomfort. The specimen belonged to the conservation refuge NEX, located in Corumbá, State of Goiás, Brazil and, according the local keeper, had been recently transferred from a breeding center located in the northern region of the country, where it was fed scraps left over from human meals.

Chemical restraint consisted of a combination of detomidine<sup>1</sup>, atropine<sup>2</sup>, tiletamine and zolazepam<sup>3</sup> given at doses calculated by interspecific allometric scaling (PACHALY, 2006). Detomidine dose was scaled from standard doses given for a 500 kg domestic horse (0.1 mg/kg). Atropine and tiletamine/zolazepam doses were scaled from standard doses reported for a 10 kg domestic dog (0.05 mg/kg and 5.0 mg/kg respectively) (PAPICH, 2009). Selection of these animal models was based on the amount of scientific information available for dosing of aforementioned drugs (PACHALY, 2006).

Doses calculated for the puma in this study were as follows: 0.12 ml of 1% detomidine, 0.11 ml of 1% atropine and 0.69 ml of tiletamine/zolazepam prepared by adding 1.5 ml of sterile water to the vial containing the freeze-dried compound (Zoletil®-50) to achieve a

final concentration of 166.6 mg/ml, as per Pellarigo *et al.* (2013).

Drugs were mixed in a single dart and administered by deep intramuscular injection into the left pelvic limb using a blowgun. The animal was monitored until signs of ataxia progressing to lateral recumbency and total loss of consciousness were noted, then transferred to a clinical examination room.

Timing of injection was recorded. Subsequent procedures were timed (minutes post-injection, MPI) at 10-minute intervals, from five minutes after loss of righting reflex to the start of the recovery period. The following parameters were measured: core body temperature (CT, degrees Celsius, °C), partial oxygen saturation (pSO<sub>2</sub>), heart rate (HR, beats per minute, bpm) and respiratory rate (RR, movements per minute, mpm). Core body temperature was measured using a digital rectal thermometer and partial oxygen saturation (pSO<sub>2</sub>) determined using a portable pulse oximeter<sup>4</sup> with the sensor attached to the animal's tongue (Figure 1A).

Severe abdominal distension was the major physical examination finding in this case. Intestinal obstruction by fecaloma or foreign body was suspected based on medical history and overall physical status. Given the severity of the condition and the lack of access to radiographic and sonographic assessment, exploratory laparotomy was immediately indicated for diagnostic and therapeutic purposes.

The patient received intravenous ceftriaxone<sup>5</sup> and intramuscular (deep injection into the pelvic limb) flunixin meglumine.<sup>6</sup> Ceftriaxone (50.0 mg/kg) and flunixin meglumine (0.25 mg/kg) doses were scaled from doses described for a 5.0 kg domestic cat (PAPICH, 2009). Intravenous lactated Ringer's solution was given throughout the surgical procedure.

Surgery was carried out with the patient in the supine position following skin prep consisting of wide clipping of the abdominal region, antisepsis and isolation of the operative field with surgical drapes. Anesthetic plane was maintained with intravenous bolus administration of 2.0 ml of propofol<sup>7</sup> at 30 and 60 MPI, then every 10 minutes (70 to 190 MPI), totaling 28.0 ml (560 mg).

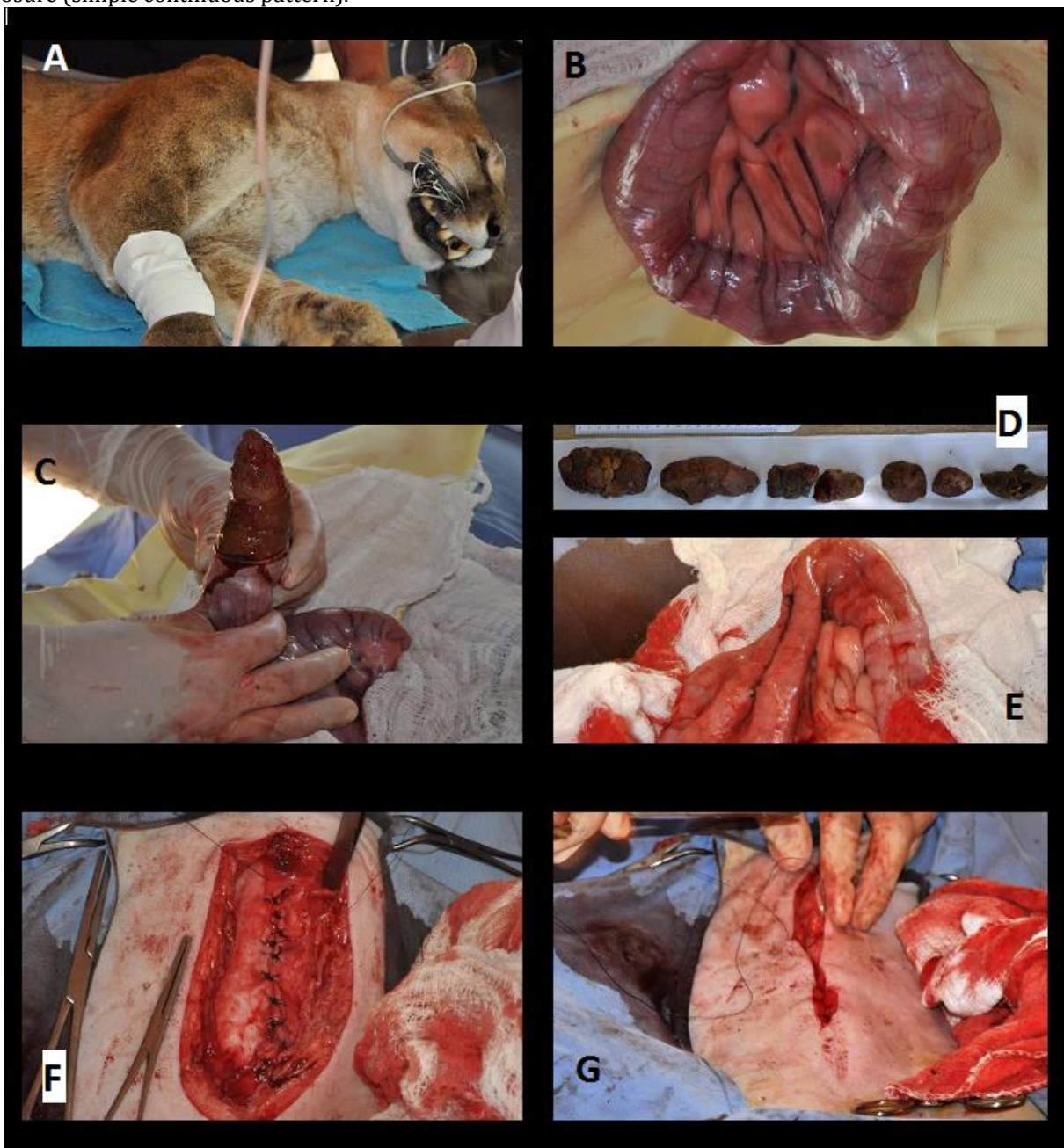
The abdominal cavity was approached via a ventral midline incision. Palpation of a hard mass measuring approximately 30 cm in length and obstructing the distal portion of the descending colon supported the suspicion of fecaloma. Following intestinal viability assessment, the affected segment was exteriorized, isolated with laparotomy pads and opened. Enterotomy revealed large amounts of hardened feces (Figure 1B), confirming the diagnosis of fecaloma. The compacted material was gently milked (Figure 1C) through the intestinal incision and removed. The mass weighed 1.04 kg and consisted of seven tightly packed fecalomas (Figure 1D).

The intestine was carefully inspected in its entire length to rule out further abnormalities (e.g., additional fecalomas, bowel perforation or stenosis) and the enterotomy incision closed with a Cushing pattern using 3.0 polyglactin 910<sup>8</sup> (Figure 1E). The abdominal wall was closed with a Sultan pattern using 2.0 nylon (Figure 1F). The subcutaneous dead space was closed in simple continuous fashion (Figure 1G) and the skin apposed with simple interrupted sutures using 2.0 nylon. Finally, a layer of cyanoacrylate adhesive<sup>9</sup> was applied onto the suture line. The patient was then transferred to an appropriate cage lined with soft hay and monitored until full anesthetic recovery.

The puma was taken back to its original enclosure the following day. Postoperative medication consisted of oral azithromycin<sup>10</sup> (10.0 mg/kg for seven days) and meloxicam<sup>11</sup> (0.1 mg/kg and 0.05 mg/kg for one and three days respectively). Both drugs were mixed with food at doses scaled from standard doses reported for a 5.0 kg domestic cat (PAPICH, 2009).

Postoperative recovery was uneventful, except for minor amounts of blood in feces in the first three days. The patient was kept on a liquid diet consisting of wet canned cat food<sup>12</sup> blended with water for seven days. Ground beef and viscera were then progressively added to the cat food mixture to form a thin paste of increasing consistency over time. Feces gained consistency as diet consistency increased. The regular chopped meat-based diet was reintroduced within 45 days of surgery. Twice weekly supplementation with meatballs containing wheat bran and linseed was recommended for life to facilitate normal evacuation and prevent future fecalomas.

Figure 1. Photographic images of a male adult puma submitted to exploratory laparotomy due to intestinal obstruction by fecalomas. A: Preoperative period. Intravenous fluid therapy and pulse oximetry monitoring of the chemically restrained patient; note oximeter sensor attached to the tongue; B: Intraoperative exposure of the obstructed descending colon; C: Milking of fecalomas through the intestinal incision; D: Fecalomas removed from the descending colon; E: Intestinal wall closure (Cushing pattern) following fecaloma removal; F: Abdominal wall closure (Sultan pattern); I: Subcutaneous dead space closure (simple continuous pattern).



## DISCUSSION

Intestinal obstruction by fecalomas have seldom been reported in wild mammals (BATISTA *et al.*, 2010). According to a survey of anatomopathological examinations, poor management, nutritional deficiency, traumatic events, poisoning and infectious diseases are common causes of death in wild animals (PIMENTA *et al.*, 2015). The fact that only one out of 32 agouti (*Dasyprocta agouti*) specimens submitted to necropsic examination presented with fecaloma (BATISTA *et al.*, 2010) suggests the condition is not common in wild neotropical rodents. In the case reported, fecaloma was

caused by inadequate diet. Poor nutritional management is a major cause of digestive disorders such as fecalomas (HEDLUND, 2005).

The puma described in this study presented with typical clinical signs of fecaloma described in dogs and cats, such as anorexia and absence of evacuation (JONES, 2004; HEDLUND, 2005; HOLT; BROCKMAN, 2007; MOORE; MORGAN, 2008). Abdominal distension was the major physical examination finding and is highly consistent with the diagnosis of fecaloma (JONES, 2004; HEDLUND, 2005; HOLT; BROCKMAN, 2007; MOORE; MORGAN, 2008).

Diagnostic imaging is thought to be the gold standard for fecaloma diagnosis (HEDLUND, 2005). Diagnostic imaging could not be performed in this case. Still, fecaloma could be suspected based on medical history and physical examination (JONES, 2004; HOLT; BROCKMAN, 2007). Abdominal palpation can reveal hardened intra-abdominal masses (MOORE; MORGAN, 2008) and exploratory laparotomy is widely indicated to confirm the diagnosis and relieve the intestinal obstruction in animal patients (EDERLI *et al.*, 2009; BORGES *et al.*, 2016).

Physical and chemical restraint of wild animal have been associated with complications and even death (PACHALY; VOLTARELLI-PACHALY, 2011; OSILHEIRE-Jr. *et al.*, 2012; PACHALY *et al.*, 2013). Therefore, the lesser the handling, the better the prognosis. In this case, immediate surgical intervention was chosen over medical treatment with enemas and laxatives as these entail chemical restraint and may not be effective (JONES, 2004; HEDLUND, 2005; HOLT; BROCKMAN, 2007; MOORE; MORGAN, 2008). Surgery was thought to be the treatment of choice in order to avoid the risks of anesthetizing the patient more than once. Also, surgical treatment is recommended for diagnosis and prompt relief of fecalomas (JONES, 2004; HEDLUND, 2005; MOORE; MORGAN, 2008). The surgical procedure in this study was widely successful. Response to treatment was uneventful and a full recovery achieved.

Blood in the feces is a common postoperative occurrence in gastrointestinal surgery (ACQUAFRESCA *et al.*, 2015) and is thought to reflect intraoperative bleeding associated with incision of the widely irrigated colonic mucosa (BERNARDES *et al.*, 2013). As in this case, this type of bleeding is often self-limiting (ACQUAFRESCA *et al.*, 2015).

Dietetic fiber supplementation is widely recommended for animals presenting with fecalomas (JONES, 2004; HEDLUND, 2005; HOLT; BROCKMAN, 2007; MOORE; MORGAN, 2008), given the high recurrence rates of the condition (JONES, 2004; HEDLUND, 2005; HOLT; BROCKMAN, 2007; MOORE; MORGAN, 2008). Therefore, life-long, twice weekly supplementation of meatballs containing wheat bran and linseed was prescribed in this case.

## CONCLUSIONS

Just like other wild carnivores, pumas are prone to intestinal obstruction by fecalomas. However, the diagnosis tends to be delayed until behavioral and physical changes are observed and, at that stage, chemical restraint is required for examination.

Clinical severity and the lack of access to radiographic and/or sonographic assessment justified the immediate indication of exploratory laparotomy in the case described. These imaging modalities are important for preoperative diagnosis and may allow conservative, less

invasive therapeutic interventions. In the case presented, surgery was the only diagnostic and therapeutic alternative. Still, this approach should be limited to such extreme cases.

Breeding centers, zoos and other institutions that keep wild animals should have access to non-invasive diagnostic modalities and conservative therapeutic alternatives for diseases such as intestinal obstructions by fecaloma. Awareness of natural dietary habits of wild animals and proper application of nutritional knowledge to optimize species-specific diets must also be emphasized.

## REFERENCES

- ACQUAFRESCA, P.A; PALERMO, M.; ROGULA, T.; DUZA, G.E.; SERRA, E. Complicações cirúrgicas precoces após bypass gástrico - Revisão da literatura. Arquivo brasileiro de cirurgia digestiva, v. 28, n. 1, p. 74-80, 2015.
- AZEVEDO, F.C.; LEMOS, F.G.; ALMEIDA, L.B.; CAMPOS, C.B.; BEISIEGEL, B.M.; PAULA, R.C.; CRAWSHAW JR, P.G.; FERRAZ, K.M.P.M.B.; OLIVEIRA, T.G. Avaliação do risco de extinção da onça-parda (*Puma concolor* Linnaeus, 1771) no Brasil. Biodiversidade brasileira, v. 3, n.1, p.107-121, 2013.
- BATISTA, J.S.; OLINDA, R.G.; SILVA, T.M.F.; RODRIGUES, C.M.F.; OLIVEIRA, A.F.; QUEIROZ, S.A.C.; MORAIS, S.R.L.; OLIVEIRA, M.F. 2010. Enfermidades de cutias (*Dasyprocta agouti*) criadas em cativeiro diagnosticadas pelo exame anatomopatológico. Pesquisa veterinária brasileira, v. 30, n.6, p.497-502. 2010.
- BERNARDES, A.; COELHO, P.; CARREIRA, C.; TEIXEIRA, L.; O'NEILL, J.G. Microvascularization of the colon and rectum of the dog by scanning electron microscopy. Journal of morphology, v. 30, n. 3, p. 191-197, 2013.
- BORGES, T.B.; QUESSADA, A.M.; RIBEIRO, R.C.L.; PAULA, D.S.; SILVA, R.B.; LEITZKE, A.V.S.; COSTA NETO, J.M. Enterite linfoplasmocítica causando granuloma com obstrução intramural mecânica do íleo em um cão - Relato de caso. Revista brasileira de medicina veterinária, v. 38(Supl.1), p.33-38, 2016.
- EDERLI, B.B.; ROCHA, A.A.; GUIDI, R.C.; EDERLI, N.B. Linfoma intestinal em cão: diagnóstico e tratamento - Relato de caso. Revista brasileira de medicina veterinária, v. 31, n.1, p. 39-42, 2009.
- FOWLER, M.E. Preventive medicine. In: \_\_\_\_\_. Zoo & wild animal medicine. 2. ed. Philadelphia: W.B. Saunders, 1986. p.14-17.
- HOLT, D.E.; BROCKMAN, D. Intestino grosso. In: SLATTER, D. Manual de cirurgia de pequenos animais. 3. ed. São Paulo: Manole, 2007. p. 665-682. v.2.
- JONES, B. Constipação, tenesmo, disquezia e incontinência fecal. In: ETTINGER, S.J.;
- FELDMAN, E.C. Tratado de medicina interna veterinária. Rio de Janeiro: Guanabara Koogan, 2004. p. 134-140.
- MARQUES, L.C.; CATTELAN, J.W.; MACORIS, D.G.; MARQUES, J.A.; PORTUGAL, E.S.; CADIOLI, F.A. (2001). Estudo clínico, cirúrgico e anatomopatológico de intussuscepção em quatro bovinos. Arquivo brasileiro de medicina veterinária e zootecnia, v.53, n.1, p. 52-57, 2001.
- MOORE, L.E.; MORGAN, R.V. Diseases of the large intestine. In: MORGAN, R.V. Handbook of small animal practice. 5. ed. Saint Louis: Saunders-Elsevier, 2008. p. 383-393.
- OSILHEIRE Jr., J.A. *et al.* Novo método para contenção farmacológica e anestesia de campo em onças-pintadas (*Panthera onca*), empregando a

fórmula ZAD (Zoletil/100 + Atropina + Dormiun-V) Relato preliminar. A hora veterinária, v. 32, p. 54-59, 2012.

PACHALY J.R. Terapêutica por extrapolação alométrica. In: CUBAS, Z. S., SILVA, J. C. R., CATÃO-DIAS, J. L. Tratado de Animais Selvagens – Medicina Veterinária. São Paulo: Roca, 2006. p. 1215-1223. Utilizar o tratado 2014.

PACHALY, J.R.; WERNER, P.R.; CIFFONI, E.M.G; SCHIMANSKI, J.C. Estresse por captura e contenção em animais selvagens. A hora veterinária. n. 74, p.47-52, 1993.

PACHALY, J.R.; VOLTARELLI-PACHALY, E.M. Novo método para contenção farmacológica e anestesia de campo em leões (*Panthera leo*), empregando a fórmula ZAD (Zoletil/100 + Atropina + Dormiun-V) Relato preliminar. A hora veterinária, v. 31, p. 75-80, 2011.

PACHALY, J.R. et al. Novo método para contenção farmacológica e anestesia de campo em quatis (*Nasua nasua*), empregando a fórmula ZAD-50 (Zoletil/50 + Atropina + Dormiun-V) - Relato preliminar. A hora veterinária, v. 33, p. 58-62, 2013.

PAPICH, M. G. Manual Saunders terapêutico veterinário, 2. ed. São Paulo: MedVet, 2009. 814 p.

PELLARIGO, B.B.; CENCI, A.G.; PARO, E.B.; SILVA, R.P.B.; BELETTINI, S.T.; PACHALY, J.R. Método de diluição concentrada do produto Zoletil@50 para contenção farmacológica de animais selvagens de grande porte. In: 12º Encontro de Iniciação Científica e 12º Fórum de Pesquisa da UNIPAR, 2013, Umuarama. Anais. Umuarama: UNIPAR, 2013.

PIMENTA, L.B.; LEMOS, G.G.; ALVAREZ, M.C.L.; PERLES, L.; RIBEIRO, J.M.; OLIVEIRA, J.P.; KAWANAMI, A.E.; SANTO, L.G., SANTI, M.; WERTHER, K. Exames anatomopatológicos em animais selvagens. In: 8º Congresso de Extensão Universitária da UNESP, 2015.

SIGRIST, T. Mamíferos do Brasil: Uma visão artística. São Paulo: Avis Brasilis, 2012. 448p.