



Clinical Reports

Feline plasm cell pododermatitis: case report

Pododermatite plasmocitária felina: relato de caso

Adriane Strack¹ , Luana Moretto¹ , Carla Di Concilio¹ , Francielli Cordeiro Zimmermann² , Adriano Tony Ramos² , Rogério Luizari Guedes³ , Marcy Lancia Pereira^{3*} 

1 Graduate student, Veterinary Medicine, Federal University of Santa Catarina, campus Curitibanos, Santa Catarina state, Brazil.

2 Professor, Department of Agriculture, Biodiversity and Forests, Federal University of Santa Catarina, campus Curitibanos, Santa Catarina state, Brazil.

3 Professor, Special Coordination of Biosciences and One Health, Federal University of Santa Catarina, campus Curitibanos, Santa Catarina state, Brazil.

ARTICLE INFO

Article history

Received 25 May 2020

Accepted 04 August 2020

Keywords:

Pad

Histopathological

Cat

Plasmacytic

ABSTRACT

Feline Plasmacytic Pododermatitis is an uncommon dermatological disorder that affects one or multiple paw pads and leads to swelling, ulceration, hemorrhage, scaling, erythema, and striation. Its etiopathogenesis is poorly understood, however, an immune-mediated basis is strongly suggested. A two-year-old neutered, mixed breed, male cat was referred to the Veterinary Clinic of the Federal University of Santa Catarina (UFSC), Curitibanos Campus, with a brief clinical history of progressive lesions on palmar and plantar pads for one month. On physical examination, the patient had enlarged popliteal and inguinal lymph nodes, and paw pads with thin, swollen, hyperemic, erythematous, and purple color skin with multiple white striations. Histopathological diagnosis confirmed plasmacytic pododermatitis, and glucocorticoid therapy with prednisolone was prescribed. In the present report, the patient's clinical follow-up was compromised, as the tutor did not perform the prescribed treatment and did not return with the animal for further evaluations.

RESUMO

A pododermatite plasmocitária felina é uma desordem dermatológica incomum que acomete os coxins plantares e/ou palmares, levando a edema, ulceração, hemorragia, descamação, eritema e estrias esbranquiçadas. Sua etiologia e patogenia são desconhecidas, mas acredita-se que tenha origem imunomediada. Foi atendido na Clínica Veterinária Escola da UFSC, Campus Curitibanos, um felino, macho, sem raça definida, 2 anos de idade, castrado, com histórico de lesões nos coxins palmares e plantares há um mês, com evolução progressiva. Ao exame físico apresentava-se com os linfonodos poplíteos e inguinais aumentados, além de coxins com pele fina, edemaciada, hiperêmica, com eritema, púrpura e estrias esbranquiçadas. O diagnóstico histopatológico confirmou pododermatite plasmocitária e foi prescrito tratamento à base de prednisolona. Não foi possível acompanhar a evolução clínica do paciente, pois o tutor não realizou o tratamento prescrito e não trouxe o animal para novas avaliações.

Palavras-chave:

Coxins

Histopatológico

Gato

Plasmocítica

INTRODUCTION

Feline plasmacytic or plasma cell pododermatitis is an uncommon skin disease that affects either palmar and planta pads. Generally, no other concurrent dermatopathy is involved (BETTENAY; LAPPIN;

MUELLER, 2007). Its etiopathogenesis is poorly understood, however, an immune-mediated basis is strongly suggested. Cats may present spongy swelling, scaling, erythema, and white striation of one or multiple paw pads (GONDIM, 2019). These lesions may become

* Corresponding author: marcy.pereira@ufsc.br

ulcerated and cause hemorrhage and lameness (HARGIS; GINN, 2013).

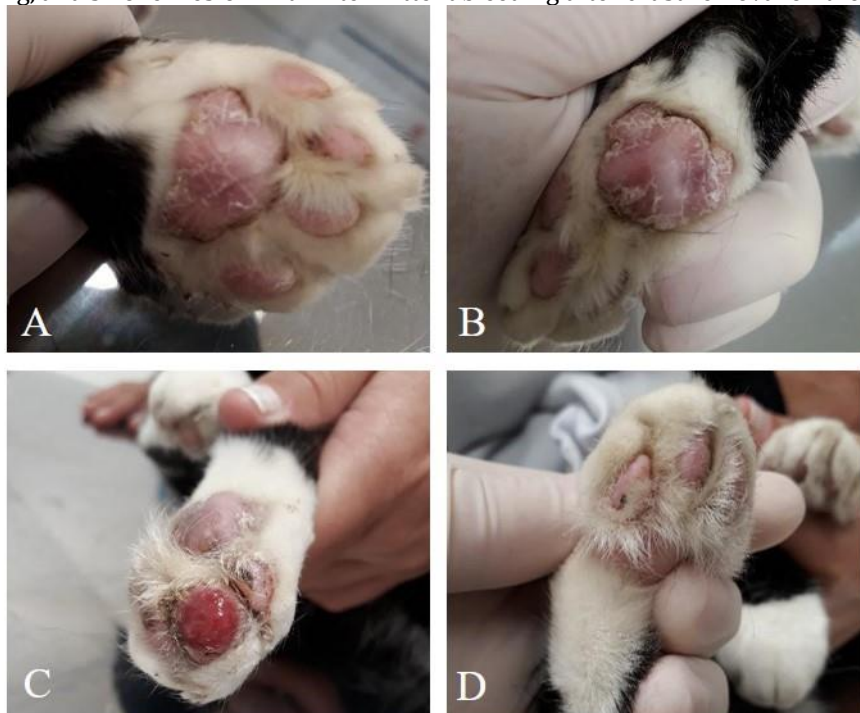Diagnosis of feline plasmacytic pododermatitis is based on the patient's history, clinical signs, and cytology, and can be confirmed histopathologically (NUTTALL; HARVEY; McKEEVER, 2009; GRUCHOUSKEI et al., 2012).

The treatments of choice include the use of glucocorticoids and immunomodulators, as well as surgical excision of the affected sites (PEREIRA; FAUSTINO, 2003; GUAGUERE et al., 2004). Cryotherapy may be an option to conventional surgical treatment (GRUCHOUSKEI et al., 2012).

National scientific reports on feline plasma cell pododermatitis are lacking (MACHADO et al., 2009; LOSS et al., 2010; GRUCHOUSKEI et al., 2012; CORDEIRO et al., 2012; LARSSON et al., 2013; OLIVEIRA et al., 2014; SANTOS; SANTOS; MUZZI, 2017; COSTA; CALLEGAN; CARON, 2018). Therefore, the present case report aims to contribute with important information regarding clinical signs and histopathological findings of an adult feline affected by this disease at the Veterinary Clinic of the Federal University of Santa Catarina (UFSC).

CASE REPORT

Figure 1. Images of the paw pads lesions of the feline patient: left forelimb (A), right forelimb (B), left hindlimb (C), right hindlimb (D). Thin skin, erythema, scaling, and white striation were noticed on all paw pads of the left fore and hind limbs; and erythematous, oozing, and swollen lesion with intermittent bleeding after crust removal on the left hindlimb.



Slight improvement of the paw pads lesions was noticed after seven days; however, intermittent bleeding was still present on the left hindlimb. There was a decrease in the amount of ocular discharge, and differently from inguinal lymph nodes, popliteal lymph nodes remained enlarged. Results from the cytological analysis revealed a

A two-year-old, neutered, mixed breed male cat was referred to the Veterinary Clinic of the Federal University of Santa Catarina (UFSC), Curitibaanos *Campus*. According to the tutor, the patient presented progressive lesions on the palmar and plantar paw pads for a month. No other clinical signs or previous medical history were reported. The patient was regularly vaccinated with core vaccines (V3) and had outdoor access. On physical examination, the animal was alert, with good body score condition (3/5), and presented enlarged popliteal and inguinal lymph nodes. Signs of blepharitis manifested by a significant amount of mucopurulent ocular discharge and swollen, and hyperemic eyelids were also noticed. The paw pads were purple, swollen, hyperemic, erythematous, with thin skin and white striations. sites Intermittent bleeding was also noticed in one of the limbs (Figure 1).

Swab and lesion imprint of the left hindlimb paw were carried out and sent to cytological analysis for differential diagnosis for Sporotrichosis. Combined tobramycin and dexamethasone eye drop (1 drop, BID, 7 days) was prescribed to treat blepharitis, and footbath with potassium permanganate, once daily for 7 days, was indicated for paw pads lesions.

suppurative bacterial inflammation. Thus, maintenance of the footbaths associated with 1% chlorhexidine spray were prescribed. Swabbing of the ocular discharge for viral isolation and bacterial culture and antibiogram was carried out to discard Calicivirus infection. All tests presented negative results. Hematological findings

showed discrete mature neutrophilia ($13,690/\text{mm}^3$, reference interval 2,500 to $12,500/\text{mm}^3$) e thrombocytopenia ($22 \times 10^3/\mu\text{L}$, reference interval 300 to $800 \times 10^3/\mu\text{L}$) and platelet aggregation.

Inconclusive results and lack of clinical improvement led to biopsy indication and histopathological analysis of the affected sites. An incisional biopsy of the left plantar paw pad was performed. Postoperative prescription included oral dipyrone (25 mg/kg, TID), surgical wound cleansing with physiological solution and gauze, use of pet cone, and stitch removal in 7 days. The excised fragment was fixed in 10% buffered formaldehyde solution and sent to histological analysis.

After one week, the paw pads skin remained thin, with erythema and scaling. Similarly, ocular discharge and enlarged right popliteal lymph node did not show any improvement. FIV and FeLV snap tests were carried out (Alere Diagnóstico Veterinário) and presented negative results for both diseases.

As a result of the pathological analysis, gross inspection of the fragment revealed a white and pink colored spongy tissue. At microscopy, a marked diffuse plasma

cell pododermatitis was diagnosed. Thus, orthokeratotic hyperkeratosis and acanthosis were present in the epidermis. In the dermis, an intense cell infiltration of well-differentiated plasma cells was noted, with the presence of Mott cells (plasma cells with spherical intracytoplasmic inclusions called Russel bodies), erythrophagocytosis, neutrophils, and lymphocytes, of which some of them presented two nuclei. This infiltrate extended to the adjacent subcutaneous tissue (Figure 2). Among the inflammation, scattered sites of weak eosinophilic amorphous material were observed. This material, when stained with Congo red and subjected to polarized light, was emerald green, which confirmed presence of amyloid (Figure 3).

Prescribed treatment included oral prednisolone 2,0 mg/kg, once daily, for 30 days, with clinical reassessment immediately before the end of the medication. Unfortunately, the tutor did not return. Nevertheless, through telephone contact, he informed a lack of clinical improvement; however, due to personal reasons, the prescribed treatment was never carried out.

Figure 2. Skin fragment with marked diffuse plasma cell pododermatitis. A – intense cell infiltration of the subcutaneous and superficial and deep dermis (H&E – 40x magnification). B – Magnification of image A showing sparse inflammatory infiltrate with amorphous eosinophilic material (amyloid and collagen fibers) within the superficial and part of the deep dermis) (H&E – 100x magnification). C – Magnification of image B, plasmacytes with eosinophilic cytoplasm and eccentric nucleus surrounded by lymphocytes and macrophages (arrow) (H&E – 400x magnification). D – Hyperplasia of the epidermis in its spinous (acanthosis) and corneal (orthokeratotic hyperkeratosis) layers (H&E – 100x magnification). E – Dermis on an adjacent location to the other images. Mott cell (magnified on the left superior corner - arrow), containing intracytoplasmic Russell bodies. Plasma cells, lymphocytes, and macrophages infiltrates can also be noticed (H&E – 400x magnification and Mott cell insertion in H&E – 1000x magnification). F – Dermis on an adjacent location to the other images. Russell bodies covering up different portions of the Mott cell (arrow). Plasma cells infiltrate (arrowhead), lymphocytes, and macrophages can also be noticed (H&E – 1000x magnification).

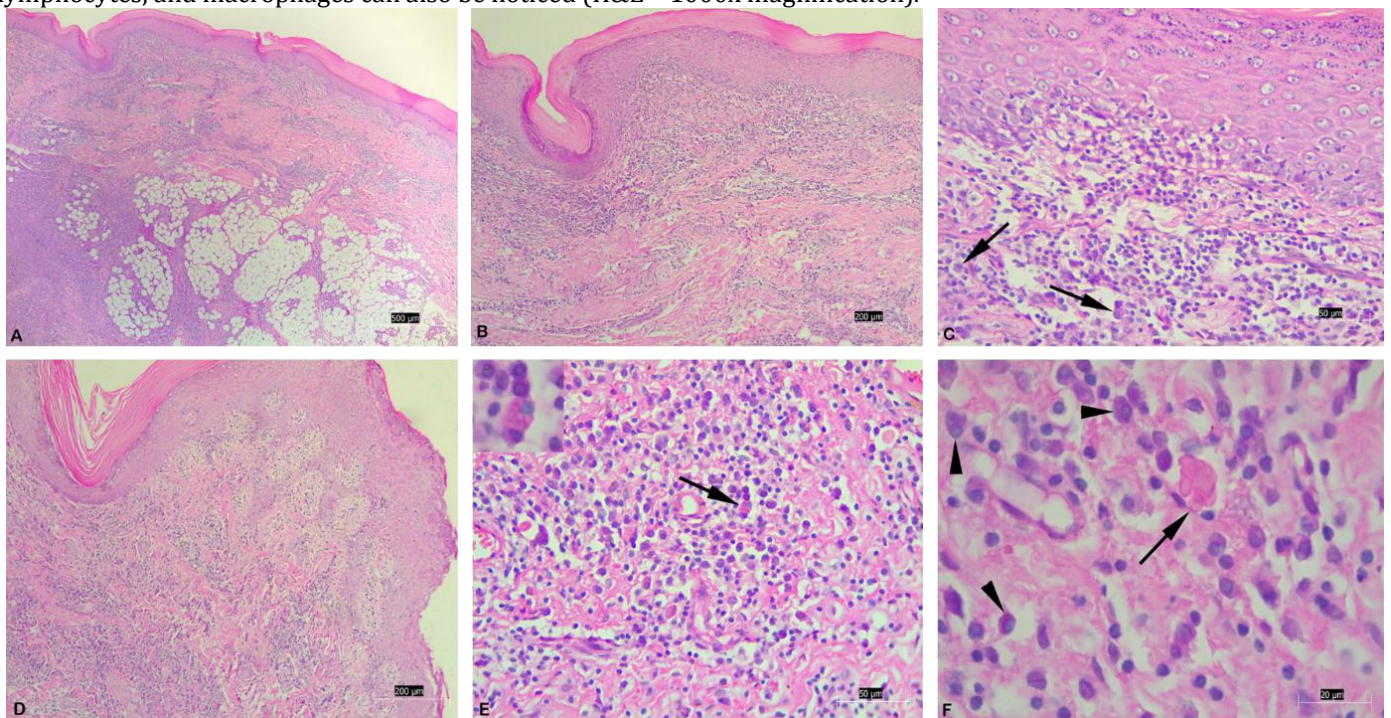
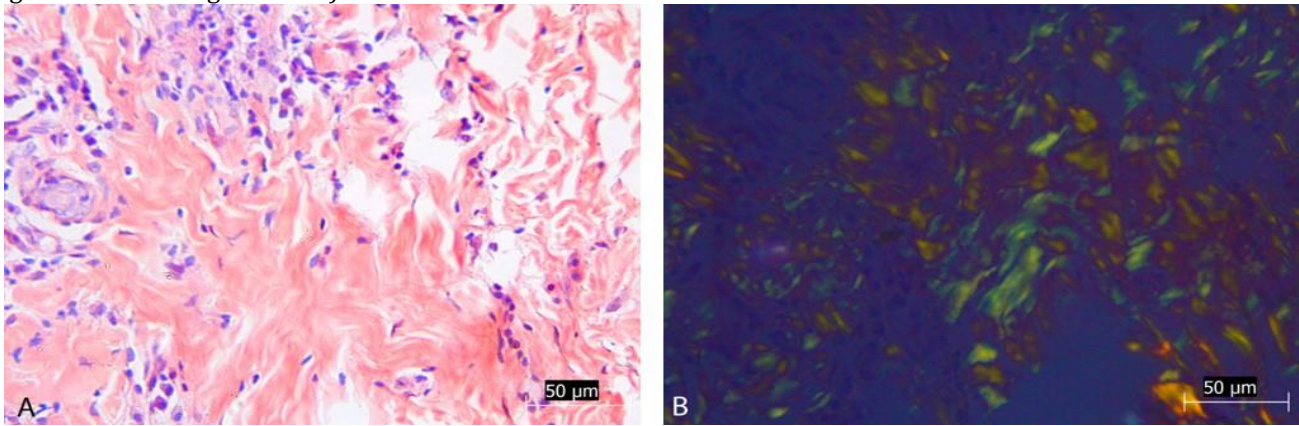


Figure 3. Skin fragment in the dermis with amyloid deposits. A - Amorphous eosinophilic material (amyloid) without polarized light (Congo red – 400X magnification). B - Amyloid confirmed by the emerald green color, under polarized light (Congo red – 400X magnification).



DISCUSSION AND CONCLUSIONS

The present report describes a case of feline plasmacytic pododermatitis in a young adult male cat. Although some authors state that there is no relation between this disease and patients' age (GRUCHOUSKEI et al., 2012), other studies indicate that young to middle age cats are more suitable to develop this disorder (BETTENAY et al., 2003; SCARAMPELLA; ORDEIX, 2004; DOBROMYLSKYJ, 2015).

Concomitant diseases, such as plasmacytic stomatitis (GUAGUERE et al., 2004; MATA; VICH, 2005), immune-mediated glomerulonephritis (GUAGUERE; HUBERT; DELABRE, 1992; MATA; VICH, 2005), renal amyloidosis (PEREIRA; FAUSTINO, 2003; MATA; VICH, 2005), and FIV (SIMON et al., 1993; CADIERGUES; DELVERDIER; FRANC, 2002; GUAGUERE et al., 2004; SCARAMPELLA; ORDEIX, 2004; BETTENAY; LAPPIN; MUELLER, 2007; HARGIS; GINN, 2013; SHUMAKER, 2019) may be associated to plasma cell pododermatitis. As for FeLV, there is no correlation described in the literature. Although the patient presented negative results in FIV / FeLV snap test, which has good sensitivity and specificity (MEDEIROS et al., 2019), the diagnosis should be confirmed with a qPCR test. However, due to the tutor's financial limitations, this test was unable to be performed.

Clinically, this condition starts with mild and painless swelling (GRUFFYDD-JONES; ORR; LUCKE, 1980) which can progress to epidermal ulceration and formation of friable red granulation tissue that may lead to soreness and lameness (GRUFFYDD-JONES; ORR; LUCKE, 1980; PEREIRA; FAUSTINO, 2003). Once this patient did not present granulation tissue, ulcers, or signs of lameness, it may be assumed that the patient presented an early stage of the disease.

Plasmacytic pododermatitis is a disease that can develop solely and affect one or multiple limbs (GROSS et al., 2005). In this case, lesions were present in all four limbs, and as previously mentioned by Gondim (2019), scaling, erythema, and white striation were common findings. In

addition, on physical examination, the patient presented lymphadenopathy, as mentioned in other reports of the disease (GUAGUERE; HUBERT; DELABRE, 1992; NUTTALL; HARVEY; MCKEEVER, 2009).

Initially, sporotrichosis was suspected. Thus, this disease was considered as a probable diagnosis once the patient was a male cat with outdoor access, and presented paw pad lesions, which can be ulcerative or not, with crusts, moisty and contaminated (BAZZI et al., 2016; ALMEIDA et al., 2018). However, this disease was disregarded after a negative cytological result and posteriorly excluded as a differential diagnosis after histopathological analysis.

Although the patient was vaccinated, the presence of ocular discharge with eyelid edema and hyperemia, and partial responsiveness to antibiotic and anti-inflammatory therapy, led to the suspect of Feline Calicivirus infection (KENNEDY; LITTLE, 2016). When systemic, this disease may develop signs of skin edema and ulcerative lesions on the head, limbs (HURLEY et al., 2004; PESAVENTO et al., 2004; RADFORD et al., 2009) and paw pads (HURLEY et al., 2004; PESAVENTO et al., 2004). These findings are quite similar to the ones noticed in the present report; however, after a negative result for viral isolation, caliciviruses was ruled out.

Other conditions are considered as differential diagnoses for plasmacytic pododermatitis. Thus, on eosinophilic granulomas, crusts, and ulceration in the paw pads are present; however, interdigital alopecia, erythema, and inflammation are also common findings (GROSS et al., 2005). In addition, immune-mediated diseases such as pemphigus foliaceus or lupus erythematosus (CADIERGUES; DELVERDIER; FRANC, 2002), are conditions that involve the limbs of middle-aged felines, with the presence of crusts (MORIELLO, 2016), hyperkeratosis and ulceration (GUAGUERE; HUBERT; DELABRE, 1992) on the paw pads. Such diseases were excluded for this patient, once definitive diagnosis of plasmacytic pododermatitis was determined by histopathological analysis

Plasma cells and Mott cells, which are plasma cells containing abundant intracytoplasmic granules formed by immunoglobulin, are usually described as common histopathological findings. Neutrophils can also be noticed regardless of the presence or absence of ulcers. In addition, edema of the dermis, mucin, and more rarely eosinophils may also be present. Blood vessels may be more prominent, and congestions and decreased number of lymphocytes and macrophages can also be observed (GROSS et al., 2005). The patient's histopathological results showed a very similar inflammatory infiltrate, with evident Mott cells, and the presence of erythrophagocytosis, amyloid, acanthosis, and orthokeratotic hyperkeratosis.

Thrombocytopenia is a frequent finding for feline plasmacytic pododermatitis (GUAGUERE; HUBERT; DELABRE, 1992; SCARAMPELLA; ORDEIX, 2004). However, in this report, the patient's thrombocytopenia was accompanied by platelet aggregation, which underestimates platelets total count. Thus, it would be prudent to repeat the platelet count chart. Although other findings, such as leukocytosis (GRUFFYDD-JONES; ORR; LUCKE, 1980; SCARAMPELLA; ORDEIX, 2004) and hypergammaglobulinemia (GUAGUERE; HUBERT; DELABRE, 1992; CADIERGUES; DELVERDIER; FRANC, 2002; GRUFFYDD-JONES; ORUC; SCARAMPELLA; ORDEIX, 2004) are also described, in this case, total blood count did not present significant changes, and plasma proteins were not requested.

Potassium permanganate solution and chlorhexidine are topical, bactericidal, antiseptic agents that were used on the symptomatic treatment of the patient's skin lesions. An immunosuppressive dose of prednisolone was prescribed after a definitive diagnosis. However, the tutor did not perform the treatment. Since the healing of the lesions tends to be fast (PEREIRA; FAUSTINO, 2003; MORIELLO, 2016), and with excellent results in up to 30 days, (CADIERGUES; DELVERDIER; FRANC, 2002; OLIVEIRA et al., 2014) the prescribed therapy would be in accordance to what is recommended by the scientific literature. Other therapeutic options include the use of immunomodulatory agents such as doxycycline (GUAGUERE; HUBERT; DELABRE, 1992; MORIELLO, 2016). Still, besides the long-lasting time for the complete remission of signs (DONNELLY, 2003), according to the veterinary medicine antibiotic therapy guidelines, this therapeutic modality should only be used after the diagnosis of bacterial disease (SILLEY; STEPHAN, 2017).

Prognosis of feline plasmacytic pododermatitis is usually favorable. However, in recurrent cases, in which long-lasting treatments are required, or in the presence of stomatitis or concomitant kidney disease, patients tend to have a reserved to poor prognosis (MEDLEAU; HNILICA, 2003; LARSSON et al., 2013). In the present report, the patient's clinical follow-up was compromised, as the tutor did not perform the prescribed treatment and did not return with the animal for further evaluations.

REFERENCES

- ALMEIDA, A. J. et al. Esporotricose em felinos domésticos (*Felis catus domesticus*) em Campos dos Goytacazes, RJ. *Pesquisa Veterinária Brasileira*, v. 38, n. 7, p. 1438-1443, 2018.
- BAZZI, T. et al. Características clínico-epidemiológicas, histomorfológicas e histoquímicas da esporotricose felina. *Pesquisa Veterinária Brasileira*, v. 36, n. 4, p. 303-311, 2016.
- BETTENAY, S. V. et al. Prospective study of the treatment of feline plasmacytic pododermatitis with doxycycline. *Veterinary Record*, v. 152, n. 18, p. 564-566, 2003.
- BETTENAY, S. V.; LAPPIN, M. R.; MUELLER, R. S. An Immunohistochemical and polymerase chain reaction evaluation of feline plasmacytic pododermatitis. *Veterinary Pathology*, v. 44, n. 1, p. 80-83, 2007.
- CADIERGUES, M. C.; DELVERDIER, M.; FRANC, M. Feline plasma cell pododermatitis: a clinical case and literature review. *Revue de Medecine Veterinaire*, v. 153, n. 5, p. 311-313, 2002.
- CORDEIRO, C. T. et al. Pododermatite plasmocítica felina - relato de caso. *MEDVEP DERMATO*, v. 2, n. 5, p. 284-288, 2012.
- COSTA, I. R. R.; CALLEGAN, F. Z.; CARON, V. F. Pododermatite plasmocítica felina: relato de caso. *Revista Eletrônica Biotecnologia, Biotecnologia e saúde*, v. 11, n. 22, p. 164-165, 2018.
- DOBROMYLSKYJ, M. Feline plasma cell pododermatitis - A pathologist's eye view. *Control and Therapy series*, v. 279, p. 41-45, 2015.
- DONNELLY, T. M. Diagnóstico: Pododermatite plasmocítica felina. *Lab Animal*, v. 32, n. 10, p. 24-25, 2003.
- GONDIM, A. L. C. L Pododermatite plasmocitária felina - Revisão de literatura. *Revista Brasileira de Higiene e Sanidade Animal*, v. 13, n. 4, p. 478-488, 2019.
- GROSS, T. L. et al. Nodular and diffuse diseases of the dermis with prominent eosinophils, neutrophils, or plasma cells. In: *... Skin diseases of the Dog and Cat: Clinical and Histopathologic Diagnosis*. 2. ed. Hong Kong: Blackwell, 2005. v. 1. cap. 14, p. 342-372.
- GRUFFYDD-JONES, T. J.; ORR, C. M.; LUCKE, V. M. Foot pad swelling and ulceration in cats: a report of five cases. *Journal of Small Animal Practice*, v. 21, n. 7, p. 381-389, 1980.
- GRUCHOUSKEI, L. et al. Pododermatite plasmocitária felina. *Archives of Veterinary Science*, v. 17, n. 1, p. 32-36, 2012.
- GUAGUERE, E. et al. Feline plasma cell pododermatitis: a retrospective study of 26 cases. *Veterinary Dermatology*, v. 15, n. 1, p. 27, 2004.
- GUAGUERE, E.; HUBERT, B.; DELABRE, C. Feline pododermatoses. *Veterinary Dermatology*, v. 3, n. 1, p. 1-12, 1992.
- HARGIS, A. M.; GINN, P. E. O tegumento. In: ZACHARY, J. F.; McGAVIN, M. D. *Bases da Patologia em Veterinária*. 5.ed. Rio de Janeiro: Elsevier, 2013. cap. 17, p. 975-1087.
- HURLEY, K. F. et al. An outbreak of virulent systemic feline calicivirus disease. *Journal of the American Veterinary Medical Association*, v. 224, n. 2, p. 241-249, 2004.
- KENNEDY, M.; LITTLE, S. E. Doenças infecciosas. In: LITTLE, S. E. *O gato: medicina interna*. 1.ed. Rio de Janeiro: Roca, 2016. v. 1, cap. 33, p. 978-1046.
- LARSSON, C. E. et al. Pododermatite plasmocítica felina - relato de caso. *Revista de educação Continuada em Medicina Veterinária e Zootecnia do CRMV-SP*, v. 11, n. 1, p. 58, 2013.

LOSS, F. R. et al. Pododermatite plasmocitária felina: relato de caso. MEDVEP. Revista Científica de Medicina veterinária. Pequenos animais e Animais de Estimação, v. 8, n. 25, p. 217-220, 2010.

MACHADO, L. H. A. et al. Pododermatite plasmocitária felina – relato de caso. Clínica Veterinária, v. 82, p. 78-82, 2009.

MATA, R. P.; VICH, C. Pododermatitis plasmocítica felina. Caso clínico. REDVET. Revista Eletrônica de Veterinária, v. 6, n. 2, p. 1-2, 2005.

MEDEIROS, S. O. et al. Avaliação de dois testes sorológicos comerciais para diagnóstico das infecções pelo FIV e pelo FeLV. Arquivo Brasileiro de Medicina Veterinária e Zootecnia, v. 71, n. 2, p. 447-454, 2019.

MEDLEAU, L.; HNILICA, K. A. Miscelânea de enfermidades cutâneas em gatos. In: _ Dermatologia de pequenos animais: atlas colorido e guia terapêutico. 1. ed. São Paulo: Roca, 2003. v. 1. cap. 15. p. 250-262.

MORIELLO, K. A. Dermatologia. In: LITTLE, S. E. O gato: medicina interna. 1.ed. Rio de Janeiro: Roca, 2016. v. 1, cap. 22, p. 358-410.

NUTTALL, T.; HARVEY, R. G.; MCKEEVER P. L. Ulcerative Dermatoses. In: ___ A Colour Handbook of: Skin Diseases of the Dog and cat. 2. ed. Florida: Manson Publishing, 2009. cap. 3, p. 97-144.

OLIVEIRA, E. T. A. et al. Pododermatite plasmocitária felina: relato de caso. In: Congresso Brasileiro da Anclivepa, 35º, 2014, Belo Horizonte. Anais..., p. 279-281. Disponível em: <<https://dokumen.tips/documents/pododermatite-plasmocitaria-felina-relato-de-caso-pododermatite-plasmocitaria.html>>. Acesso em: 09 mai. 2020.

PEREIRA, P. D.; FAUSTINO, A. M. R. Feline plasma cell pododermatitis: a study of 8 cases. Veterinary Dermatology, v. 14, n. 6, p. 333-337, 2003.

PESAVENTO, P. A. et al. Pathologic, immunohistochemical, and electron microscopic findings in naturally occurring virulent systemic feline calicivirus infection in cats. Veterinary Pathology, v. 41, n. 3, p. 257-263, 2004.

RADFORD, A. D. et al. Feline calicivirus infection: ABCD guidelines on prevention and management. Journal of Feline Medicine and Surgery, v. 11, n. 7, p. 556-564, 2009.

SANTOS, N. R. S.; SANTOS, R. C.; MUZZI, R. A. L. Pododermatite plasmocítica felina – relato de caso. In: Congresso MEDVEP Internacional de Especialidades Veterinárias, 2017, Curitiba. Anais... Curitiba: MEDVEP, 2017. p. 356-357.

SCARAMPELLA, F.; ORDEIX, L. Doxycycline therapy in 10 cases of feline plasma cell pododermatitis: clinical, haematological and serological evaluations. Veterinary Dermatology, v. 15, n. 1, p. 27, 2004.

SHUMAKER, A. Autoimmune and Immune-mediated dermatologic disorders. In: COYNER, K. S. Clinical Atlas of Canine and Feline Dermatology. 1. ed. Hoboken: Wiley-Blackwell, 2019. Cap. 11, p. 255-289.

SILLEY, P.; STEPHAN, B. Prudent use and regulatory guidelines for veterinary antibiotics- politics or science? Journal of Applied Microbiology, v. 123. n. 6, p. 1373-1380, 2017.

SIMON, M. et al. Plasma cell pododermatitis in feline immunodeficiency virus-infected cats. Veterinary Pathology, v. 30, n. 5, p. 477, 1993.