



Case Report

Metabolic bone diseases in a wild crab-eating hawk and a caboclo hawk in Paraíba

Ricardo Romão Guerra^{1*}, Glenison Ferreira Dias², Harlan Hallamys de Lima Nascimento², Temistocles Soares de Oliveira Neto³, Ricardo Barbosa de Lucena

¹ Universidade Federal da Paraíba/ UFPB, Centro de Ciências Agrárias, Programa de Pós-Graduação em Ciência Animal/ Programa de Pós-Graduação em Zootecnia, Areia, Paraíba (PB).

² Universidade Federal da Paraíba/ UFPB, Centro de Ciências Agrárias, Programa de Pós-Graduação em Ciência Animal, Areia, Paraíba (PB).

³ Universidade Federal de Campina Grande/ UFCG, Centro de Saúde e Tecnologia Rural, Programa de Pós-Graduação em Medicina Veterinária, Patos, Paraíba (PB).

ARTICLE INFO

Article history

Received 30 January 2018

Received in revised form 26 April 2018

Accepted 09 May 2018

Keywords:

Calcium

Histopathology

Metabolism

Birds of prey

ABSTRACT

The amount of research on metabolic bone diseases in commercial birds is considerable, however, there is a large gap in the knowledge of these diseases in wild birds. Aspects related to diet are the main factors that cause these diseases, such as: vitamin D deficiency, insufficient calcium intake, or imbalance of calcium and phosphorus in the diet, and problems in the absorption and metabolism of these compounds. This study reports two cases of bone diseases in birds of the order Accipitriformes, which are wild in the state of Paraíba, a crab-eating hawk with rickets, and a caboclo hawk with fibrous osteodystrophy. The diagnosis in both cases was based on macroscopic and microscopic findings. These reports are subsidies for the bird clinic of the order Accipitriformes and for the maintenance of these birds in nurseries and zoos. This study demonstrates the need for further studies to assess whether such cases can be used as indicators of environmental imbalance.

INTRODUCTION

Metabolic bone diseases may be caused by vitamin D deficiency, insufficient calcium intake or calcium and phosphorus balance in the diet, and absorption and metabolism problems with these elements. The nomenclature and cause of these disorders are diversified and include: osteomalacia, osteoporosis, rickets, primary or secondary hyperparathyroidism, bone atrophy, and juvenile osteoporosis (FOWLER, 1986).

Adequate levels of calcium and phosphorus are present in the natural diet of birds of prey, since the bones and viscera consumed contain the appropriate ratio of calcium-phosphorus. Metabolic bone disease conditions

can be observed in improperly fed birds of prey in captivity, such as using boneless meat, insect-based diets, large prey that make it impossible for the birds to ingest the whole carcass, or immature animals as food (CUBAS, 2015). The provision of ultraviolet light has influence on the serum level of calcium, so the correct use of an unfiltered light source is of great importance to prevent the clinical signs of disorders of calcium metabolism (STANFORD, 2006).

In a study carried out with wild birds coming from rehabilitation centers and private clinics, Stenkat; Krautwald-Junghanns; Schmidt (2013) show that 13% of the cases that led to the mortality or morbidity of birds from urban centers in general were due to metabolic diseases, such as fibrous osteodystrophy. Rickets is a

* Corresponding author: rromaoguerra@gmail.com

bone disease characterized by the inefficient mineralization of the epiphyseal plate, a disease that occurs in growing animals, with low extracellular concentration of calcium and phosphorus (MECHICA, 1999). The casuistry of fibrous osteodystrophy and rickets in free-living (wild) animals is low, and it is necessary to analyze the environmental factors that led to this. Cases have been described in cattle egrets (*Bubulcus ibis*) (PHALEN et al., 2005), crows (*Corvus brachyrhynchos*) (TANGREDI, 1990), and in vulture chicks (*Gyps* sp.) (RICHARDSON; PLUG, 1986). In the first, the egrets of two groups of regions with different available foods were analyzed, and lesions were observed in the chicks of one of the groups, in which there was less insect abundance.

Cases of metabolic bone diseases in commercial poultry and captive wild birds have been well reported and studied, but there is a shortage of literature among free wild birds. The occurrence of metabolic bone diseases in free-living animals is an alarming phenomenon (PHALEN et al., 2005; TANGREDI, 1990), since these animals theoretically have access to diets without human influence. In this study, metabolic bone diseases were described for the first time in a crab-eating hawk and a caboclo hawk, both living freely in Paraíba. Thus, the two cases of this study fill some of this gap in the literature and demonstrate the need for further studies on the anthropic influence on the diets of free-living animals, negatively influencing biological balance.

CASUISTRY CASE REPORT

A crab-eating hawk nestling (*Buteogallus aequinoctialis*) was taken to the Arruda Câmara Zoological Park, in João Pessoa, PB by the Environmental Police because it was having difficulty in locomotion. It had a fracture in the right femur and the left tibia was curved, which generated an abnormal posture in the bird. To avoid aggravation of the lesion, the animal was immobilized and placed in a calm environment, until surgical procedure. In captivity, the animal also fractured the left femur as a result of repeated efforts to get up and it died before corrective surgery, and thus was sent to necropsy.

A young specimen of caboclo hawk (*Heterospiza meridionalis*) was transferred to the Arruda Câmara Zoological Park, in João Pessoa, PB after apprehension by the Environmental Police. It already had a consolidated fracture in the left tibiotarsus, and in the zoo it fractured the tibia and fibula on the same side after a short flight. This complete fracture was stabilized by surgical placement of external fixation. One month after the surgical procedure, radiography was performed in which poorly developed mineralization was observed at the site, so that fixation was maintained for 15 more days. During this period the bird had a pathological fracture in

the same tibia and fibula. The previous diet of this bird was unknown; at the zoo, its diet was composed of adult rats and mice, and calcium supplementation. The bird was submitted to euthanasia due to worsening of the clinical picture and lack of response to the treatments, and then it was also sent to necropsy.

The procedures and euthanasia described in this study were approved by the Committee of Ethics on Use of Animals of the Federal University in Paraíba (CEUA-UFPB), under the number 149/2017. The necropsies occurred at the Laboratory of Pathology and Anatomy of the Center of Agricultural Sciences of the Federal University of Paraíba, Areia, PB. During necropsies samples of the liver, thyroid, parathyroid and the external, tibia and femur bones were collected. The fragments were submitted to routine histological processing (RAMOS et al., 2011). Prior to conventional processing, the bone samples were dematerialized by using 5% formic acid exchanged daily for 4 days. The 5 µm sections were stained with hematoxylin-eosin and Masson's Trichrome.

In the macroscopic analysis of the crab-eating hawk, three fractures and the curving of the tibia (Figure 1A) and keel (Figure 1B) were observed. The fragile bones were easily cut with scissors. In microscopy, the markedly thickened and irregular epiphyseal cartilage plate was observed (Figure 2A). Just below the plate, bone trabeculae with persistent cartilage in the interior and islands of cartilage indicating incomplete mineralization of spongy bone were observed. The trabecular bone was atrophied, characterized by thin and poorly mineralized trabeculae, and surrounding these trabeculae there was a large quantity of active osteoblasts and connective tissue in the middle of the trabeculae. This tissue was strongly stained with Masson's Trichrome blue. Cortical bone was also largely replaced by fibrous connective tissue (Figure 2B). The formation of irregular and slightly mineralized bone calluses denoting areas of previous fractures was also observed. No alterations were found in the liver, thyroid, and parathyroid samples in this specimen.

In the macroscopic analysis of the caboclo hawk, we observed fractures and the presence of bone calluses (Figure 3). In microscopy of the spongy bone, we observed areas of fractures with formation of irregular and poorly mineralized bone calluses (Figure 4 A); atrophied, poorly mineralized trabeculae and in some areas the absence of trabeculae and a large quantity of osteoblasts surrounding the trabeculae. Masson's trichrome staining showed bone tissue replacement by fibrous connective tissue. Parathyroids were increased, characterized by intense cell proliferation with cytoplasmic vacuolization. No changes were found in liver and thyroid samples.

Figure 1 – Photographic bone images of wild free-living crab-eating hawk (*Buteogallus aequinoctialis*). A) Tibiotarsus and femur: fractures in the femur (arrow head) and curving tibiotarsus (arrow). B) Curving the keel (asterisk).

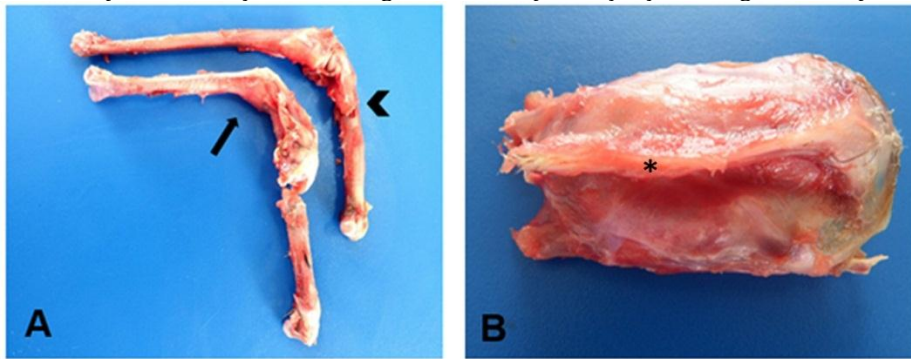


Figure 2 – Photomicrographs of the tibiotarsus of the crab-eating hawk (*Buteogallus aequinoctialis*). A) Plate of thick and irregular epiphyseal cartilage (asterisk). B) Replacement of cortical bone by fibrous connective tissue marked in blue (delimited by brackets) and microfracture (thin arrow). A) Bar = 800µm. B) Bar = 200µm. Masson's trichrome staining.

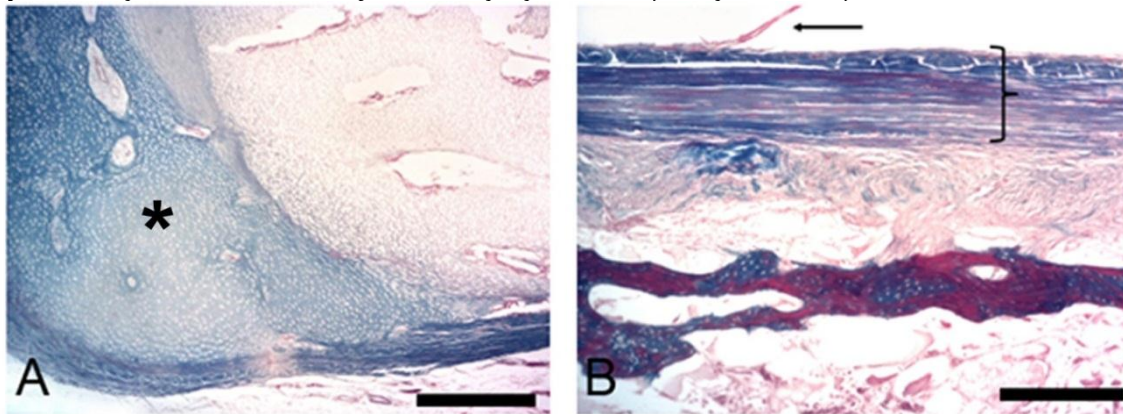
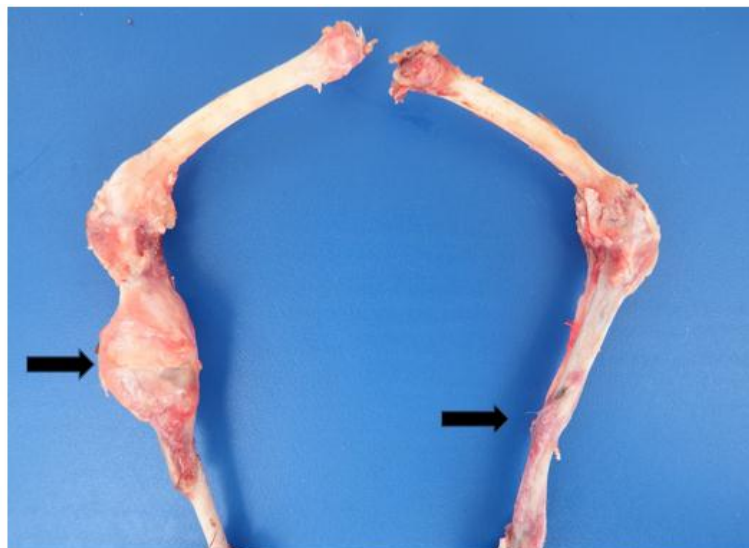

Figure 3 – Photographic image of the lower limbs of caboclo hawk (*Heterospizias meridionalis*). Presence of bone calluses in the tibiotarsus (arrows).



DISCUSSION

Metabolic bone diseases are much more frequent in young specimens than in adults because of the rapid

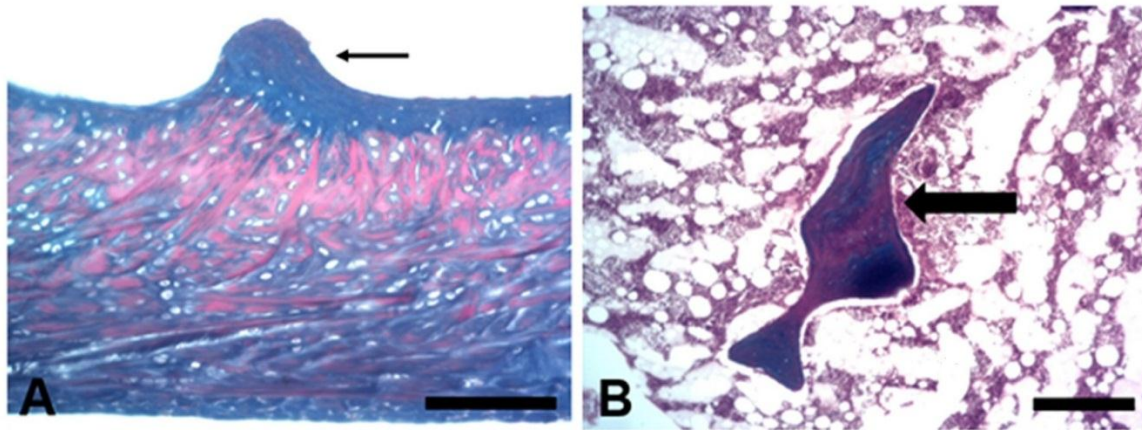
growth of the birds, which reach adult size five times faster than mammals (COUSQUER; DANKOSKI; PATTERSON-KANE, 2007). Therefore, there is a great need for an adequate supply of calcium, phosphorus and

vitamin D in the diet. Due to the high calcium requirement, birds can develop bone diseases in a matter of days of restriction (GRAHAM, 2013). In the present study, the two hawks were young and had bone diseases; and as final diagnosis, the crab-eating hawk had rickets and the caboclo hawk had rickets and the caboclo hawk had fibrous osteodystrophy.

The histopathological and macroscopic findings in the crab-eating hawk were consistent with the diagnosis of rickets. The lack of detailed history, which would include the type of feeding in nature, made it difficult to investigate the causes that led to this situation. However, it is known that the crab-eating hawk feeds exclusively on crabs (SICK, 1987), so this bird can act as an environmental indicator of the quality of the swamps or

mangroves. Although the mangroves of the Brazilian coast are included as areas of environmental preservation (LACERDA; SANTOS; MADRID, 2006), they are still irregularly exploited without any form of appropriate management, resulting in the degradation of the natural resources of these ecosystems (SILVA; CONSERVA; OLIVEIRA, 2011). The lack or decrease of dietary items for these birds may lead to imbalance of the amounts of calcium and phosphorus levels, as already described in cattle egrets (PHALEN et al., 2005). In the case of the crab-eating hawk in this study, it is believed that the disease was actually derived from the reduction of crab ingestion, since there is a reduction of crustacean in the mangroves of the region of João Pessoa, due to pollution and human predation (IVO et al., 2000; NASCIMENTO, 2016; NORDI, 1994).

Figure 4 – Photomicrographs of the tibiotarsus of the caboclo hawk (*Heterospizias meridionalis*). A) Presence of irregular and slightly mineralized bone callus (thin arrow). B) Spongy bone: atrophied, slightly mineralized trabeculae (thick arrow). A) Bar = 200µm. B) Bar = 300µm. Masson's trichrome staining.



The use of foods that are not common in the diet of the animal is one of the factors that can cause the imbalance in the levels of calcium and phosphorus (TANGREDI, 1990), so the degradation of the habitat, in the case of the mangroves in the Paraíba coast, may have been a factor that influenced the decrease in the food supply (IVO et al., 2000; NASCIMENTO, 2016; NORDI, 1994) and use of different items in the diet, resulting in the development of rickets in this chick. However, further studies are needed with the populations of crab-eating hawks and their food supply in the region to evaluate the possible risks of anthropic actions on the population of crab-eating hawks.

The histological findings of the caboclo hawk are consistent with the diagnosis of fibrous osteodystrophy. This disease is the result of continuous and excessive secretion of parathyroid hormone, which is characterized by an osteoclastic resorption and consequent fibrous substitution. In these cases, the birds become more susceptible to pathological fractures (PALMER, 1991), and this led to the decision of euthanasia of the animal. In general, this disease is a consequence of nutritional problems or insufficient

exposure to sunlight (GRAHAM, 2013), but in this case there was no improvement in mineral deposition even with the use of balanced foods (mice, rats and adult quails) and calcium supplementation, perhaps due to the advanced stage of the disease. This finding demonstrates the need for research in the wild, since in domestic species genetic causes, malabsorption syndromes and acquired causes have already been widely described, such as the use of drugs like fluorides or the intake of aluminum and lead (MECHICA, 1999).

Calcium deficiency results in increased activity of the long-term parathyroid gland. Hyperparathyroidism has been reported in hawks with severe fibrous osteodystrophy (LONG; CHOI; REHMEL, 1983). The parathyroid glands of the hawk had characteristic oxyphilic cells. These cells have been described in several cases of hyperparathyroidism in animals (ROTH; CAPEN, 1974), but the diagnosis of fibrous osteodystrophy can also be concluded without the presence of these cells. Therefore, factors such as the age of the bird, type of nutrient and duration of the deficiency are related to the proliferation of oxyphilic cells in avian hyperparathyroidism (TOYODA et al.,

2004), since these cells are not normally found in birds, as they are in cattle, horses and humans (BANKS, 1992).

These cases demonstrate the need for more in-depth research to assess the influence of the environment, genetics, drug intake, among other factors that can trigger metabolic diseases. Since metabolic bone diseases can occur in wild free-living birds of prey due to unbalanced feeding, it is important to investigate the causes that led to these diseases and the possible use of these cases as bio-indicators of environmental imbalance.

CONCLUSION

This report describes, for the first time, rickets in a crab-eating hawk, and fibrous osteodystrophy in a caboclo hawk, both free-living. Such macro and microscopic data are subsidy for the clinic and for conservation and nutritional studies, mainly for birds found in zoos, rehabilitation centers and nurseries, as well as to demonstrate the need for ecological studies to investigate such causes in natural environments and their relation to the environmental imbalance.

REFERENCES

- BANKS, J. W. **Histologia Veterinária Aplicada**. São Paulo: Manole, 1992. 629 p.
- COUSQUER, G. O.; DANKOSKI, E. J.; PATTERSON-KANE J. C. Metabolic bone disease in wild collared doves (*Streptopelia decaocto*). **Veterinary Record**, v. 160, n. 3, p. 78-84, 2007.
- FOWLER, M. E. Metabolic Bone Disease. In: FOWLER, M. E. (Ed.). **Zoo and Wild Animal Medicine**. 2. Ed. Philadelphia: Saunders, 1986. p. 69-90.
- IVO, C. T. G.; DIAS, A. F.; BOTELHO, E. R. DE O.; MOTA, R. I.; VASCONCELOS, J. A. DE; VASCONCELOS, E. M. S. Caracterização das populações de caranguejo-uçá, *Ucides cordatus* (Linnaeus, 1763), capturadas em estuários do Nordeste do Brasil. **Boletim Técnico Científico do CEPENE**, v. 8, n. 1, p. 9-43, 2000.
- LACERDA, L. D.; SANTOS, J. A.; MADRID, R. M. Copper emission factors from intensive shrimp aquaculture. **Marine Pollution Bulletin**, v. 52, p. 1784-1832, 2006.
- LONG, P.; CHOI, G.; REHMEL, R. Oxyphil cells in a red-tailed hawk (*Buteo jamaicensis*) with nutritional secondary hyperparathyroidism. **Avian Disease**, v. 27, p. 839-843, 1983.
- MECHICA, J. B. Raquitismo e osteomalacia. **Arquivo Brasileiro de Endocrinologia e Metabologia**, v. 43, p. 457-466, 1999.
- NASCIMENTO, D. M. **Ecologia e captura do caranguejo-uçá *Ucides cordatus* (Linnaeus, 1763) (Decapoda, Brachyura) no estuário do rio Mamanguape - PB e suas implicações para a conservação**. 2016. 172 f. Tese (Doutorado em Etnobiologia e Conservação da Natureza) - Universidade Federal Rural de Pernambuco, Recife, 2016.
- NORDI, N. A produção dos catadores de caranguejo-uçá (*Ucides cordatus*) na região de Várzea Nova, Paraíba, Brasil. **Revista Nordestina de Biologia**, v. 9, n. 1, p. 71-77, 1994.
- PALMER, N. Bones and joints. In: JUBB, K. V. F.; KENNEDY, P. C.; PALMER, N. (Ed.). **Pathology of Domestic Animals**. San Diego: Academic Press, 1991, p. 1-181.
- PHALEN, D. N. et al. Naturally occurring secondary nutritional hyperparathyroidism in cattle egrets (*Bubulcus ibis*) from central Texas. **Journal of Wildlife Disease**, v. 41, n. 2, p. 401-415, 2005.
- GRAHAM D. L. Malnutrition in captive birds of prey. In: PAGE L. A. (Eds). **Wildlife Disease**. New York: Plenum Presse, 1976. p. 89-94.
- RAMOS, A. H. et al. Biometria, histologia e morfometria do sistema digestório do cachorro-do-mato (*Cerdocyon thous*) de vida livre. **Biotemas**, v. 24, n. 4, p. 111-119, 2011.
- RICHARDSON, P. R. K.; PLUG, I. Bone crushing carnivores and their significance to osteodystrophy in griffon vulture chicks. **Journal of Zoology**, v. 210, n. 1, p. 23-43, 1986.
- ROTH, S. I.; CAPEN, C. C. Ultrastructural and functional correlations of the parathyroid gland. **International Review of Experimental Pathology**, v. 13, p. 161-221, 1974.
- SICK, H. **Ornitologia brasileira, uma introdução**. Brasília: Editora Universidade de Brasília, 1984.
- SILVA, E. L. P.; CONSERVA, M. S.; OLIVEIRA, P. Socioecologia do processo de trabalho das pescadoras artesanais do estuário do rio Paraíba, Nordeste, Brasil. **Ecologia**, v. 3, p. 47-61, 2011.
- STANFORD, M. Effects of UVB radiation on calcium metabolism in psittacine birds. **Veterinary Record**, v. 159, p. 236-241, 2006.
- STENKAT, J.; KRAUTWALD-JUNGHANN, M. E.; SCHMIDT, V. Causes of morbidity and mortality in free-living birds in an urban environment in Germany. **EcoHealth**, v. 10, n. 4, p. 352-365, 2013.
- TANGREDI, B. P.; KROOK, L. P. Nutritional secondary hyperparathyroidism in free-living fledgling American crows (*Corvus brachyrhynchos brachyrhynchos*). **Journal of Zoo Wildlife Medicine**, v. 30, p. 94-99, 1999.
- TOYODA, T. et al. Nutritional secondary hyperparathyroidism and osteodystrophía fibrosa in a Hodgson's hawk-eagle (*Spizaetus nipalensis*). **Avian Pathology**, v. 33, n. 1, p. 9-12, 2004.