









Original article

## Sonographic evaluation of the lumbosacral region for neuroaxial anaesthesia in domestic felines

Avaliação ultrassonográfica da região lombossacra para anestesia neuroaxial em felinos domésticos

Andressa de Fátima Kotleski Thomaz de Lima<sup>1\*</sup> , Mario Antonio Ferraro Rego<sup>1</sup> , Luciano Cacciari Baruffaldi Almeida da Silva<sup>2</sup> , Vanessa Nadine Gris<sup>1</sup> , Carla Aparecida Batista Lorigados<sup>1</sup> , Silvia Renata Gaido Cortopassi<sup>1</sup> 

<sup>1</sup> Department of surgery, School of Veterinary Medicine, University of São Paulo.

<sup>2</sup> Department of surgery, University Metropolitana of Santos.

### ARTICLE INFO

#### Article history

Received 15 January 2019

Accepted 27 June 2019

#### Keywords:

Epidural

Spinal anaesthesia

Cat

Ultrasound

#### Palavras-chave:

Peridural

Raquianestesia

Gato

Ultrassom

### ABSTRACT

The objective of this study was to describe the lumbosacral region of domestic felines using ultrasonography. The limits and dimensions of the epidural and subarachnoid spaces were identified and their correlation with sex and body score condition (BCS) were evaluated. Fourteen mongrel cat cadavers, nine males and five females, weighing between 2.0 and 4.5 kg and with BCS ranging from 2 to 5 (1-5) were used. The cadavers were put in sternal recumbency and ultrasonographic images of the lumbosacral region were obtained in the sagittal and transverse planes. There was no statistical difference in the measurements between males and females. The BCS was positively correlated with the distance between the skin and dorsal epidural space, the distance between the skin and dural sac, and the distance between the skin and the ventral floor. No correlations were identified between the BCS and the distance between epidural space and dural sac, BCS and the sagittal dural sac height, or BCS and transverse dural sac height. The study showed that animals with a higher body condition score present larger distances between structures, regardless of their sex. In addition, the sonographic study verified the close proximity of the epidural and subarachnoid spaces, highlighting the risk of inadvertent spinal puncture in felines.

### RESUMO

O presente estudo objetivou avaliar a região lombossacra de felinos domésticos por meio da ultrassonografia, identificando os limites e dimensionando os espaços peridural e subaracnoide, relacionando essas medidas com o sexo e o escore corporal dos animais. Foram utilizados 14 cadáveres de gatos, sem raça definida, nove machos e cinco fêmeas, pesando entre 2,0 e 4,5 kg e com escore corporal variando de 2 a 5 (1-5). Para a avaliação da região lombossacra, os animais foram posicionados em decúbito esternal e imagens ultrassonográficas desta região foram adquiridas nos planos sagital e transversal. Não houve diferença estatística entre machos e fêmeas com relação às medidas. Houve correlação positiva entre o escore corporal e a distância entre a pele e o espaço peridural dorsal; escore corporal e a distância entre a pele e o saco dural; e escore corporal e a distância entre a pele e o assoalho ventral. Não foram identificadas correlações entre o escore corporal e a distância entre o espaço peridural e saco dural; escore corporal e altura do saco dural sagital; e escore corporal e altura saco dural transversal. Conclui-se que animais com maior escore corporal apresentam distâncias maiores, e não há diferença nas mensurações com relação ao sexo. Além disso, o estudo ultrassonográfico constatou a proximidade do espaço peridural e raquidiano, implicando no risco de punção inadvertida em felinos.

### INTRODUCTION

Pain treatment in cats is often neglected due to the fear of adverse effects of traditional analgesics and a lack of drugs authorised for use in cats. The glucuronidation

\* Corresponding author: [andressa\\_kotleski@hotmail.com](mailto:andressa_kotleski@hotmail.com)

deficiency caused by some drugs and the increased risk of toxicity also contribute to the underutilisation of analgesics in cats compared to dogs (ROBERTSON; TAYLOR, 2004).

Effective pain control can be achieved with the use of locoregional anaesthesia, which presents well known advantages, such as the control and reduction of the endocrine and metabolic responses to surgical stress, a reduction in the need for opioid analgesics and ventilatory support, and an improved quality of recovery (SESSLER et al., 2008; ETIENNE; PEETERS; BUSONI, 2010; LOBO, 2012). The blockade of nociceptive impulse transmission also reduces the requirement of general anaesthetics and the time for extubation, thus increasing patient comfort and the safety of the anaesthetic procedure (ROBERTSON; TAYLOR, 2004; HELLYER et al., 2007).

Epidural and spinal anaesthesia are commonly used to control nociception and postoperative pain (OTERO et al., 2016). In veterinary medicine, spinal anaesthesia is still rarely performed, especially in cats. Their spinal cord is located more caudally in the sacral area than in large-breed dogs, and inadvertent puncture of the dural sac is likely (VALVERDE, 2008; CASONI; ROHRBACH; SPADAVECCHIA, 2014). However, there is still a substantial lack of information on the use of different drugs and doses for cats (NOVELLO; CORLETTI, 2006).

Spinal anaesthesia presents some advantages over epidurals. For example, the correct positioning of the needle in spinal anaesthesia can be confirmed by the flow of cerebrospinal fluid through its hub, the latency of the drug is shorter, and the level of lateralisation can be

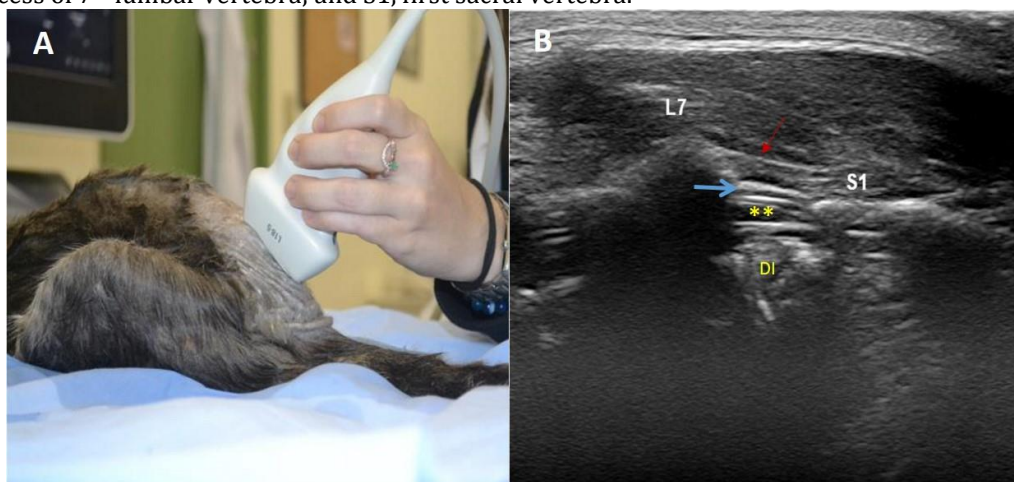
controlled according to the baricity of the solution. However, the risk of cardiac arrest, neurological injury, and radiculopathy is higher than for epidural anaesthesia (VALVERDE, 2008). It is important to emphasise that the dose used in the subarachnoid space is 40 to 60% lower than that used for an epidural (NOVELLO; CORLETTI, 2006; VALVERDE, 2008). In addition, the use of preservative-containing drugs is associated with spinal cord toxicity (VALVERDE, 2008).

In cats, the epidural space is traditionally accessed in the region that presents the largest dural sac, between the 7<sup>th</sup> lumbar and 1<sup>st</sup> sacral vertebrae. During puncture, the needle traverses the skin and the yellow ligament, and a loss of resistance is perceived. There is risk of inadvertent subarachnoid injection, leading to severe hypotension, cardiovascular collapse, and death (OTERO et al., 2016). The purpose of our study was to evaluate the lumbosacral region using ultrasonography (US) and to describe the epidural and subarachnoid spaces to provide a better understanding of neuraxial anaesthesia in cats.

## MATERIAL AND METHODS

This study was approved by the Ethics Committee on the Use of Animals of the Faculty of Veterinary Medicine and Animal Science of the University of São Paulo (FMVZ-USP) under the protocol number 4984040716. Fourteen mongrel cat cadavers, nine males and five females, weighing between 2.0 and 4.5 kg and with a BCS ranging from 2 to 5 (1–5) were used. The cats had died naturally from different causes and presented no deformity in the lumbar and sacral spine.

Figure 1 – Positioning of the transducer in space L7–S1 (A) to obtain a sonographic image of structures in the median sagittal plane (B): supraspinous ligament (red arrow); epidural space (blue arrow); dural sac (\*\*); ID, intervertebral disc; L7, spinous process of 7<sup>th</sup> lumbar vertebra; and S1, first sacral vertebra.

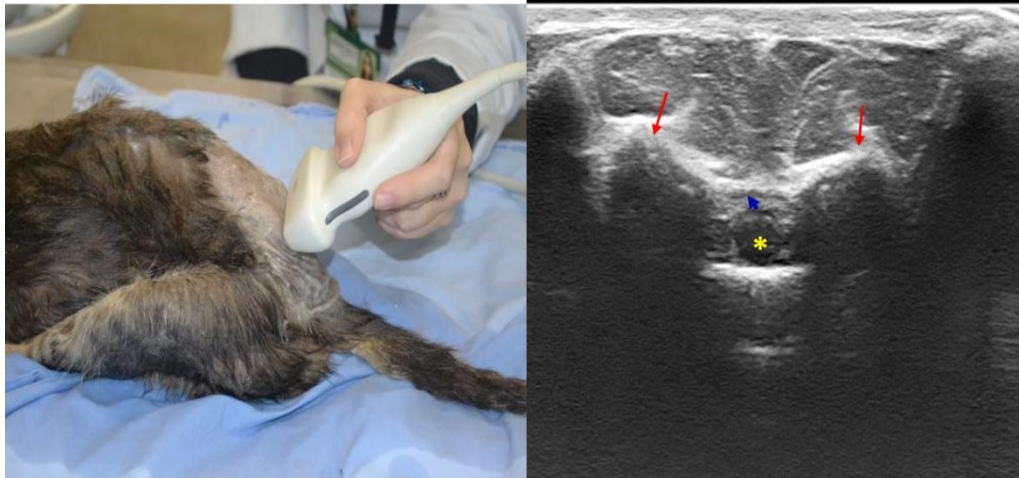


The cadavers were thawed for 24 hours before the study and the lumbosacral region was shaved. With the cats in sternal recumbency and the pelvic limbs cranially drawn, the intervertebral space was located by palpation of the ilium wings and the spinous process of L7. A

multifrequential 5 to 18 MHz 45 mm linear transducer (Affiniti 70, Philips, Amsterdam, NL) was placed longitudinally to the lumbosacral axis, dorsally to the spinous processes of L7–S1 (Figure 1), and transverse to

the median sagittal plane (Figure 2) in order to obtain B-mode images.

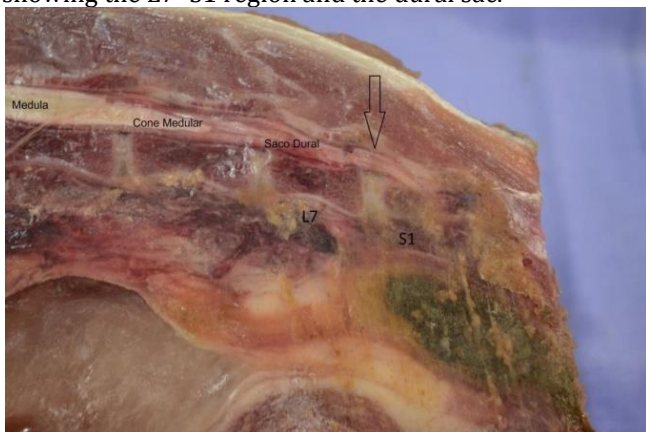Figure 2 – Positioning of the transducer in space L7–S1 (A) to obtain a sonographic image of structures in the transverse plane (B): dural sac; iliac wings (red arrows), and epidural space (blue arrow).



In the sagittal plane, the distance between the surface of the skin and the dural sac, the dorsal epidural space and the dural sac, and the ventral floor and the dorsal epidural space were measured. The height of the dural sac was also evaluated. All assessments were performed by the same specialist.

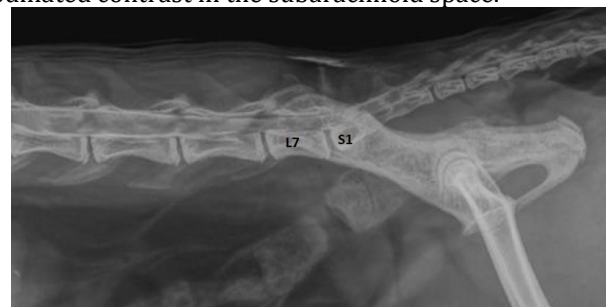To confirm the values obtained by ultrasonography, a sagittal cut of the lumbosacral region of a cat cadaver was performed and measurements were made directly on the anatomical piece (Figure 3). A US-guided puncture was also performed in the L7–S1 space for the injection of iodinated contrast into the dural sac followed by radiography of the area for confirmation (Figure 4).

Figure 3 – Sagittal section of the anatomical part, showing the L7–S1 region and the dural sac.



All data were submitted to the Shapiro-Wilk test and presented a normal distribution. A student's t-test was used for the comparison between males and females for each measurement and the comparison between the dural sac heights according to the sagittal and transverse methods.

Figure 4 – Laterolateral radiograph of the lumbosacral spine after puncture in the space L7–S1, showing iodinated contrast in the subarachnoid space.



A spearman's correlation test verified the association between BCS, sex, and the observed measures. The level of significance was set at 5% ( $p < 0.05$ ). The statistical tests were performed with RStudio, Version 0.99.903© 2009–2016 (RStudio, Inc., Boston, MA, USA) and Prism Version 7.0 for Windows (GraphPad Software, Inc., San Diego, CA, USA).

## RESULTS

There was no difference in the number of males and females ( $F = 5/14$ ,  $M = 9/14$ ,  $X\text{-squared} = 0.64286$ ,  $df = 1$ ,  $p\text{-value} = 0.4227$ ). Likewise, there was no difference in the weight of the sexes ( $F = 2.98 \pm 1.11$  kg,  $M = 3.81 \pm 1.6$ ,  $t = -1.1401$ ,  $df = 11.125$ ,  $p\text{-value} = 0.2782$ ) or the BCS of the sexes [ $F = 3$  (2-3),  $M = 3$  (2-3);  $W = 22$ ,  $p\text{-value} = 1$ ] (Table 1).

There was a positive correlation between the distance from the skin to the ventral floor and the BCS ( $\rho = 0.6882376$ ,  $p = 0.009303$ ) (Figure 5), the BCS and the distance between the skin and the dorsal epidural space ( $\rho = 0.7248384$ ,  $p = 0.003359$ ) (Figure 6), and the BCS and the distance between the skin and the dural sac ( $\rho = 0.5954557$ ,  $p = 0.02466$ ) (Figure 7).

Table 1 – Mean ± standard deviation of the lumbosacral region measurements (cm) in male and female cats.

Parameter	Male	Female	p-value
Skin-dorsal epidural	1.198 ± 0.240	1.002 ± 0.120	0.069
Skin-dural sac	1.329 ± 0.240	1.110 ± 0.150	0.064
Skin-ventral floor	1.481 ± 0.260	1.220 ± 0.190	0.075
Epidural-dural sac	0.143 ± 0.030	0.128 ± 0.040	0.447
Height of dural sac- Sagittal	0.112 ± 0.030	0.117 ± 0.040	0.843
Height of dural sac- Transversal	0.120 ± 0.030	0.113 ± 0.040	0.812

Figure 5 – Correlation of the distance from the skin to the ventral floor with the BCS.

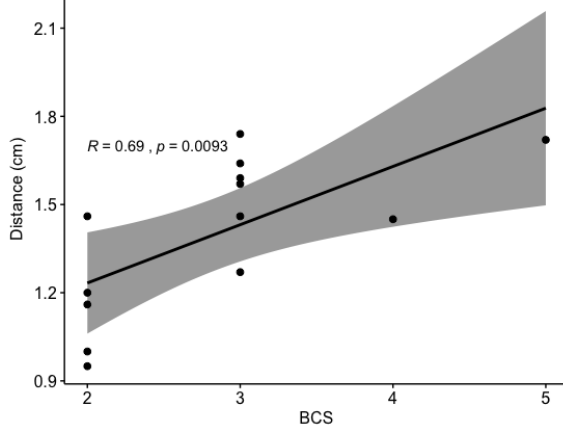


Figure 6 – Correlation of the distance from the skin to the dorsal epidural space with the BCS.

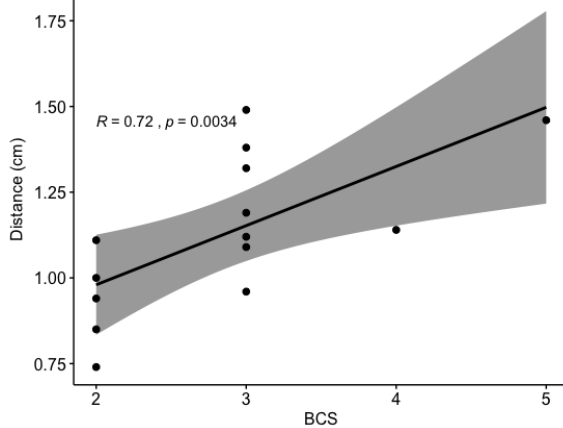


Figure 7 – Correlation of the distance from the skin to the dural sac with the BCS.

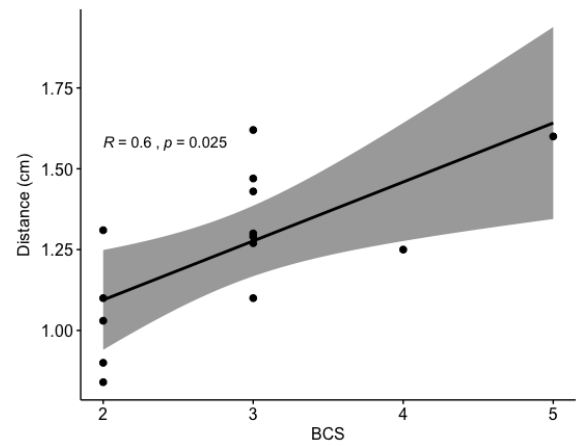
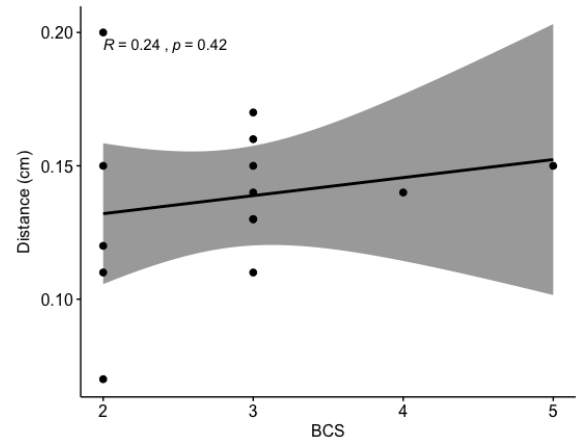
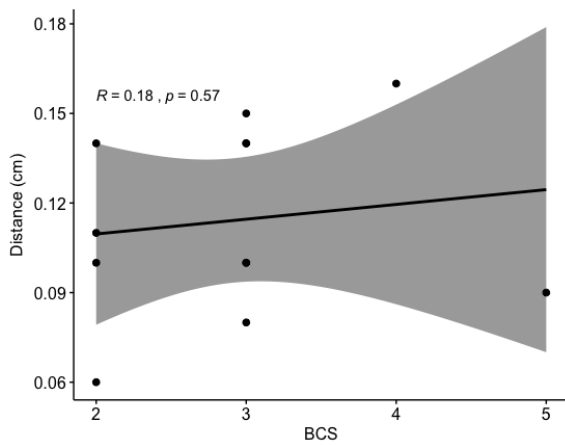


Figure 8 – Correlation of the distance from the epidural space to the dural sac with the BCS.



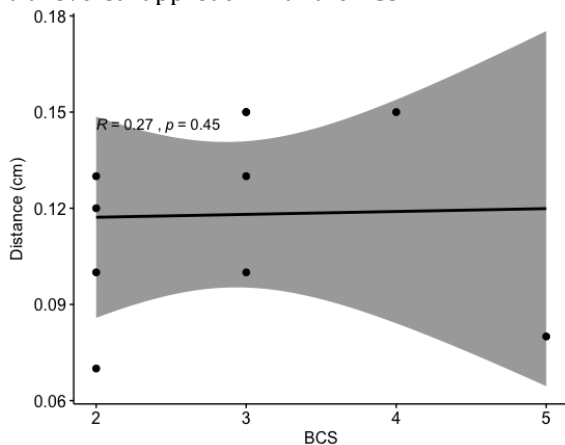
No correlation was identified between the BCS and the distance between the epidural space and dural sac ( $\rho = 0.2354036$ ,  $p = 0.4178$ ) (Figure 8), between the BCS and height of the sagittal dural sac ( $\rho = 0.1815796$ ,  $p = 0.5722$ ) (Figure 9), or between the BCS and height of the transverse dural sac ( $\rho = 0.270023$ ,  $p = 0.4505$ ) (Figure 10).

Figure 9 – Correlation of the dural sac height in the sagittal approach with the BCS.



There was no difference in the measurements obtained for the height of the dural sac using the sagittal and transverse methods (sagittal =  $0.11 \pm 0.03$ , transversal =  $0.12 \pm 0.03$ ;  $t = -1,291$ ,  $df = 9$ ,  $p = 0.2289$ ).

Figure 10 – Correlation of the height of the dural sac in the transversal approach with the BCS.



Furthermore, no difference was found between males and females when comparing the distances from the skin to the dorsal epidural ( $t = -1.9964$ ,  $df = 11.991$ ,  $p = 0.06911$ ), the skin to the dural sac ( $t = -2.0419$ ,  $df = 11.635$ ,  $p = 0.0645$ ), the skin to the ventral floor ( $t = -2.0435$ ,  $df = 7.9561$ ,  $p = 0.07545$ ), and the epidural to the dural sac ( $t = -0.80801$ ,  $df = 6.5841$ ,  $p = 0.4473$ ), or when comparing the height of the sagittal dural sac ( $t = 0.21104$ ,  $df = 4.1639$ ,  $p = 0.8428$ ) and the height of the transverse dural sac ( $t = -0.26165$ ,  $df = 2.8091$ ,  $p = 0.8116$ ).

## DISCUSSION

The anatomy of the lumbosacral region in felines is well described in the literature (CAMPOY; READ, 2013). However, ultrasonographic guidance for neuroaxial blocks is a recent development in veterinary medicine (OTERO et al., 2016; CREDIE; LUNA, 2018).

According to the data obtained in our study, it is possible to affirm that the peridural-subarachnoid spaces and adjacent structures can be well described with the use of

ultrasonography. Credie and Luna (2018) also described two-dimensional ultrasonography capable of accurately identifying the anatomy of the lumbosacral epidural space.

During the ultrasound-guided puncture, the transducer had to be moved to the parasagittal region to visualise the needle for real-time puncture. The distances from the skin to the epidural described by Otero et al. (2016) and Credie and Luna (2018) were taken in the parasagittal plane, and could have been different to those obtained in our study. However, the results were very similar.

Credie and Luna (2018) excluded obese and very thin animals in order to standardise the technique in animals with the same body score. Our study intended to report the effect of the corporal score on the proposed measures. Thus, we verified a positive correlation between the increase in body condition score and the increase in the distance from the skin to the neuroaxial structures due to the accumulation of fat in the subcutaneous tissue, an effect that has also been documented in humans (D'ALONZO et al., 2008).

The proximity of the epidural space to the dural sac ( $<0.15$  cm) supports the authors' concern about the possibility of inadvertent puncture of the subarachnoid space. The use of ultrasound to locate these spaces is advantageous compared to conventional methods since it allows visualisation of the site of administration and introduction of the needle at the exact location, resulting in a reduction in tissue damage (CAMPOY et al., 2010). Valverde (2008) reported the risk of erroneous puncture in the dural sac while performing epidural anaesthesia in felines. Otero and Campoy (2013) observed the spinal cord of felines, evidencing their extension to lumbosacral space. Thus, epidural puncture in the sacrococcygeal space has been proposed in felines instead of the lumbosacral approach, in order to avoid inadvertent puncture of the subarachnoid space or spinal cord (O'HEARN; WRIGHT, 2011; OTERO et al., 2015; CREDIE; LUNA, 2018).

Furthermore, in accordance with Gnaho et al. (2012), we describe that the use of ultrasound for identifying the location of the subarachnoid space provides a reliable estimate of the depth of the space and delineation of the structures of the neuroaxis, thus reducing the risks of failure of the puncture. In addition, professional experience facilitates the interpretation of the images obtained in the ultrasound (ETIENNE; PEETERS; BUSONI, 2010). Nowadays, the training of professionals who are inexperienced with ultrasonography is performed using cadavers or training models, which enables an increase in knowledge and improvements in the learning curve (ETIENNE; DELGUSTE; BUSONI, 2016; SILVA et al., 2017).

Since the measurements were performed in a cadaver, post-mortem alterations might have impaired the evaluation of the structures. However, the measurements were similar to those observed in other

in vivo studies, indicating that eventual occurrences did not compromise the results obtained in this study.

### CONCLUSION

The use of ultrasound for the identification of structures in the lumbosacral region allowed the accurate measurement of the peridural and subarachnoid spaces. There was no difference in the measurements between males and females. Animals presenting a higher body score condition had larger distances from the skin to the epidural space, the dural sac, and the ventral floor.

### ACKNOWLEDGEMENTS

We would like to thank the Coordination for the Improvement of Higher Education Personnel, Brazil (CAPES), financing code 001, for their support.

### REFERENCES

- CAMPOY, L. et al. Ultrasound-guided approach for axillary brachial plexus, femoral nerve, and sciatic nerve blocks in dogs. **Veterinary Anaesthesia and Analgesia**, Philadelphia, v. 37, n. 2, p. 144–153, 2010.
- OTERO, P. E.; CAMPOY, L. Epidural and Spinal Anesthesia. In: CAMPOY, L.; READ, M. **Small animal regional anesthesia and analgesia**. New Jersey: Wiley-Blackwell, 2011. 1<sup>st</sup>ed, cap.1, p. 227–259.
- CASONI, D.; ROHRBACH, H.; SPADAVECCHIA, C. Total spinal anaesthesia following spinal lumbosacral injection of bupivacaine 0.5 per cent in a cat. **Veterinary Record Case Reports**, London, v. 2, p. 1–4, 2014.
- CREIDIE, L.; LUNA, S. The use of ultrasound to evaluate sacrococcygeal epidural injections in cats. **Canadian Veterinary Journal**, Ottawa, v. 59, p. 143–146, 2018.
- D'ALONZO, R. C. Ethnicity and the distance to the epidural space in parturients. **Regional Anesthesia and Pain Medicine**, Alphen aan den Rijn, v. 33, n. 1, p. 24–29, 2008.
- ETIENNE, A. L.; DELGUSTE, C.; BUSONI, V. Comparison of ultrasound-guided vs. standard landmark techniques for training novice operators in placing needles into the lumbar subarachnoid space of canine cadavers. **Veterinary Radiology and Ultrasound**, New Jersey, v. 57, n. 4, p. 441–447, 2016.
- ETIENNE, A. L.; PEETERS, D.; BUSONI, V. Ultrasonographic percutaneous anatomy of the caudal lumbar region and ultrasound-guided lumbar puncture in the dog. **Veterinary Radiology and Ultrasound**, New Jersey, v. 51, n. 5, p. 527–532, 2010.
- GNAHO, A. et al. Avaliação da Profundidade do Espaço Subaracnóideo com o Uso do Ultrassom. **Revista Brasileira de Anestesiologia**, Botafogo, v. 64, n. 4, p. 520–530, 2012.
- HELLYER, P. et al. AAHA/AAFP pain management guidelines for dogs and cats. **Journal of Feline Medicine and Surgery**, New York City, v. 9, n. 6, p. 466–480, 2007.
- NOVELLO, L.; CORLETTI, F. Combined spinal-epidural anesthesia in a dog. **Veterinary Surgery**, New Jersey, v. 35, p. 191–197, 2006.
- O'HEARN, A. K.; WRIGHT, B. D. Coccygeal epidural with local anesthetic for catheterization and pain management in the treatment of feline urethral obstruction. **Journal of Veterinary Emergency and Critical Care**, New Jersey, v. 21, n. 1, p. 50–52, 2011.
- OTERO, P. E.; CAMPOY, L. Epidural and spinal anesthesia. In: CAMPOY, L.; READ, M. (Eds.). **Small animal regional anesthesia and analgesia**. Nova Jersey: Wiley, 2013. p. 227–259.
- OTERO, P. E. et al. Sonographic evaluation of epidural and intrathecal injections in cats. **Veterinary Anaesthesia and Analgesia**, Philadelphia, v. 43, n. 6, p. 652–661, 2016.
- OTERO, P. E. et al. The use of a nerve stimulation test to confirm sacrococcygeal epidural needle placement in cats. **Veterinary Anaesthesia and Analgesia**, Philadelphia, v. 42, n. 1, p. 115–118, 2015.
- ROBERTSON, S. A.; TAYLOR, P. M. Pain management in cats—past, present and future. Part 2. Treatment of pain—Clinical pharmacology. **Journal of Feline Medicine and Surgery**, New York City, v. 6, n. 5, p. 321–333, 2004.
- LOBO, C. O ensino da anestesia regional. **Clube de Anestesia Regional**, Porto, n. 72, p. 6-11, 2012.
- SESSLER, D. I. et al. Can regional analgesia reduce the risk of recurrence after breast cancer? **Contemporary Clinical Trials**, New York, v. 29, n. 4, p. 517–526, 2008.
- SILVA, L. C. B. A. et al. Preliminary study of a teaching model for ultrasound-guided peripheral nerve blockade and effects on the learning curve in veterinary anesthesia residents. **Veterinary Anaesthesia and Analgesia**, Philadelphia, v. 44, p. 684–687, 2017.
- VALVERDE, A. Epidural analgesia and anesthesia in dogs and cats. **Veterinary Clinics of North America: Small Animal Practice**, New York, v. 38, n. 6, p. 1205–1230, 2008.